



Seminoma Arising from Cryptorchidism Presenting as a Giant Extraperitoneal Abdominal Mass: A Case Report

Cheng-Kai Xia, Xiao-Yang Wu*

Department of Gastrointestinal Surgery, Kunshan First People's Hospital Affiliated to Jiangsu University, Kunshan, China

Email address:

wxy640707@126.com (Xiao-Yang Wu)

*Corresponding author

To cite this article:

Cheng-Kai Xia, Xiao-Yang Wu. Seminoma Arising from Cryptorchidism Presenting as a Giant Extraperitoneal Abdominal Mass: A Case Report. *Journal of Surgery*. Vol. 11, No. 2, 2023, pp. 60-63. doi: 10.11648/j.js.20231102.15

Received: April 2, 2023; Accepted: April 24, 2023; Published: May 10, 2023

Abstract: *Background:* Preperitoneum cryptorchidism is infrequent in adults, and has an extremely high risk of malignant transformation. The diagnosis requires a comprehensive consideration of symptoms, findings upon physical examination, and laboratory and imaging tests. *Case information:* We report a case of a 38-year-old man with a massive abdominal mass corresponding to a seminoma arising from cryptorchidism. Contrast-enhanced computer tomography demonstrated a large mass with clear realm and uneven density. The testicular artery was found to originate from the left iliac fossa, and could be traced back to the abdominal aorta. The left spermatic cord was not present within the inguinal canal. *Result:* Laparotomy was performed with midline incision, and we did not enter the abdominal cavity, wherein a large solid mass was identified in the preperitoneum, with the vascular pedicle originating in the left iliac fossa. The mass was resected en bloc. The pathological evaluation of the resected specimen was compatible with seminoma. The patient was referred to the department of oncology after discharge. The patient completed four cycles of etoposide/cisplatin adjuvant chemotherapy. The five-year follow-up showed no evidence of local or distant disease recurrence. *Conclusions:* Malignant transformation of cryptorchidism can present as an abdominal mass, and clinicians must be aware of this possibility, in order to provide opportune diagnosis.

Keywords: Cryptorchidism, Seminoma, Abdominal Mass, Case Report

1. Introduction

Germ cell tumors are the most frequent malignancies among young men, including both seminoma and non-seminomatous tumors [1]. Cryptorchidism has been identified as a risk factor for the development of seminoma, and is the most common congenital anomaly of the genitourinary tract in males. Furthermore, the most common sites of undescended testis are high scrotal localization, inside the inguinal canal, or the abdominal cavity [2, 3]. Intraabdominal cryptorchidism has a higher risk of malignant transformation than inguinal and high scrotal cryptorchidism [4-5]. In this report, we describe the case of a patient with seminoma arising in an intraabdominal cryptorchidism, which presented as a giant abdominal mass.

2. Case Presentation

A 38-year-old male patient was referred to our hospital with

a history of slight abdominal bloating which had begun approximately one month before consultation. He had no other complaints, and there was no other significant medical or surgical history. The male was successful in conceiving a child 13 years ago. On physical examination, no superficial enlarged lymph nodes were found; however, an abdominopelvic mass with high mobility was palpable in the lower abdomen. The left testicle was not detected in the scrotum. The right testis is located in the scrotum for normal size. Laboratory assessment revealed levels of lactate dehydrogenase (LDH), β -human chorionic gonadotropin (β -HCG), and α -fetoprotein were detected but not elevated. Abdominopelvic computed tomography (CT) demonstrated a 9.5 x 9.5 x 10.5 cm abdominal mass with clear limits and uneven density (Figures 1A and 1B). No obvious lymph node swelling was recognized in the abdominal aortic and inguinal area. The testicular artery was identified and found to originate from the left iliac fossa, which could be traced back to the abdominal aorta (Figure 1C). The left spermatic cord

was not present within the inguinal canal (Figure 1D).

Next, laparotomy was performed with midline incision, and we did not enter the abdominal cavity, wherein a large solid mass was identified in the preperitoneum, with the vascular pedicle originating in the left iliac fossa. The mass was resected *en bloc*. No lymph nodes were detected. The resected specimen had a length of 12 cm at its longest axis, with a smooth surface. A cut section of the mass showed a greyish white coloration, with a few foci of hemorrhage and necrosis (Figure 1E). Histopathological examination revealed that seminomas were composed of a sheet-like organization of cells with a fibrous stromal network (Figure 1F). The fibrous septa contained focal lymphocyte inclusions, and granulomas

were seen. Immunohistochemical staining was positive for placental alkaline phosphatase (PLAP), prominin-1 (PROM1) and POU class 2 associating factor 1 (POU2AF1). The final histopathological impression was that of a testicular seminoma (pT2N0M0S0), stage Ib.

Post-operative recovery was uneventful, and the patient was discharged on the sixth day after surgery. The patient was referred to the department of oncology after discharge. The patient completed four cycles of adjuvant chemotherapy with etoposide and cisplatin. The patient has been on follow-up for five years, with no evidence of recurrence, and tumor markers remaining within normal limits.

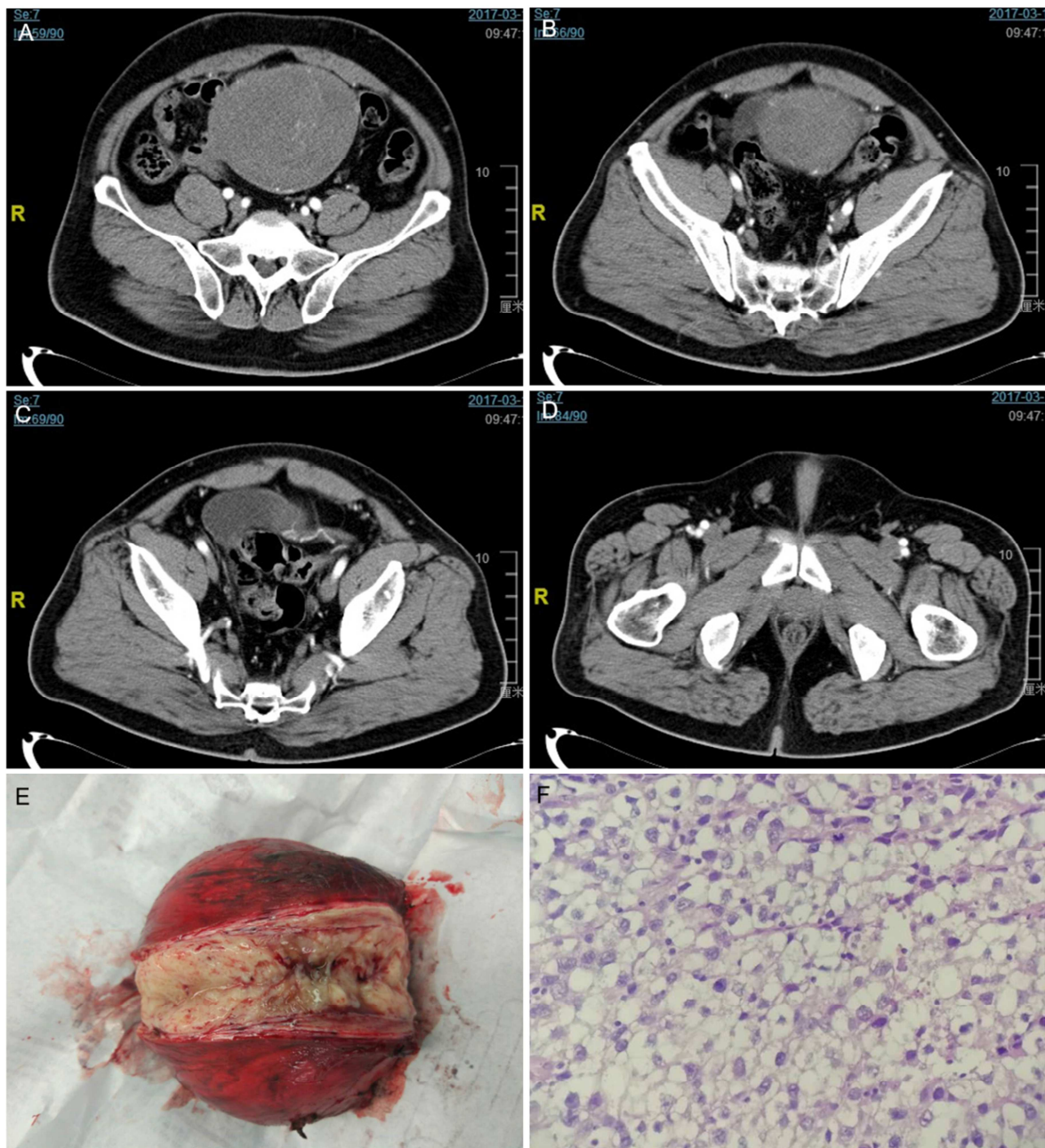


Figure 1. (A and B) A massive pelviabdominal mass with heterogeneous enhancement. (C) The testicular artery was identified originating from the left iliac fossa. (D) The left spermatic cord was not present within the inguinal canal. (E) Specimen's image after surgical resection. (F) Hematoxylin and eosinstained high-power microscopic view suggestive of seminoma.

3. Discussion

During fetal development, the testes typically descend into the scrotum within the third trimester. Cryptorchidism develops when this process is disrupted. It is an uncommon congenital anomaly, occurring in 1% of full-term males. Cryptorchidism should be treated in the first year. Early orchiopexy will preserve germinal epithelium, minimize infertility, and put the testis in a position that allows for easier self-examination and detection of testicular cancer [6-7]. Intraabdominal cryptorchidism has the highest risk of malignant transformation [4], with the most common malignancy being seminoma. Malignant transformation shows the peak incidence in the third and fourth decades of life. The intra-abdominal location is particularly rare with less than 10 cases of abdominal testicular tumors being reported [8-10]. While confined in the abdomen, testicular tumors can reach considerable sizes before being diagnosed. Symptoms consist mainly of abdominal pain, abdominal mass, difficulty in micturition and constipation. This case report presents an adult patient with cryptorchidism and an intraabdominal seminoma.

Seminoma arising from cryptorchidism is usually asymptomatic [11]. The radiologic diagnosis is often challenging since the patient's history of cryptorchidism is not provided, and individuals who had cryptorchidism surgery as a kid are unaware that orchiectomy may not have been done [12]. The diagnosis requires a comprehensive consideration of symptoms, findings upon physical examination, and laboratory and imaging tests. Ultrasound, CT and magnetic resonance imaging (MRI) can all detect abdominal, pelvic and retroperitoneal masses. Various tumor markers are available, including α -fetoprotein, β -HCG, and LDH; these are helpful for both diagnosis and formulation of management plans [13-15]. In this case, the main differential diagnosis was gastrointestinal stromal tumour. In addition, lymphoma, retroperitoneal sarcoma and desmoid tumor should also be considered. In conclusion, malignant transformations of cryptorchidism can present as an abdominal mass and clinicians must be aware of this possibility, in order to provide opportune diagnosis.

4. Conclusion

Seminoma arising from cryptorchidism is usually asymptomatic and identified incidentally by imaging tests. The diagnosis requires a comprehensive consideration of symptoms, findings upon physical examination, and laboratory and imaging tests. Malignant transformations of cryptorchidism can present as an abdominal mass and clinicians must be aware of this possibility, in order to provide opportune diagnosis.

Declarations

Ethics Approval and Consent to Participate

The present study was undertaken under the guidelines of the ethics committee of Jiangsu University. The authors have

no ethical conflicts to disclose.

Consent for Publication

Written informed consent of publication was obtained from the patient in the study.

Competing Interests

The authors declare that they have no competing interests.

Funding

This research did not receive any specific grant from funding agencies in the public, commercial, or not-for-profit sectors.

Acknowledgements

We thank colleagues at the department of radiology and pathology in our hospital for providing data.

References

- [1] Dieckmann KP, Richter-Simonsen H, Kulejewski M, *et al*: Testicular Germ-Cell Tumours: A Descriptive Analysis of Clinical Characteristics at First Presentation. *Urol Int* 100 (4): 409-419, 2018.
- [2] Wood HM and Elder JS: Cryptorchidism and testicular cancer: separating fact from fiction. *J Urol* 181 (2): 452-461, 2009.
- [3] Faruk M, Palinrungi MA, Kholis K, *et al*: A giant intra-abdominal right testicular seminoma in a bilateral undescended testicle: a case report. *Pan Afr Med J* 44: 3, 2023.
- [4] Nickalls OJ, Tan CL and Thian Y: A Tortured Ruptured Intra-abdominal Testicular Seminoma Presenting As An Acute Abdomen. *J Radiol Case Rep* 9 (12): 21-28, 2015.
- [5] Sushma Agrawal, Ranjeet Bajpai, R. K. Agrawal, *et al*: Bilateral synchronous seminoma with bilateral cryptorchidism of the testis. *Indian J Urol* 26 (4): 587-589, 2010.
- [6] Nkembe M. N., Mvalo C. M., Tianyi F. L., Demba C. Ambiguous presentation of an intra-abdominal testicular seminoma in a 40-year-old man: a case report. *J Med Case Rep* 13 (1): 1-4, 2019.
- [7] Parajuli P., Man Pradhan M., Chapagain S., Luitel B. R., Chalise P. R., Sharma U. K. Intra-abdominal mass with empty scrotum in adult male. *Urol Case Rep* 34, 2021.
- [8] Wong DG, Singla N, Bagrodia A. Massive Intra-abdominal Germ Cell Tumors: A Case Series and Review of Literature. *Rev Urol* 21 (2-3): 136-140, 2019.
- [9] Zhou JL, Liu DQ, Lei JX, *et al*: Abdominal cocoon syndrome with unilateral cryptorchidism and seminoma: A case report. *Asian J Surg*. 46 (2): 878-879, 2023.
- [10] Ben Hadj Alouane H, Mrad Dali K, Madani MA, *et al*: Unusual presentation of an intra-abdominal testicular seminoma in an adult. *Urol Case Rep* 43: 102119, 2022.

- [11] Sabbah BN, Alathel A, Alghafees MA, et al. Classical Seminoma With Secondary Undescended Testis in an Elderly Patient: An Incidental Finding With a Penile Fracture. *Cureus* 14 (11): e31924, 2022.
- [12] Liu R, Li J, Jiang Y, et al. Apparent diffusion coefficient values of cryptorchid testes and malignant transformation of cryptorchidism (MTC) (seminoma) in postpubertal patients. *Br J Radiol* 94 (1119): 20200624, 2021.
- [13] Zhu JL, Roberts MJ, Navaratnam A, *et al*: Bloating due to massive seminoma in an undescended testis. *ANZ J Surg* 89 (4): E160-E161, 2019.
- [14] Pedrazzoli P, Rosti G, Soresini E, Ciani S, Secondino S. Serum tumour markers in germ cell tumours: From diagnosis to cure. *Crit Rev Oncol Hematol* 159: 103224, 2021.
- [15] Miyai K, Yonekura Y, Ito K, Matsukuma S, Tsuda H. Gene expression microarray analysis of adult testicular germ cell tumor: a comparison between pure-type seminomas and seminoma components in mixed tumors. *Virchows Arch* 479 (6): 1177-1186, 2021.