



# A Case Study on Treatment of Ankylosing Spondylitis with Kyphosis Deformity by Two-Level Pedicle Subtraction Osteotomy

Yongchun Xiao, Gengxiong Lin, Guowei Zhang, Hua Yang, Zhisheng Ji\*, Hongsheng Lin\*

Department of Orthopedics, the First Affiliated Hospital of Jinan University, Guangzhou, China

## Email address:

tzhishengji@jnu.edu.cn (Zhisheng Ji), tlinhsh@jnu.edu.cn (Hongsheng Lin)

\*Corresponding author

## To cite this article:

Yongchun Xiao, Gengxiong Lin, Guowei Zhang, Hua Yang, Zhisheng Ji, Hongsheng Lin. A Case Study on Treatment of Ankylosing Spondylitis with Kyphosis Deformity by Two-Level Pedicle Subtraction Osteotomy. *Journal of Surgery*. Vol. 10, No. 3, 2022, pp. 131-135. doi: 10.11648/j.js.20221003.18

Received: June 1, 2022; Accepted: June 22, 2022; Published: June 30, 2022

---

**Abstract:** Ankylosing spondylitis is a disease characterized by inflammation of sacroiliac joint and spinal attachment point. It is strongly associated with HLA-B27. About 30% of patients will develop kyphosis. It not only causes severe kyphosis, restricted mobility, ugly appearance, and human head-up disorder, but also severe kyphosis causes sleep difficulties, compression of the chest and abdominal organs, and abdominal muscles. Contractures lead to disorders of the digestive function of the gastrointestinal tract and superior mesenteric artery syndrome, and even more serious psychological disorders, and even loss of confidence in life. The most effective treatment for ankylosing spondylitis kyphosis is spinal orthopedics. We report a 38-year-old male patient who was hospitalized with ankylosing spondylitis and kyphosis due to low back pain and activity limitation for 20 years, and progressive aggravation of his kyphosis for 10 years. The measurement of preoperative imaging parameters indicated: Pelvic Incidence (PI) = 61°, Pelvic Tilt (PT) = 64°, Sacral Slope (SS) = -3°, Lumbar Lordosis (LL) = -25°, Thoracolumbar Junction (TLJ) = 45°, Thoracic Kyphosis (TK) = 65°, Chin-Brow Vertical Angle (CBVB) = 60°. With adequate preoperative planning and discussion, we performed a two-level pedicle subtraction osteotomy, which requires comprehensive perioperative care and more refined intraoperative manipulation. The postoperative patient was 169cm, the height increased by 32cm, postoperative parameter measurement, PI = 60°, PT = 38°, SS = 22°, LL = 52°, TLJ = 15°, TK = 19°, CBVB = 13°. After the operation, the patient recovered well, the treatment effect was satisfactory, and the quality of life was significantly improved. Two-level pedicle subtraction osteotomy is a high-risk and high-demand operation that needs to be performed by an experienced spinal surgery team.

**Keywords:** Ankylosing Spondylitis, Spondyloarthritis, Kyphosis, Pedicle Subtraction Osteotomy, Case Report

---

## 1. Background

Ankylosing spondylitis is a chronic inflammatory disease, which mainly affects the sacroiliac joints, bony spine, adjacent soft tissues and peripheral joints. The prevalence is between 0.1% and 1.4% [1]. About 30% of the patients will have spine deformity, which not only causes severe kyphosis, restricted movement, ugly appearance and head-up disorder [2, 3], but also severe kyphosis causes sleep disorder and abdominal organ damage. Pressure leads to disorders of the digestive function of the gastrointestinal tract and superior mesenteric artery syndrome, which is more serious, causes

psychological disorders, and even loses confidence in life [4-7]. The current main treatment methods for ankylosing spondylitis include non-drug therapy, drug therapy and surgical treatment. Although conservative treatment has improved the patient's symptoms, the disease progresses to the later stage and causes kyphosis, which will affect the patient's ability of daily living, and even cause damage to the respiratory and digestive functions and reduce the patient's quality of life. Currently, the most effective treatment is spinal osteotomy orthopedics. Spinal osteotomy can not only

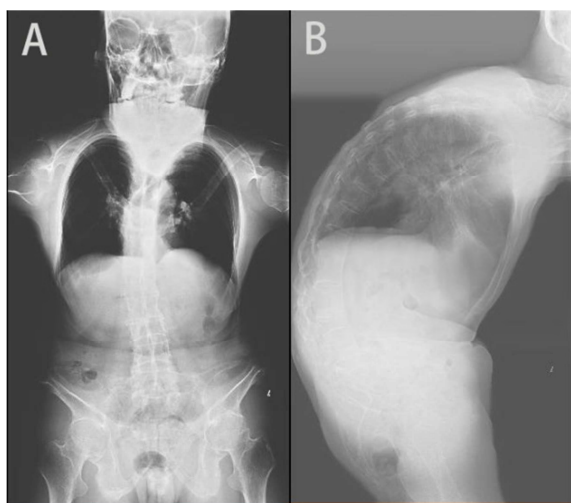
correct spinal deformities and restore sagittal plane balance, but also improve respiratory function, digestive function, heart function, sleep quality, and daily living ability [2, 4-7].

We report a case of 38-year-old male patient with "low back pain with limited mobility for 20 years and progressive aggravation of kyphosis for 10 years". Through the measurement of preoperative parameters, after adequate preoperative planning and discussion, we decided to adopt two-level pedicle subtraction osteotomy.

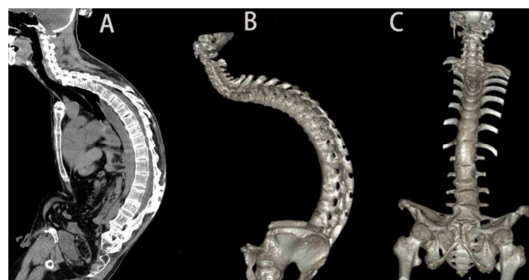
## 2. Case Presentation

A 38-year-old male patient came to our hospital for treatment with low back pain with limited movement for 20 years and progressive aggravation of kyphosis for 10 years. Twenty years ago, there was no obvious cause of left hip pain and kyphotic deformity gradually appeared. Five years ago, he could not lie supine. He visited many local hospitals. The imaging examination of the local hospital indicated "kyphosis with ankylosing spondylitis". There was no significant improvement in the patient's conservative treatment with drugs. In the past year, the symptoms had gradually worsened, and knee flexion was required for compensation when walking, which seriously affected life. Physical examination: The physiological curvature of the spine disappeared and kyphosis mainly in thoracolumbar segment. The cervical spine mobility was acceptable and the lumbar spine mobility disappeared. Each spinous process, interspinous ligament, transverse process, paraspinal process tenderness and percussion pain were obvious, and there was no radiating pain in the lower limbs. Both hips and knees moved normally. The sensation, muscle strength, and muscle tone of both lower limbs were normal.

Based on the patient's medical history, physical examination and imaging diagnosis, the preoperative diagnosis was ankylosing spondylitis kyphosis. The patient was 137cm before the operation, measured by the preoperative parameters, PI =61°, PT=64°, SS=-3°, LL=-25°, TLJ=45°, TK=65°, CBVB=60°.



**Figure 1.** Spinal X-ray before operation: 1, Scoliosis, Kyphosis; Ankylosing spondylitis.

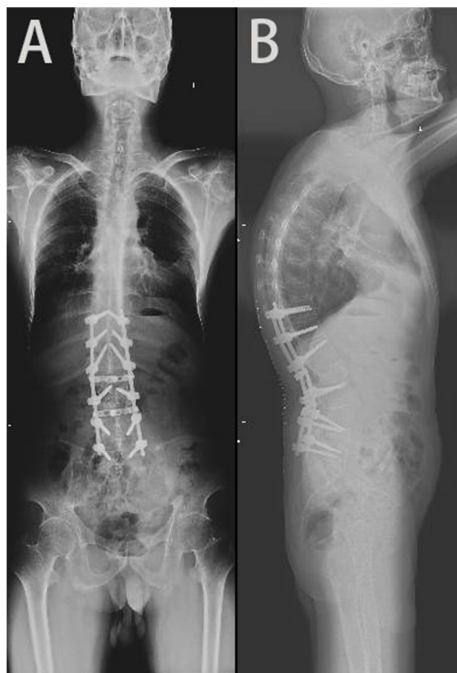

**Figure 2.** Spinal CT before operation: Scoliosis, Kyphosis; Ankylosing spondylitis.

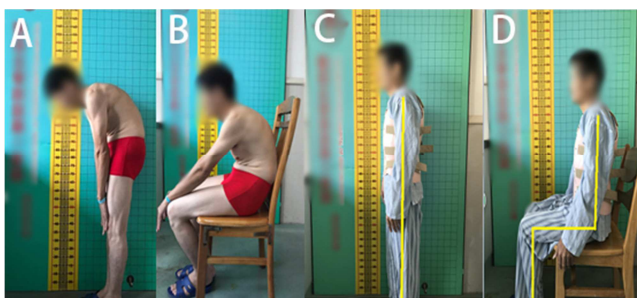
The general procedure of the operation was that the patient was placed in the prone position after the anesthesia was successful, and the C-arm was used to locate the T10-L5 surgical segment before the operation. Disinfected the surgical field, drape, and paste sterile film. A longitudinal incision was made on the lower back to expose the T10-L4 lamina and bilateral facet joints. Using the apex of the right-sided herringbone crest of L5 as the nail entry point, screwed in a pedicle screw of appropriate length into the bony pedicle wall. In the same way, screwed in pedicle screws of appropriate length on the left side of L5 and on both sides of T10, T11, T12, L2 and L4. During the operation, the position of the C-arm machine fluoroscopy pedicle screw was good. The upper and lower edges of the spinous process of the L3 vertebral body were approximately 7cm long for spinous process osteotomy, and the apex of the left pedicle of the L3 pedicle was used as the nail entry point. The probe was used to detect the correct direction of the nail path and the integrity of the four walls of the nail hole. The pedicle was treated with an osteotomy triangle from small to large to rupture the outer wall of the pedicle and keep the inner wall intact. At the same time, the transverse process was ruptured. The cancellous bone on the posterior edge of the L3 vertebral body was treated with an osteotomy triangular pyramid, so that the cancellous bone in the center of the vertebral body was close to the upper and lower endplates, and the center was empty. The right pedicle was treated in the same way, and the posterior lamina was removed to expose the L3 dura mater. Stripped the lateral muscles of the left vertebral body, used a bone knife to cut the vertebral body obliquely toward the center of the vertebral body at the upper and lower edges of the L3 vertebral body, and removed the cortical bone. The right vertebral body of L3 was treated in the same way, the nerve root stripper stripped the dura mater and the adhesion behind the vertebral body, processed and crushed the cortical bone behind the vertebral body with a sickle-like vertebral body processor, and removed the cortical bone of the vertebral body. Decompression of the bone and soft tissue around the nerve root to avoid compression of the nerve after reduction, temporary fixation of the L2 vertebral body and L4 vertebral body short rods. In the same way, the pedicle L1 vertebral body wedge-shaped osteotomy was performed, and the mold rod was pre-bent. The longitudinal connecting rod was pre-bent according to the shape of the mold rod, the angle of the L1 vertebral body was about 20°, and the angle of the L3 vertebral body was about 40°. After the short rod

was removed, the T10-L5 pedicle screw tail was cross-installed, the left L4 and L5 were screwed into the nut, the right T10-T12 was screwed into the nut, the prone position pad was removed and the operating table was reset. The connecting rod was put into the remaining nail tail. Properly and symmetrically compressed the L1/2 and L2/3 intervertebral spaces in sequence to close the osteotomy surfaces of L1 and L3. After the tail cap was locked, the fluoroscopy showed that the osteotomy angle of the vertebral body was satisfactory and the internal fixation position was good. After installing 2 beams, break the nail tail. Washed the incision and sutured the incision layer by layer, leaving a drainage tube for the wound. The wound was sutured layer by layer and wrapped with dressings.

The postoperative diagnosis was ankylosing spondylitis with kyphosis. The patient was 169cm after the operation, which was 32cm higher than before the operation. Imaging parameters after surgery: PI=60°, PT=38°, SS=22°, LL=52°, TLJ=15°, TK=19°, CBVB=13°.



**Figure 3.** Postoperative re-examination of spine X-rays: 1. Ankylosing spondylitis, Kyphosis, correction by L1, L3 pedicle wedge osteotomy, posterior T10-L5 pedicle screw fixation and postoperative changes; 2. Thoracolumbar degeneration Change; Ankylosing spondylitis.



**Figure 4.** Preoperative and postoperative comparison: the patient is 137cm before the operation, and the postoperative patient is 169cm, with an increase of 32cm.

After the operation, the patient not only restored the spine sagittal balance, and the spine was stable, but also the appearance and ability of daily living were significantly improved, and the effect was satisfactory.

### 3. Discussion

Ankylosing spondylitis kyphosis correction osteotomy indications are as follows: 1. The patient's sleep is severely affected or the ability of daily living is severely restricted due to the inability to lie down; 2. Compression of internal organs in the abdominal cavity caused by severe kyphosis seriously affects digestive function; 3. The patient's breathing movement is restricted due to severe kyphosis; 4. Conservative treatment is ineffective, and the patient requires surgery [4-7].

Each spinal osteotomy has different characteristics, including the range of correction angles, potential risks and suitable indications. Currently commonly used clinical spinal orthopedics are as follows: 1. Smith-Peterson Osteotomy (SPO): It is also called trans-articular process osteotomy and was first reported in 1945. It is mainly suitable for young patients without osteoporosis and ossification of the anterior longitudinal ligament. If the anterior longitudinal ligament is completely ossified, it may be challenging [8]. Generally, a single segment can be corrected by 10° [9]. 2. Pedicle Subtraction Osteotomy (PSO): This method uses the pedicle to perform vertebral body osteotomy to shorten the middle and posterior column. PSO is mainly suitable for correction of lordosis > 25°, sagittal imbalance > 10 cm, coronal and sagittal Patients with uneven surface alignment, very collapsed and rigid intervertebral disc space [10]. Generally, the average osteotomy angle of single-cone PSO osteotomy is 35-40°. For patients with severe overall kyphosis, correction of more than 60° is required to achieve satisfactory postoperative sagittal alignment. Two levels are recommended PSO [11]. 3. Vertebral Column Resection (VCR): It is suitable for operations such as moderate to severe spinal deformities, spinal tumors, congenital kyphosis, and hemipyrectomy [12, 13]. 4. Vertebral Column Decancellation (VCD): It is an improvement of the original osteotomy technique and is mainly suitable for severe acute-angle spinal deformities [14].

Adequate preoperative planning is a key issue in the correction of kyphosis deformity in ankylosing spondylitis. There are many ways to calculate the osteotomy angle required for spinal imbalance, mainly including empirical judgment, paper-cutting splicing, professional software analysis, modeling and other methods. CBVA and sagittal spine imbalance distance are two important parameters to determine the osteotomy plane and the osteotomy angle. CBVA is the angle between the line of the mandible and the brow arch and the plumb line when the patient is in the straight position of the hip and knee joints. The sagittal spine imbalance distance is the vertical distance from the upper posterior corner of the sacrum to the C7 plumb line on the full-length lateral X-ray film in the standing position.

Determining the angle of osteotomy cannot only rely on the Cobb angle of kyphotic deformity, nor can it blindly perform osteotomy correction based on the experience of the surgeon. Because the size of the osteotomy angle will directly affect the size of the CBVA, the patient's occupation and living habits should be considered. For patients who often work at the desk with their heads down, the osteotomy angle should be less than the degree of CBVA to meet their work and life needs. Under the same correction angle, osteotomy at lower level vertebrae can obtain higher safety. Osteotomy in the lumbar vertebrae area can allow a larger operation space and correction angle, which means that osteotomy can be performed more safely. The third vertebra is the vertex of the lumbar vertebrae, and osteotomy at the vertex should achieve a better correction effect. The second vertebra is usually close to the thoracolumbar kyphosis, and it is recommended that most osteotomies are located in the second and third lumbar vertebrae [15]. However, osteotomy is usually not performed at L4 or L5 because L4 and L5 are not the apex of lumbar lordosis, and the fusion of the short lever arm at the distal end of the fusion with the sacrum can cause discomfort or inability to sit on the floor [11]. For severe thoracolumbar kyphosis, biconical osteotomy is recommended. The ideal combination of osteotomy sites is L1 and L3. If the vertex of the kyphosis is above T12, T12 and L2 can be selected as the osteotomy site [16]. Continuous two-segment spine osteotomy is not recommended, because excessive shortening of the two-segment spine area may cause flexion of the dura mater and spinal cord, which is very dangerous [17].

Although two-level pedicle subtraction osteotomy has a good corrective effect, the operation is difficult, the operation time is long, and the risk of nerve damage is high. It requires more comprehensive perioperative treatment and finer intraoperative operations to reduce perioperative complications. Complications of transpedicular lumbar osteotomy mainly include nerve injury, cerebrospinal fluid leakage, osteotomy incomplete closure, fixed segmental fracture, incision infection, abdominal skin distraction injury, loosening of internal fixation, false joint formation, Superior mesentery artery syndrome etc.[18-20]. In patients with ankylosing spondylitis, the dura mater is thin and closely adheres to the ossified ligamentum flavum. Careful manipulation should be performed during the separation process. If a spinal dura tear occurs during the operation, it is generally difficult to repair it directly. When the rupture is large, an artificial spinal dura mater can be used to repair it. When the rupture is small, a suitable size of myofascial membrane can be cut from the wound, repaired with ear-brain glue, and then covered with gelatin sponge [16, 21]. A large number of osteotomies and a large open osteotomy surface in the PSO orthopedic stage result in a significantly higher blood oozing volume in this stage than in other stages. At the same time, it is the most challenging and time-consuming stage of the entire surgical process. Subperiosteal dissection and controlled blood pressure reduction can significantly reduce the amount of intraoperative blood loss.

For patients with large intraoperative blood loss, autologous blood transfusion is feasible [22].

## 4. Conclusion

For the treatment of patients with severe ankylosing spondylitis and kyphosis, two-level pedicle subtraction osteotomy can achieve ideal correction and clinical effects. However, the operation is very difficult and requires sufficient preoperative planning, comprehensive perioperative treatment and more delicate intraoperative operations, which need to be performed by an experienced spinal surgery team.

## References

- [1] Braun, J. and J. Sieper, *Ankylosing spondylitis*. Lancet, 2007. 369 (9570): p. 1379-1390.
- [2] Vergara, M. E., et al., *Postural control is altered in patients with ankylosing spondylitis*. Clin Biomech (Bristol, Avon), 2012. 27 (4): p. 334-40.
- [3] Koller, H., et al., *Osteotomies in ankylosing spondylitis: where, how many, and how much?* Eur Spine J, 2018. 27 (Suppl 1): p. 70-100.
- [4] Hu, F., et al., *Improvement of Sleep Quality in Patients With Ankylosing Spondylitis Kyphosis After Corrective Surgery*. Spine (Phila Pa 1976), 2020. 45 (23): p. E1596-e1603.
- [5] Park, J. S., et al., *Psychological Changes and Employment Outcomes After Kyphosis Correction in Patients With Ankylosing Spondylitis*. Spine (Phila Pa 1976), 2019. 44 (14): p. 996-1002.
- [6] Liu, C., et al., *Changes of the abdomen in patients with ankylosing spondylitis kyphosis*. Spine (Phila Pa 1976), 2015. 40 (1): p. E43-8.
- [7] Fu, J., et al., *Pulmonary function improvement in patients with ankylosing spondylitis kyphosis after pedicle subtraction osteotomy*. Spine (Phila Pa 1976), 2014. 39 (18): p. E1116-22.
- [8] Cho, K. J., et al., *Comparison of Smith-Petersen versus pedicle subtraction osteotomy for the correction of fixed sagittal imbalance*. Spine (Phila Pa 1976), 2005. 30 (18): p. 2030-7; discussion 2038.
- [9] Burton, D. C., *Smith-Petersen osteotomy of the spine*. Instr Course Lect, 2006. 55: p. 577-82.
- [10] Gupta, M. C., et al., *Pedicle Subtraction Osteotomy*. JBJS Essent Surg Tech, 2020. 10 (1).
- [11] Kim, K. T., et al., *Clinical outcome results of pedicle subtraction osteotomy in ankylosing spondylitis with kyphotic deformity*. Spine (Phila Pa 1976), 2002. 27 (6): p. 612-8.
- [12] Suk, S. I., et al., *Posterior vertebral column resection for severe spinal deformities*. Spine (Phila Pa 1976), 2002. 27 (21): p. 2374-82.
- [13] Bridwell, K. H., *Decision making regarding Smith-Petersen vs. pedicle subtraction osteotomy vs. vertebral column resection for spinal deformity*. Spine (Phila Pa 1976), 2006. 31 (19 Suppl): p. S171-8.

- [14] Wang, Y. and L. G. Lenke, *Vertebral column decancellation for the management of sharp angular spinal deformity*. Eur Spine J, 2011. 20 (10): p. 1703-10.
- [15] Xin, Z., et al., *Clinical results and surgery tactics of spinal osteotomy for ankylosing spondylitis kyphosis: experience of 428 patients*. J Orthop Surg Res, 2019. 14 (1): p. 330.
- [16] Zheng, G. Q., et al., *Two-level spinal osteotomy for severe thoracolumbar kyphosis in ankylosing spondylitis. Experience with 48 patients*. Spine (Phila Pa 1976), 2014. 39 (13): p. 1055-8.
- [17] Kawahara, N., et al., *Influence of acute shortening on the spinal cord: an experimental study*. Spine (Phila Pa 1976), 2005. 30 (6): p. 613-20.
- [18] Bridwell, K. H., et al., *Complications and outcomes of pedicle subtraction osteotomies for fixed sagittal imbalance*. Spine (Phila Pa 1976), 2003. 28 (18): p. 2093-101.
- [19] Hyun, S. J. and S. C. Rhim, *Clinical outcomes and complications after pedicle subtraction osteotomy for fixed sagittal imbalance patients: a long-term follow-up data*. J Korean Neurosurg Soc, 2010. 47 (2): p. 95-101.
- [20] Buchowski, J. M., et al., *Neurologic complications of lumbar pedicle subtraction osteotomy: a 10-year assessment*. Spine (Phila Pa 1976), 2007. 32 (20): p. 2245-52.
- [21] Zhang, X., et al., *Vertebral column decancellation: a new spinal osteotomy technique for correcting rigid thoracolumbar kyphosis in patients with ankylosing spondylitis*. Bone Joint J, 2016. 98-b (5): p. 672-8.
- [22] Keating, E. M. and J. B. Meding, *Perioperative blood management practices in elective orthopaedic surgery*. J Am Acad Orthop Surg, 2002. 10 (6): p. 393-400.