

**Case Report**

# The Unicorn Syndrom: Case of a Giant Skull Invasive Metastasis of a Pulmonary Cancer

Maxime Rivollier<sup>1,\*</sup>, Benoit Marlier<sup>1</sup>, Jean-Charles Kleiber<sup>1</sup>, Stanislas Loniewski<sup>1</sup>,  
Claude-Fabien Litre<sup>1</sup>, Fabien Rivollier<sup>2</sup>

<sup>1</sup>Hopital Maison Blanche, University of Reims Champagne Ardenne, Reims, France

<sup>2</sup>Hopital Nord Saint-Etienne, University Jean Monnet, Saint-Etienne, France

**Email address:**

[mrivollier@chu-reims.fr](mailto:mrivollier@chu-reims.fr) (M. Rivollier)

\*Corresponding author

**To cite this article:**

Maxime Rivollier, Benoit Marlier, Jean-Charles Kleiber, Stanislas Loniewski, Claude-Fabien Litre, Fabien Rivollier. The Unicorn Syndrom: Case of a Giant Skull Invasive Metastasis of a Pulmonary Cancer. *Journal of Surgery*. Vol. 9, No. 2, 2021, pp. 49-52.

doi: 10.11648/j.js.20210902.11

**Received:** February 16, 2021; **Accepted:** March 5, 2021; **Published:** March 12, 2021

---

**Abstract:** *Background:* Tumors of cranial vault are quite uncommon but represent a major diagnostic and therapeutic issue. Skull involvements are rarely primitive tumors. Mostly, cranial vault tumors are metastases of lung, breast, thyroid, kidney and prostate cancers. These lesions often grow quickly and sometimes become infected, which raises the issue of how to manage them. *Patient:* We operated a patient of 64 years old for a large, painful and sweating tumor of the frontal cranial vault with subcutaneous, meningeal and cerebral parenchyma dissemination. The lesion grew rapidly following a frontal shock within 3 months. Initially, according to history, we thought of an infected abscess. However, thanks to MRI, the possibility of a tumor is quickly suggested. We choose to operate quickly in order to obtain a histological tissue which permits to orient the additional medical treatment. This also allows us to perform a plasty at the same time. Histological analysis assets a metastasis of a pulmonary adenocarcinoma undiagnosed at this time. Therefore, we were able to refer the patient to oncology for the rest of medical exams and treatment. The aesthetic result is satisfactory too. *Conclusion:* We report this case to explain our care. We also submit this article to emphasize that careful skin examination can provide valuable clues to guide the diagnosis.

**Keywords:** Scalp, Metastasis, Lung Cancer, Bone, Cranial Vault

---

## 1. Introduction

Cranial vault is a possible location for several malignancies, especially carcinoma of the lung, breast, thyroid, renal cell carcinoma, melanoma in adults and neuroblastoma in children. [1]

In France, adenocarcinoma pulmonary represent 49000 new cases each year. Principal sites of metastasis are chest, abdomen, head and neck. [2] 20 to 40% of patients have bone metastases at diagnosis or during the course of lung cancer. However, cranial vault metastasis are very rare (<1%).

These are most often multiple metastases (80%) rather than single metastases (20%). Despite therapeutic progress, the prognosis remains poor. [3] Skull metastasis can cause various clinical symptoms but early diagnosis is crucial for selecting

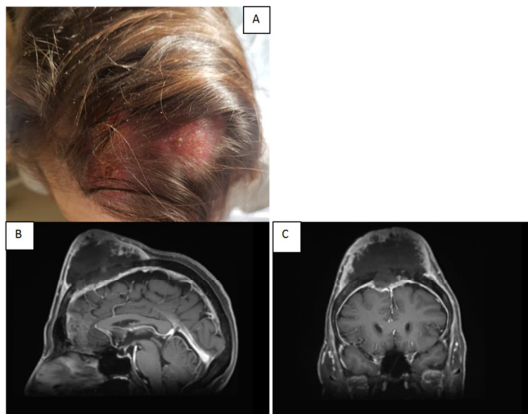
treatment. MR also contributes to understanding their type, site, multiplicity, and their invaded structures. [1] In this paper, we are going to present the clinic history and surgical treatment of a giant frontal metastasis of a primitive lung.

## 2. Case Report

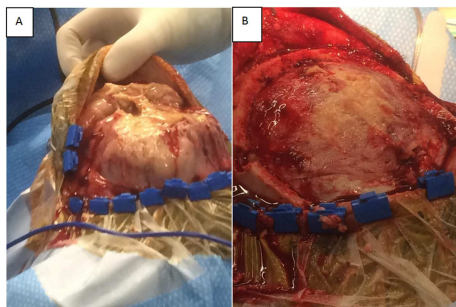
The patient was a 65 years old female. She had no medication but was a heavy smoker. There is a notion of light chronic obstructive pulmonary disease without drugs. She came to the emergency room after a consultation with her attending physician. Patient explained that her story began 2 months before. She described the very rapid development of a frontal swelling, as a result of a frontal shock. Thus, her general practitioner asked her to consult at the emergency

room. Clinical examination showed massive tumefaction 10x11cm with headaches and the onset of psychomotor slowing down. No others neurological symptoms were noted. The skin was made up of a crusting erythematous background with pus oozing pustule. Lesions are not pruritic and not painful. C-Reactive-Protein was 88.6mg/L and white blood cells count was 12G/L. MRI with injection was performed on an emergency basis. (Figure 1)

Our main hypothesis was an abscessed hematoma, but MRI is more in favor of a tumor. The presence of malignancy criteria such as osteolysis and invasion of the upper longitudinal sinus with invasion of the soft tissues makes one suspect a tumor with invasion of the upper longitudinal sinus. We chose to operate this lesion quickly, two days later. In the operating room we performed a bitemporal incision, type Cairns-Unterberger, and found the tumor directly. It was not very hemorrhagic. (Figure 2) The lesion invaded the subcutaneous parts, the bony periosteum and dura as well as the upper longitudinal sinus (ULS). We had to exclude the invaded part of the ULS until we found a circulating part. The most complete tumor excision was performed, although it is certain that subcutaneous fragments remain in front of and behind the ULS. It was possible to place a MEDPOR® plasty.



**Figure 1.** Dermatological aspect (A) and cerebral MRI with injection of gadolinium, sagittal (A) and coronal (B).

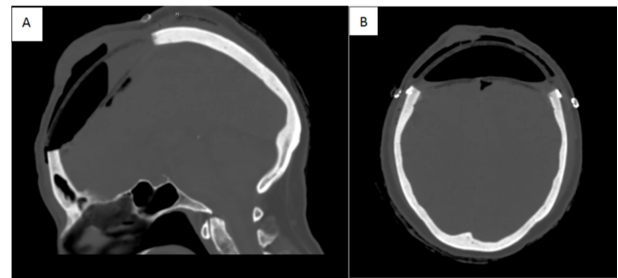


**Figure 2.** Intraoperative images, (A) shows the appearance of the lesion and (B) shows the invaded meninges after the cranial flap.

The control scanner is satisfactory. We observe a correct exclusion of the lesion. The plasty is in right place. Pneumencephaly, which is hypodense tone, is usual after this type of surgery and is resolved within a few days. (Figure 3) Postoperatively, there was no neurological deterioration to

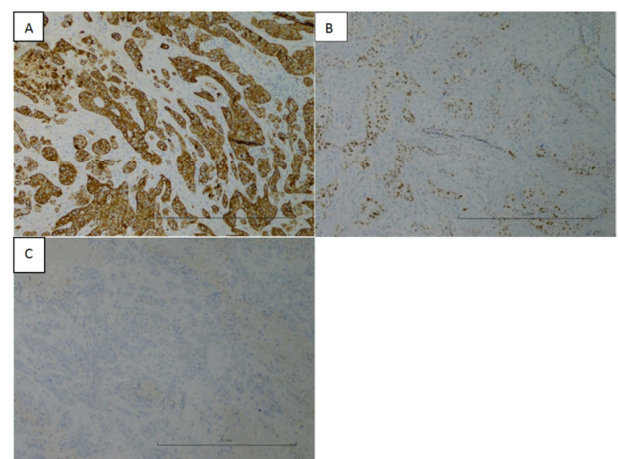
report. The samples were positive for enterococci faecalis. An infectious disease specialist started treatment with clindamycin 600 mg three times daily for 3 weeks.

The patient discharged hospital 5 days after the surgery. We therefore referred her to oncological management for the realization of the complementary examinations and the oncologic treatment. Body scanner reveals a large right hilar tumor with bilateral mediastinal adenopathy and bilateral pulmonary nodules. Initially, it was decided to urgently use hypo-fractionated loco-regional irradiation, with 5x7 Gy, followed by radio chemotherapy associated with immunotherapy on the primitive tumor. The introduced drugs were carboplatine and alimta with keytruda.



**Figure 3.** Post operative CT-scan, sagittal (A) and coronal (B).

Ten weeks after surgery, the final result reveals samples infiltrated by an adenocarcinoma of predominantly solid morphology whose immunohistochemical profile: CK7+, CK20-, TTF1+. It points to a primitive pulmonary origin. There is no expression of CK20, GATA3, Thyroglobulin and PAX8. We notice the presence of perinvertebral sheaths and vascular emboli. Bone flap is also infiltrated by adenocarcinoma. Tumor infiltration extends to the limits of bone resection: R1. Dura mater is also infiltrated by solid adenocarcinoma as well as the portion in contact with the cerebral parenchyma.



**Figure 4.** Tumor cells express cytokeratin 7 (A) as well as TTF1 (B), no expression of CK20 (C).

### 3. Discussion

We therefore believe this is a skull metastasis with

meningeal, subcutaneous and parenchyma dissemination. Obviously, this is a poor prognosis. Bone metastases significantly reduce the median survival of bronchopulmonary cancers compared to extra-bone metastases. [3, 4]

Lung carcinomas metastasis to the skull are only around 3% of total lung carcinoma bone metastases. This is in contrast to other carcinomas, such as hepatocellular tumors, which has been widely reported to present as a single skull metastasis as a first presentation. [5]

Metastases are the most frequent causes of tumors of the cranial vault in adults. All visceral cancers can metastasize to the vault, especially breast, lung and prostate cancers. In a study, broncho-pulmonary cancers are the 4th most common cause of skull metastasis. [6, 8] Another study made on 175 patients found that 55% of skull metastases originated from breast origin, 14% from lung carcinoma, 6% from prostate cancer, and 25% from other origins. [16, 18]

Only two cases in literature have presented a case of solitary skull mass as the first presentation of lung adenocarcinoma, in a patient with no history of a previous malignant disease, presented with a skull swelling. To our knowledge, we are the third. [7, 10, 17]

The route of metastasis in this case is not clear but transmission by mandibular lymphatics is the main hypothesis. Locally, very often, there is a close relationship between the primary cancer and the cutaneous metastatic localizations. For this reason, bone metastasis with extension is the main etiology. [5]

Their growth is usually rapid before stabilizing in their expansion, however they do not tend to regress spontaneously. [14, 15] Sometimes metastases become bubbly or erode. Others have an inflammatory erysipeloid or even sclerotic or an armoured appearance. [9, 11] Some become infected as in our case.

From a surgical point of view, it is important to achieve a viable reconstruction and a tight closure because the risk of infection in cranial plasties is high. It might generate serious consequences. [12, 13]

## 4. Conclusion

Solitary cranial vault metastasis as the first sign of an occult lung cancer is an extremely rare occurrence. In our case, we describe the initial care of a giant skull metastasis of a lung adenocarcinoma. Consequently, a cranial vault metastasis has to be stated in front of fast growing scalp tumefaction for adults. Various clinical symptoms can occur, notably infectious signs as in our case. As mentioned, patients with skull metastases are often in an advanced stage of disease with further occult metastasis. Then, in front of patients with a scalp tumefaction it is absolutely essential to eliminate a cancer lesion in order to avoid delaying subsequent treatment.

## Conflict of Interest

The authors declare that they have no competing interests.

## Funding

This article was written with the financial support of the University of Reims Champagne Ardennes URCA.

## References

- [1] De Monte F, Hanbali F, Ballo MT (2005) Skull base metastasis. In: Berger MS, Prados MD (eds) Text book of neuro-oncology. Elsevier, Philadelphia.
- [2] Veena Gupta, Namita Bhutani, and Nisha Marwah, Rajeev Sen. Scalp metastasis as an initial presentation of lung adenocarcinoma: A case report and literature review International Journal of Surgery Case Reports 41 (2017) 327–331.
- [3] Colas L, Caron S, Cotten A. Skull vault lesions: a review. *AJR Am J Roentgenol* 2015; 205: 840–7. doi: 10.2214/AJR.14.1341.
- [4] C. S. Chiu, C. Y. Lin, T. T. Kuo, Y. Z. Kuan, M. J. Chen, H. C. Ho, et al., Malignant cutaneous tumors of the scalp: a study of demographic characteristics and histologic distributions of 398 Taiwanese patients, *J. Am. Acad. Dermatol.* 52 (2) (2007) 448–452.
- [5] Turner R. C., Lucke-Wold B. P., Hwang R., Underwood B. D. Lung cancer metastasis presenting as a solitary skull mass. *Journal of Surgical Case Reports*. 2016; 2016 (6) doi: 10.1093/jscr/rjw116.
- [6] S. L. Kall, J. E. Koblinski, Genes That Mediate Metastasis Organotropism. In: *Madame Curie Bioscience Database* [Internet], Landes Bioscience, Austin (TX), 2000.
- [7] M. R. Hussein, Skin metastasis: a pathologist's perspective, *J. Cutan. Pathol.* 37 (2010) e1–20 (PubMed).
- [8] H. Sugiura, K. Yamada, T. Sugiura, T. Hida, and T. Mitsudomi, Predictors of survival in patients with bone metastasis of lung cancer, *Clinical Orthopaedics and Related Research*, vol. 466, no. 3, pp. 729–736, 2008.
- [9] D. P. Lookingbill, N. Spangler, F. M. Sexton, Skin involvement as the presenting sign of internal carcinoma. A retrospective study of 7316 cancer patients, *J. Am. Acad. Dermatol.* 22 (1) (1990) 19–26.
- [10] R. A. Krathen, I. F. Orengo, T. Rosen, Cutaneous metastasis: a meta-analysis of data, *South. Med. J.* 96 (2003) 164–167.
- [11] Altalhy A, Maghrabi Y, Almansouri Z, Baeesa SS. Solitary Skull Metastasis as the First Presentation of a Metachronous Primary Lung Cancer in a Survivor from Pancreatic Cancer. *Case Rep Oncol Med*. 2017; 2017: 5674749. Epub 2017 Jul 24. PMID: 28811947; PMCID: PMC5546056.
- [12] Spencer PS, Helm TN. Skin metastases in cancer patients. *Cutis*. 1987; 39 (2): 119–21 [PubMed] [Google Scholar].
- [13] Lee J. H., Ahn S. J., Kim H. J., Jang S. E., Noh G. Y., Kim H. R. Cutaneous metastasis from lung cancer: a single-institution retrospective analysis. *Tuberc. Respir. Dis.* 2011; 70 (2): 139–142.
- [14] Som PM, Curtin HD (2011) Head and neck imaging, 5th edn. Mosby, Inc., St. Louis, MO.

- [15] Hakim DN, Pelly T, Kulendran M, Caris JA (2015) Benign tumours of the bone: a review. *J Bone Oncol* 4: 37–41.
- [16] International Agency for Research on Cancer (2013) WHO Classification of Tumours of Soft Tissue and Bone, 4th edn. WHO Press, Lyon.
- [17] Doganay S, Altinok T, Alkan A, Kahraman B, Karakas HM (2011) The role of MRS in the differentiation of benign and malignant soft tissue and bone tumors. *Eur J Radiol*.
- [18] Hidaka T., Ishii Y., Kitamura S. Clinical features of skin metastasis from lung cancer. *Intern. Med.* 1996; 35: 459–462.