



Effect of Swallowing Function After ROI-C Anterior Cervical Interbody Fusion

Guowei Zhang, Zhaohui Chen, Qiuling Liu, Zhisheng Ji, Chunhai Lan, Hongsheng Lin*

Department of Orthopedics, the First Affiliated Hospital of Jinan University, Guangzhou, China

Email address:

tlinhsh@jnu.edu.cn (Hongsheng Lin)

*Corresponding author

To cite this article:

Guowei Zhang, Zhaohui Chen, Qiuling Liu, Zhisheng Ji, Chunhai Lan, Hongsheng Lin. Effect of Swallowing Function After ROI-C Anterior Cervical Interbody Fusion. *Journal of Surgery*. Vol. 4, No. 6, 2016, pp. 141-145. doi: 10.11648/j.js.20160406.14

Received: December 22, 2016; **Accepted:** January 3, 2017; **Published:** January 21, 2017

Abstract: The difference of swallowing function between a new zero-notch anterior cervical interbody fusion device (ROI-C) and classical method with the plate using in anterior cervical decompression and fusion (ACDF) were discussed and analyzed. 57 cases in the First Affiliated Hospital of Jinan University from Feb 2013 to Mar 2016 who underwent ACDF were retrospectively reviewed. There were 33 cases in group using with ROI-C and 24 cases in group using with plate. The difference of dysphagia incidence and severity were analyzed by comparing with the image data before and after operation. The dysphagia correlative risk factors analyzed by logistic regression test were internal fixation material and thickness of 3-days post-operative prevertebral soft tissue (PST). When the PST (3-days post-operative) was larger than 10.44mm, the chance of developing postoperative was significantly greater. The thickness of 3-days post-operative PST in ROI-C group was significantly lower than that in plate group ($P < 0.05$). The thickness of 3-days post-operative PST swelling width ROI-C group was significantly lower than that in plate group ($P < 0.05$). The index of 3-days post-operative PST was lower but no significant in ROI-C group than that of group Plate ($P > 0.05$). 3-days post-operation, the dysphagia incidence and severity were significantly lower in ROI-C group than that in plate group ($P < 0.05$). The dysphagia correlative risk factors are internal fixation material and thickness of 3-days post-operative PST. When the 3-days post-operative PST larger than 10.44 mm, the chance of developing postoperative is significantly greater. Zero-notch ROI-C anterior cervical interbody fusion device is associated with less stimulations to esophagus, lower postoperative dysphagia incidence, milder severity of dysphagia and shorter period of dysphagia in ACDF.

Keywords: Anterior Cervical Decompression and Fusion, Thickness of Prevertebral Soft Tissue, Dysphagia

1. Introduction

Anterior cervical discectomy (decompression) and fusion (ACDF) is a prior method for the treatment of many cervical vertebrae diseases, such as degeneration, congenital malformations, pathological and traumatic fractures [1]. However, complications, including hematoma formation, infection, failure of internal fixation, recurrent laryngeal nerve injury, esophageal injury, vertebral artery and nerve injury, have been reported [2]. Especially, dysphagia caused by esophageal injury after the surgery is particularly prominent. Accordingly, the early postoperative swallowing dysfunction rate is about 1%-80%, and also there are about 3%-21% of patients with long-term dysphagia symptoms [3-5]. The

mechanisms of dysphagia remain to be elucidated, while the most acceptable hypothesis is due to the postoperative soft tissue swelling [6-9]. In the current study, we measured the thickness of anterior soft tissue by postoperative cervical X-ray film, aiming to investigate the impact of ACDF with zero- notch ROI-C on dysphagia. Comparing to patients on ACDF with anterior plate fixation, we tried to determine role of the thickness of anterior soft tissue in dysphagia, trying to provide evidences to reduce complications of ACDF.

2. Methods

2.1. General Data

From Feb 2013 to Mar 2016, 57 patients (27 male, 30

female) under ACDF were included and subjected for retrospective analysis. By the difference of internal implantation device, patients were divided into 2 groups: (1) 33 cases of ROI-C group (zero-notch device, 13 male and 20 female); age, 27-77 years old (average 51.97 ± 11.34 years old); follow-up time, 5-17 months (average 10.72 ± 4.86 months); (2) 24 cases of Titanium (Ti) plate group (combined anterior intervertebral fusion device, 14 male and 10 female); age, 39-84 (average 52.63 ± 11.67); follow-up time, 1.5-22 months (average 10.26 ± 8.88 months).

2.2. Inclusion Criteria

Patients with the following characters were included: (1) confirmed diagnosis of cervical degenerative lesion, with instability caused by fractures or spondylolisthesis; (2) symptoms matched the corresponding segment indicated by X-ray, CT and MR; (3) Imaging suggest the lesion located between C3-T1, 1 to 3 segments requiring decompression; (4) cervical spondylotic radiculopathy patients treated by none surgical methods showed no significant improvement, still with obvious symptoms of spinal cord nerve compression; (5) with complete medical records, non-mental illness patients; (6) no dysphagia symptoms before surgery.

2.3. Exclusion Criteria

Patients with the following characters were excluded: (1) with dysphagia symptoms before surgery; (2) esophageal cervical spondylosis or imaging indicated that huge

osteophyte formation at the anterior edge of the lesion segment (height > 16 mm) [9]; (3) with spinal cord compression by serious ossification of posterior longitudinal ligament, ankylosing spondylitis, deformity and tumor; (4) combined with mental illness and severe osteoporosis; (5) other factors affect swallowing function during the follow-up: developmental abnormalities, CNS diseases, tumor metastasis/compression, severe trauma, cervical revision surgery, esophageal injury (physical/chemical /biological).

2.4. Measurements

Imagines were measured by Huahai HiNet PACS medical image inspection system (images were enlarged 5x, each index was measured twice and was averaged to reduce errors). Penning method [8] was used to measure the prevertebral soft tissue thickness (PST) of C3-7 vertebrae in the cervical spine (Figure 1). For those with obvious osteophyte formation at the anterior edge of the lesion segment (osteophyte height > 5 mm) [9]. The degree of PST swelling width equals post-operative PST minus pre-operative PST. The PST index of prevertebral soft tissue equals cervical PST/ Vertebral sagittal diameter. Degrees of dysphagia were shown in Table 1 [4].

Table 1. Bazaz-Yoo Dysphagia Score.

Severity	Symptoms	
	Liquid	Solid
None	None	None
Mild	None	Rare
Moderate	None or rare	Occasionally (only with specific food)
Severe	None or rare	Frequent (majority of food)

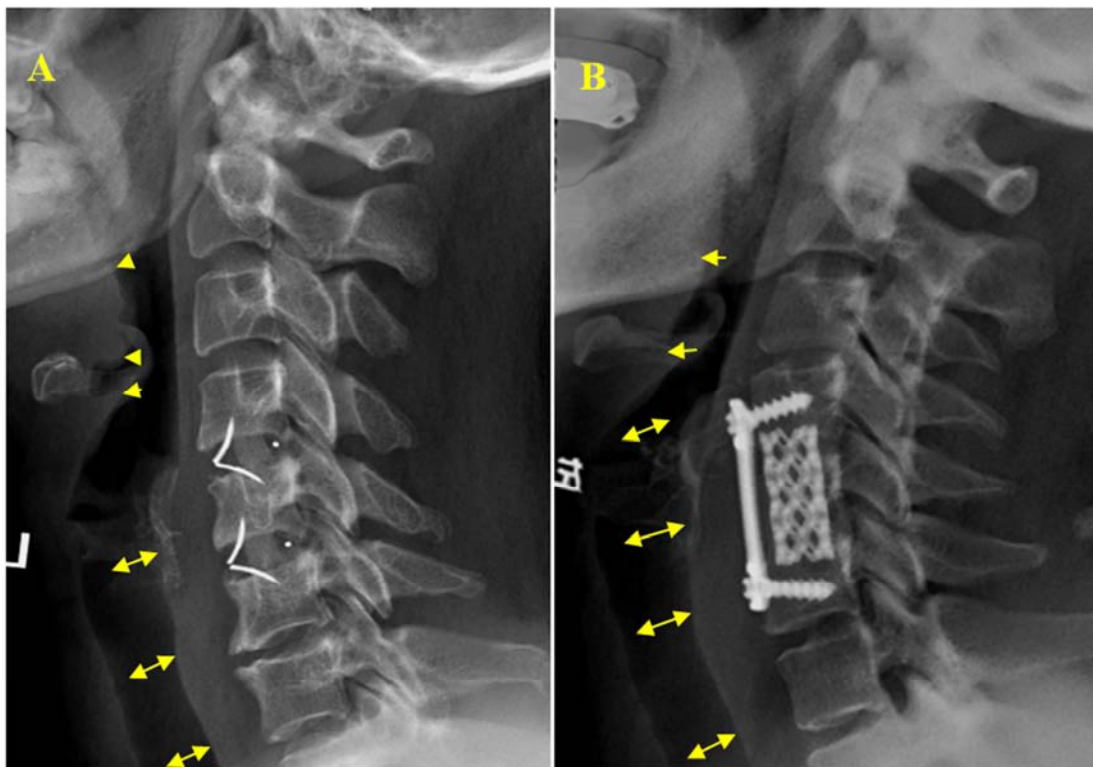


Figure 1. (A) Measurement of PST in ROI-C group: distances of C3, C5-7 vertebral anterior edge, C4 vertebral anterior superior edge to posterior trachea, get the average value as the horizontal PST. (B) Measurement of PST in titanium plate group: the distance between the front border of plate to posterior trachea.

2.5. Statistical Analysis

Data were analyzed by SPSS 19.00, dependent *t*-tests and Pearson correlations were used when comparing measures between the two groups. *P* < 0.05 means statistical significant differences.

3. Results

We compared the PST, swelling width of PST, PST index between the ROI-C group and the Titanium plate group in 3-days, 6-weeks post-operation and the last follow-up. We found that the values of PST 3-days after operation between

the two groups showed significant differences (*P* < 0.05), while values of 6 weeks post-operation and the last follow-up showed no significant differences (*P* > 0.05). PST values in ROI-C group were lower than that in Ti plate group (Figure 2A). The swelling width of PST in 3-days post-operation and the last follow-up showed significant difference (*P* < 0.05, Figure 2B). The PST index showed no difference in both groups (Figure 2C). We got the average PST value of 10.44 mm for the threshold value and found that 3-days post-operation, if PST value larger than this average value, the rate of dysphagia was higher than that with lower PST value (< 10.44) (Figure 2D).

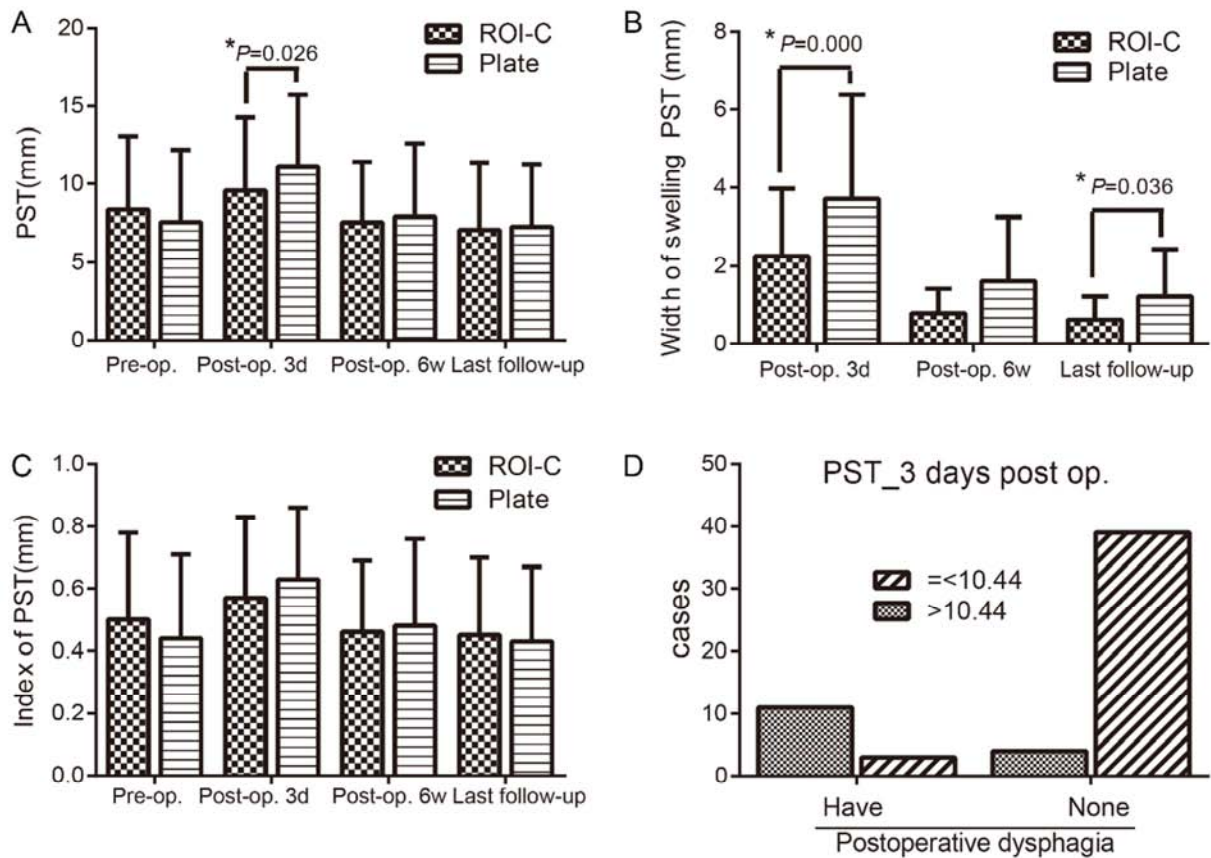


Figure 2. PST values (A), swelling width of PST (B) and PST index (C) in the ROI-C and plate groups were shown. The relationship of PST threshold and dysphagia.

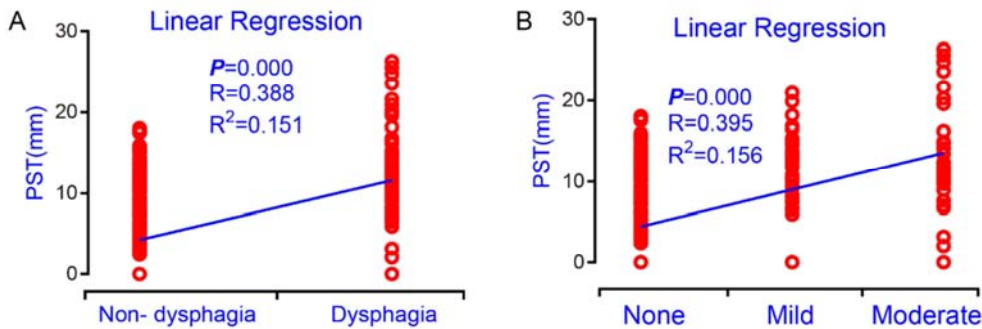


Figure 3. The linear regression for risk factor analysis. The relationship of 3-days post-operative PST values and dysphagia (A) and severity of dysphagia (B) were shown.

Furthermore, we calculated the rate of dysphagia (Table 2). We then analyzed the risk factor of dysphagia. Logistic analyses were performed with potential risk factors including sex, age and implant material, measures of 3 days post-operation (PST, swelling width of PST, PST index). As shown in Table 3, the results showed that the risk factors were implant material and 3-days post-operative PST values. A linear relationship was shown between 3-days post-operative PST value with the dysphagia (Figure 3A) and with dysphagia

severity (Figure 3B).

Table 2. The rate of dysphagia in two groups.

Severity	Rate (Cases)	
	ROI-C group (33 cases)	Ti Plate group (24 cases)
None	90.9% (12 male, 18 female)	50.0% (9 male, 3 female)
Mild	9.1% (1 male, 2 female)	25.0% (3 male, 3 female)
Moderate	0	25.0% (2 male, 4 female)
Severe	0	0

Table 3. Multiple factor analysis of pharyngeal difficulty.

Risk factor	B	P	Exp (B) OR	95.0% C. I. for EXP (B)	
				Lower	Upper
Internal fix device (ROI-C, plate)	1.391	0.006	4.017	1.491	10.823
3 days post-operative PST	0.172	0.011	1.187	1.041	1.354

4. Discussion

As a mature anterior cervical surgery method, ACDF is applied for degenerative cervical disc herniation with confirmed symptoms of spinal cord and/or nerve root, those non-surgical method cannot alleviate [1]. Because of the effective outcome, ACDF is widely recognized and applied in clinical practice. However, the use of anterior steel plate widens the narrow anterior gap, thus compresses the esophagus leading to the dysphagia. Accordingly, the rate of post-operative dysphagia differs, statistically early dysphagia ranging from 1% to 80%, chronic dysphagia 3%-21% [3-5].

The detailed mechanisms of post-operative dysphagia remain to be elucidated, while the hypothesis of post-operative soft tissue swelling is more acceptable. Suk and the colleagues suggested that due to the operation, anterior soft tissues congested and hematoma formed, the anterior usage of steel plate further stimulate the soft tissues, increasing the PST thickness, the esophagus becomes narrow due to the pressure, and finally leading to dysphagia [6].

Compared with Ti steel plate, the ROI-C fusion system is much simpler with no anterior steel implant. Hacker-Gilbert and the colleagues found that simple interbody fusion and artificial disc replacement would not lead to dysphagia, with lower rate of dysphagia than Ti steel [7]. Hofstetter and the colleagues found that another zero-notch cage (Zero-P) also can decrease the post-operative dysphagia [10]. Our results showed that the application of ROI-C cage lead to the reduced dysphagia rate and severity, than Ti plate group, which is consistent with previous reports.

In general, we identified the risk factor for the happening of post-operative dysphagia; and found that when 3-days post-operative PST value was large than 10.44 mm, the risk would increase. The application of ROI-C device in ACDF show good clinical outcome with smaller degree of anterior soft tissue swelling postoperatively, no compression to the esophagus, lower effect to swallowing function, showing the advantages of lower rate of dysphagia and lower severity and short duration.

5. Conclusion

- (1) Plate implanting and 3-days post-operative PST value are risk factors for post-operative dysphagia in ACDF.
- (2) When 3-days post-operative PST value is larger than 10.44 mm, the risk of post-operative dysphagia increases.
- (3) The application of zero-notch devices like ROI-C reduced dysphagia rate and severity.

Acknowledgments

The authors declare no conflict of interests. This work was supported by the Natural Science Foundation of Guangdong Province (2014A030313357), the National Health and Family Planning Commission of the People's Republic of China (No. W2013ZT083) and Medical Scientific Research Foundation of Guangdong Province (A2016038).

References

- [1] Denaro, V. and A. Di Martino, Cervical spine surgery: an historical perspective. *Clin Orthop Relat Res*, 2011, 469 (3): 639-48.
- [2] Bednar, D. A. and W. Al-Tunaib, Failure of reconstitution of open-section, posterior iliac-wing bone graft donor sites after lumbar spinal fusion. Observations with implications for the etiology of donor site pain. *Eur Spine J*, 2005, 14 (1): 95-8.
- [3] Riley, L. H., 3rd, A. R. Vaccaro, J. R. Dettori, and R. Hashimoto, Postoperative dysphagia in anterior cervical spine surgery. *Spine (Phila Pa 1976)*, 2010, 35 (9 Suppl): S76-85.
- [4] Lee, M. J., R. Bazaz, C. G. Furey, and J. Yoo, Influence of anterior cervical plate design on Dysphagia: a 2-year prospective longitudinal follow-up study. *J Spinal Disord Tech*, 2005, 18 (5): 406-9.
- [5] Baron, E. M., A. M. Soliman, J. P. Gaughan, L. Simpson, and W. F. Young, Dysphagia, hoarseness, and unilateral true vocal fold motion impairment following anterior cervical discectomy and fusion. *Ann Otol Rhinol Laryngol*, 2003, 112 (11): 921-6.

- [6] Suk, K. S., K. T. Kim, S. H. Lee, and S. W. Park, Prevertebral soft tissue swelling after anterior cervical discectomy and fusion with plate fixation. *Int Orthop*, 2006, 30 (4): 290-4.
- [7] Hacker, R. J., J. C. Cauthen, T. J. Gilbert, and S. L. Griffith, A prospective randomized multicenter clinical evaluation of an anterior cervical fusion cage. *Spine (Phila Pa 1976)*, 2000, 25 (20): 2646-54; discussion 2655.
- [8] Dai, L. Y. and L. S. Jia, Radiographic measurement of the prevertebral soft tissue of cervical vertebrae. *Chin Med J (Engl)*, 1994, 107 (6): 471-3.
- [9] Yue, W. M., W. Brodner, and T. R. Highland, Persistent swallowing and voice problems after anterior cervical discectomy and fusion with allograft and plating: a 5- to 11-year follow-up study. *Eur Spine J*, 2005, 14 (7): 677-82.
- [10] Hofstetter, C. P., K. Kesavabhotla, and J. A. Boockvar, Zero-profile Anchored Spacer Reduces Rate of Dysphagia Compared With ACDF With Anterior Plating. *J Spinal Disord Tech*, 2015, 28 (5): E284-90.