

Case Report

Cervical Vertebrae Internal Fixation Revision in a Patient with Ankylosing Spondylitis: A Case Report

Jianxiong Wu, Yongchun Xiao, Hongsheng Lin, Zhisheng Ji, Guowei Zhang*

Department of Orthopedics, The First Affiliated Hospital of Jinan University, Guangzhou, China

Abstract

Ankylosing spondylitis (AS) is a chronic progressive inflammatory disease that affects the sacroiliac joints and surrounding joints. It is a seronegative spondyloarthritis that invades connective tissue. Managing cervical spine fractures in patients with AS is particularly challenging due to the severity of the deformity and the instability of the fracture. Cervical spine fracture combined with spinal cord injury is the leading cause of death and is strongly correlated with in-hospital mortality in patients with ankylosing spondylitis. There have been limited reports on the revision of cervical spine fractures after internal fixation in patients with AS. The case report is about a patient who is a 34-year-old man who underwent emergency surgery at a local hospital for a cervical spine fracture resulting from a car accident. A postoperative review revealed that the anterior internal fixation was detached, leading to a revision surgery being performed according to the patient's actual condition. Unfortunately, the internal fixation became dislodged following the initial surgery, exacerbating the patient's condition and leading to the development of pneumonia. In order to prevent the need for revision surgery, it is crucial to carefully evaluate and determine the most suitable surgical approach for patients with cervical spine fractures and spinal cord injury before proceeding with the initial surgery.

Keywords

Ankylosing Spondylitis, Cervical Spine, Dislocation, Fracture, Revision

1. Introduction

Ankylosing spondylitis (AS) is a seronegative spondyloarthritis that invades the connective tissue and is a chronic progressive inflammatory disease that can also affect the sacroiliac joints and surrounding joints [1]. Generally, it starts from the sacroiliac joint and gradually spreads upward to the joints, articular processes and nearby ligaments of the spine, and can even invade adjacent large joints, eventually causing fibrous or bony ankylosis and deformity. Patients with long-standing severe AS frequently experience spinal osteoporosis, rendering their spine vulnerable to fractures from external forces. This increases their risk of injury as even

minor external forces or specific movements can lead to fractures due to the secondary osteoporosis associated with AS [2]. The lower cervical spine is the most commonly injured part of the spine, followed by the thoracolumbar junction. When a patient suffers a cervical spine fracture, managing it is very challenging due to the severity of the deformity and the instability of the fracture [3]. The occurrence of cervical fractures poses a significant challenge in managing patients with AS. Despite receiving proper care, these patients are susceptible to various perioperative complications [4]. Cervical spine fracture combined with spinal cord injury was

*Corresponding author: zgw24@qq.com (Guowei Zhang)

Received: 30 January 2024; **Accepted:** 18 February 2024; **Published:** 29 February 2024



the leading cause of death, and had the strongest correlation with in-hospital mortality in patients with AS. Among the risk factors for internal fixation failure of cervical spine fractures are osteoporosis, chronic steroid use, smoking, diabetes, malnutrition, and obesity. These factors can contribute to the failure of internal fixation [5]. Limited reports exist regarding the revision after internal fixation of cervical fracture in patients with AS. Hence, this case report presents the experience of a 34-year-old patient with AS who underwent anterior open internal fixation of cervical fracture at a local hospital following trauma. Subsequently, the patient was transferred to our hospital's intensive care unit (ICU) for treatment three weeks later, due to the development of a high fever.

2. Case Report

The patient, a 34-year-old male, experienced a cervical spine fracture as a result of a car accident and subsequently underwent emergency surgery at a local hospital. It is worth noting that the patient had a history of ankylosing spondylitis. The following narrative provides a concise overview of the patient's traumatic event, the surgical procedure performed,

and the subsequent postoperative outcome.

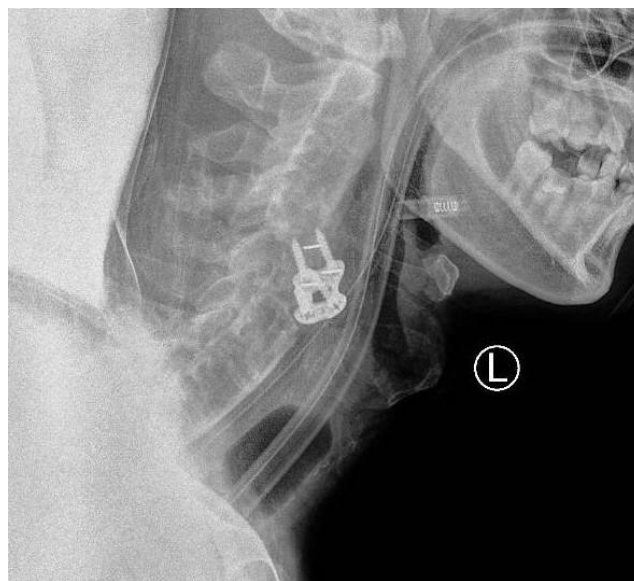


Figure 1. Anterior fixation were observed on preoperative x-rays.

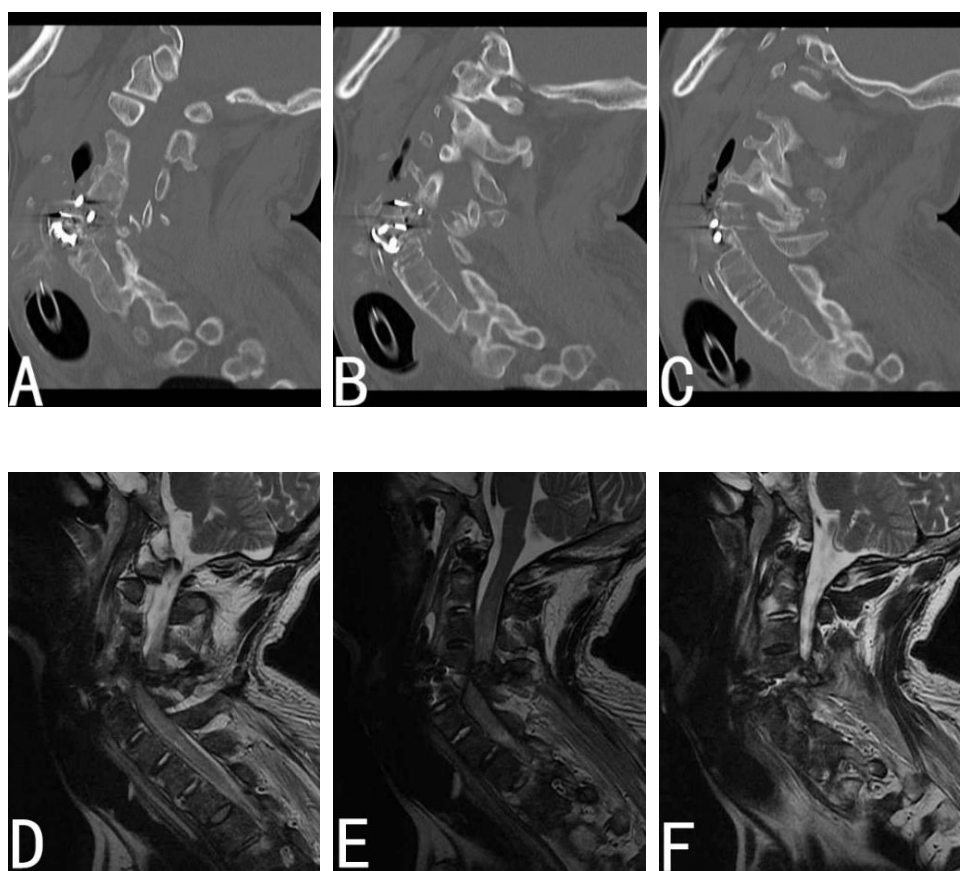


Figure 2. Loosening of internal fixator with the first anterior approaches (A-C). Preoperative T2-weighted MR image reveals spinal cord compression (D-F).

The patient collided with a tree while riding an electric bicycle, resulting in his neck becoming trapped against the

tree. Following the injury, the patient experienced a temporary impairment of consciousness. Upon regaining consciousness, the patient exhibited sensory and motor impairments in the limbs, but did not experience any urinary or fecal incontinence. The cervical spine CT and MR scans conducted at the local hospital revealed fractures in the C5 vertebral body and its associated structures. Additionally, the upper end of the C5 vertebral body was displaced at an angle and protruded into the spinal canal. The patient initially underwent anterior cervical intervertebral bone grafting fusion and internal fixation with plates and screws (neck 5/6) at the local hospital. During the operation, it was observed that there was an obvious fracture and dislocation of the neck 5/6, leading to significant bleeding. Subsequently, the patient's pneumonia worsened and necessitated transfer to the ICU of our hospital for further treatment. On physical examination, the patient exhibited sensory disturbance in the limbs, with a muscle strength grade of 0 and low muscle tone. Pain sensation was absent below the level of the first rib, and touch sensation was absent below the level of the sternal manubrium. The patient was able to shrug bilaterally, but had grade 0 muscle strength in the limbs, decreased muscle tone, absence of knee reflex and bilateral cremasteric reflex, and a positive left Papillon sign. Plain radiograph evaluation revealed a displaced fracture at the C4-C5 disc space [Figure 1]. computerized tomography confirmed fracture dislocations at C6 –C7. Further improvement of MRI and CT revealed the following findings: postoperative changes in the fifth and sixth cervical vertebrae; angular deformity of the cervical vertebrae; comminuted fractures of the C5-6 vertebrae with partial bone fragments protruding into the spinal canal; spinal canal stenosis; and compression of the cervical spinal cord at the corresponding level, resulting in deformation [Figure 2]. In order to address the instability of the cervical spine fracture, the loss of anterior internal fixation, and the compression of the cervical spinal cord, a comprehensive surgical plan was devised. This plan involved posterior decompression of the C5 and C6 spinal canals, reduction of the fracture and dislocation, internal fixation using pedicle rods from C2 to T1, removal of the anterior cervical internal fixation, extraction of the right iliac bone for bone grafting, and tracheotomy.

3. Surgical Procedure

The patient underwent surgery for cervical spine injuries under general anesthesia. A midline longitudinal incision of approximately 10cm was made, and the skin, subcutaneous tissue, and lumbar dorsal fascia were sequentially incised. The bilateral erector spinae muscles were then peeled off to expose the occipital bone and bilateral facet joints of C2-T1. Pedicle screws of appropriate length were inserted on the left side of C2, both sides of C3-T1, and the right side of C7. The connecting rod of appropriate length was pre-bent and installed. The spinous process of C5-6 was removed from its base. Utilizing preoperative image positioning, grooves were made at the junction of the lamina and lateral mass at the inner edge of the bilateral facet joints of C5-6 using a micro ball mill. The inner and outer layers of the lamina were then sequentially removed, along with the cortical bone and intervening cancellous bone. The bilateral laminae of C5-6 were removed to explore and address the hypertrophied ligamentum flavum and its adhesion to the dura mater at the corresponding segments. Special attention was given to protecting the dura mater and epidural veins. The ligamentum flavum behind the spinal canal was carefully removed, allowing for complete release of the C5-6 segment. During this process, the dura mater was observed to float and recover, while the spinal cord in the corresponding segment sustained injury [Figure 3-A]. A transverse link was then installed. Throughout the operation, the C-arm machine fluoroscopy confirmed the satisfactory internal fixation position and proper spinal alignment [Figure 4]. The nail tail was securely locked, and the transverse link was successfully installed. Finally, the incision was sutured layer by layer.

The patient was turned over to a supine position, with the neck kept in a neutral position. The neck and right iliac area were disinfected before surgery. An oblique incision was made on the right anterior superior iliac spine, and an appropriate amount of cancellous bone was taken for bone grafting. Make a longitudinal incision along the original incision in the neck to expose the C5-6 steel plate and screws, take out the C5-6 steel plates and screws, see the absence of the C5 vertebral body [Figure 3-B-C], implant a proper amount of cancellous bone, and suture the incision layer by layer.

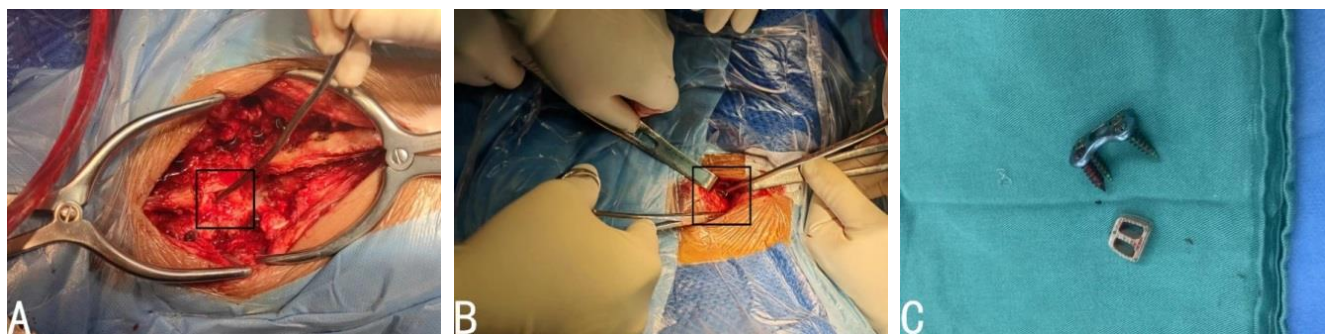


Figure 3. Intraoperative photographs of spinal cord injury (A) and anterior approaches removal of fixation (B-C).

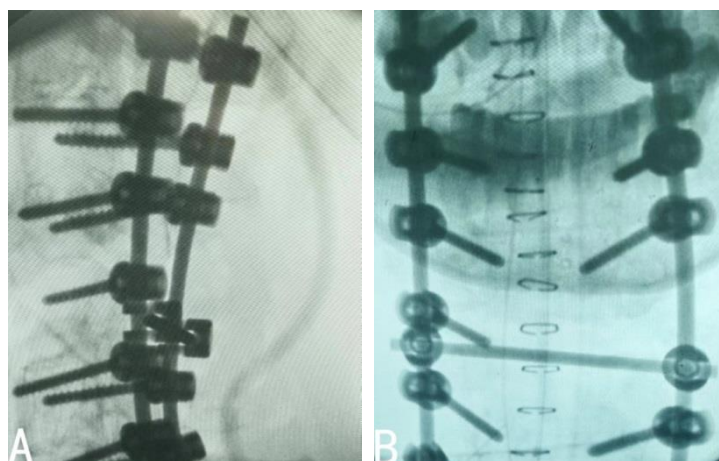


Figure 4. Intraoperative photographs of fixation with posterior approaches (A-B).

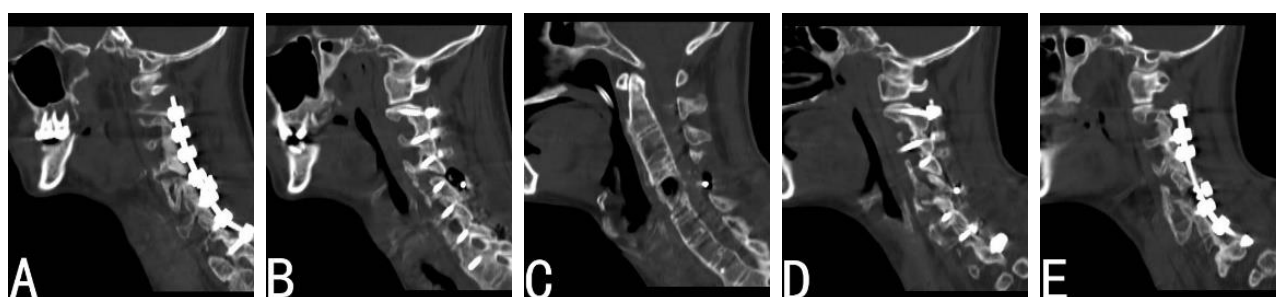


Figure 5. One-month postoperative lateral computerized tomography of the cervical spine.

One month after the operation, the patient underwent cervical spine internal fixation removal due to aggravation of wound infection and pneumonia. Five months after surgery, the patient's neurological status remained unchanged and he requested to be discharged due to financial reasons.

4. Discussion

Cervical spine fractures are more common in patients with ankylosing spondylitis. The main cause of these fractures in patients with ankylosing spondylitis is changes in the biomechanics of the spine, which make it unable to withstand normal stress and strain. Even slight external forces may cause fractures. The lower cervical spine (C5-7) is the most commonly injured part of the spine, and patients with ankylosing spondylitis are more likely to experience spinal cord injury and have a higher mortality rate. In our patient's case, they suffered a primary spinal fracture in the cervical region (C5-C6) as a result of a high-energy impact. Cervical spine fractures in patients with ankylosing spondylitis are considered unstable fractures and generally require surgical treatment. The treatment methods mainly include anterior surgery, posterior surgery, or a combination of both. The choice of surgical method is based on the individual patient's fracture characteristics.

Cervical spine fractures are more common in patients with

ankylosing spondylitis [6]. The main cause of these fractures in patients with ankylosing spondylitis is changes in the biomechanics of the spine, which make it unable to withstand normal stress and strain. Even slight external forces may cause fractures [2]. The lower cervical spine (C5-7) is the most commonly injured part of the spine, and patients with ankylosing spondylitis are more likely to experience spinal cord injury and have a higher mortality rate [6]. In our patient's case, they suffered a primary spinal fracture in the cervical region (C5-C6) as a result of a high-energy impact. Cervical spine fractures in patients with ankylosing spondylitis are considered unstable fractures and generally require surgical treatment. The treatment methods mainly include anterior surgery, posterior surgery, or a combination of both. The choice of surgical method is based on the individual patient's fracture characteristics [7, 8].

Anterior surgery is a suitable option for fractures of the upper cervical spine (C1-2) and lower cervical spine as it allows for direct decompression, reduction, and internal fixation with a low complication rate. In the case of this patient, the initial surgery performed at the local hospital involved anterior cervical intervertebral bone graft fusion and plate and screw internal fixation (C5/6) due to spinal cord compression and an obvious unstable fracture. However, it appears that the initial surgery did not adequately consider the need for strong stability, and as a result, the structural integrity of the vertebral body was seriously damaged. Therefore, posterior sur-

gery was not combined with the initial procedure [9]. According to Dvorak et al, it is not feasible to exclusively rely on anterior surgery for the treatment of unstable cervical spine fractures [10]. Vaidya's study findings indicate that anterior surgery yields diminished neurologic improvement [11]. Improper use of the internal fixation technique can result in adverse effects, including detachment of the internal fixation and displacement of the cervical spine. This can further worsen the patient's spinal cord injury. Additionally, it may also impact the trachea, as ankylosing spondylitis is often associated with pulmonary complications. This can potentially lead to a severe progression of pneumonia and further complicate the patient's condition [12]. The review of the patient's cervical spine by the doctor after the initial operation at the local hospital revealed that the anterior internal fixation had become detached. The detachment of the internal fixation can worsen the spinal cord injury and result in a poor prognosis.

This patient experienced a comminuted C5-6 fracture and spinal cord injury as a result of a high-energy impact. The initial procedure involved anterior intervertebral bone graft fusion and internal fixation using plates and screws (neck 5/6). However, it was discovered that the internal fixation became detached after the surgery. This resulted in displacement of the fractured end and worsened local spinal canal stenosis compared to pre-surgery. Multiple bone fragments and callus growth were observed around the fracture site. Although the postoperative complication rate for anterior surgery is relatively low, the failure rate of internal fixation is higher, often necessitating revision surgery [13, 14].

Reasons for revision surgery after cervical spine internal fixation: 1) The instability of the internal fixation segment and subsequent loosening of the cage resulted in vertebral body instability, which was the primary cause for revision surgery in this patient. 2) The low fusion rate of the bone graft and the relatively low success rate of the anterior surgical implant were also contributing factors [15]. 3) Inadequate decompression during the initial operation, as well as the possibility of postoperative or new lesions causing further compression of the spinal cord, are additional reasons for revision surgery. The main challenge with revision surgery after internal fixation of cervical spine fractures is the presence of a large bone defect after removing the cage. In this particular patient, the C5 vertebral body was absent during the operation. To facilitate faster growth and bone fusion, an appropriate amount of cancellous bone grafting needs to be taken from the patient's own body. Although the second operation resolved the issues of internal fixation loss and cervical spinal cord compression, it also introduced greater trauma and risks to the patient due to the irreversible spinal cord injury and the complications of long-term bed rest. Unfortunately, these interventions did not improve the patient's neurological function.

Posterior surgery is a surgical procedure that can directly address fracture fragments and other tissues in the spinal canal. This procedure effectively reduces pressure on the cervical

spinal cord and, additionally, provides improved stability for long segments [16]. The patient underwent a revision surgery using a posterior approach, which enabled complete decompression, reduction, and internal fixation through laminectomy and pedicle screws. In cases of cervical spine injuries in patients with ankylosing spondylitis, the combined anterior and posterior approach is the most preferred method for surgical treatment [17-19]. Liu et al. typically employ a comprehensive approach to revise and restore the firm stability of the cervical spine [20]. In this case, the patient had a missing C5 vertebral body. To prevent worsening the spinal cord injury, no additional treatment was administered after autologous cancellous bone implantation. Consequently, the patient underwent posterior surgical decompression, reduction, and internal fixation.

5. Conclusions

This patient, diagnosed with AS, experienced a cervical spine fracture and spinal cord injury as a result of a high-energy impact injury. Unfortunately, the internal fixation became dislodged following the initial surgery, exacerbating the patient's condition and leading to the development of pneumonia. It is crucial that we determine the appropriate procedure for the patient prior to the first surgical intervention.

Abbreviations

AS: Ankylosing Spondylitis

ICU: Intensive Care Unit

Conflicts of Interest

Authors have no potential competing interests or conflicts to report.

References

- [1] CALABRO J J, MALTZ B A. Ankylosing spondylitis [J]. *N Engl J Med*, 1970, 282(11): 606-10.
- [2] HUNTER T, DUBO H. Spinal fractures complicating ankylosing spondylitis [J]. *Ann Intern Med*, 1978, 88(4): 546-9.
- [3] GARG K, RAFIQ R, MISHRA S, et al. Cervical Spine Fracture with Extreme Dislocation in a Patient with Ankylosing Spondylitis: A Case Report and Systematic Review of the Literature [J]. *Neurol India*, 2022, 70(Supplement): S296-S301.
- [4] KANDREGULA S, BIRK H S, SAVARDEKAR A, et al. Spinal Fractures in Ankylosing Spondylitis: Patterns, Management, and Complications in the United States - Analysis of Latest Nationwide Inpatient Sample Data [J]. *Neurospine*, 2021, 18(4): 786-97.

- [5] VERLA T, XU D S, DAVIS M J, et al. Failure in Cervical Spinal Fusion and Current Management Modalities [J]. *Semin Plast Surg*, 2021, 35(1): 10-3.
- [6] LUKASIEWICZ A M, BOHL D D, VARTHI A G, et al. Spinal Fracture in Patients With Ankylosing Spondylitis: Cohort Definition, Distribution of Injuries, and Hospital Outcomes [J]. *Spine (Phila Pa 1976)*, 2016, 41(3): 191-6.
- [7] LONGO U G, LOPPINI M, PETRILLO S, et al. Management of cervical fractures in ankylosing spondylitis: anterior, posterior or combined approach? [J]. *Br Med Bull*, 2015, 115(1): 57-66.
- [8] MA J, WANG C, ZHOU X, et al. Surgical Therapy of Cervical Spine Fracture in Patients With Ankylosing Spondylitis [J]. *Medicine (Baltimore)*, 2015, 94(44): e1663.
- [9] TAGGARD D A, TRAYNELIS V C. Management of cervical spinal fractures in ankylosing spondylitis with posterior fixation [J]. *Spine (Phila Pa 1976)*, 2000, 25(16): 2035-9.
- [10] DVORAK M F, FISHER C G, FEHLINGS M G, et al. The surgical approach to subaxial cervical spine injuries: an evidence-based algorithm based on the SLIC classification system [J]. *Spine (Phila Pa 1976)*, 2007, 32(23): 2620-9.
- [11] GOVINDARAJAN V, BRYANT J P, PEREZ-ROMAN R J, et al. The role of an anterior approach in the treatment of ankylosing spondylitis-associated cervical fractures: a systematic review and meta-analysis [J]. *Neurosurg Focus*, 2021, 51(4): E9.
- [12] FELTELIUS N, HEDENSTROM H, HILLERDAL G, et al. Pulmonary involvement in ankylosing spondylitis [J]. *Ann Rheum Dis*, 1986, 45(9): 736-40.
- [13] COOPER P R, COHEN A, ROSIELLO A, et al. Posterior stabilization of cervical spine fractures and subluxations using plates and screws [J]. *Neurosurgery*, 1988, 23(3): 300-6.
- [14] EXNER G, BOTEL U, KLUGER P, et al. Treatment of fracture and complication of cervical spine with ankylosing spondylitis [J]. *Spinal Cord*, 1998, 36(6): 377-9.
- [15] EINSIEDEL T, SCHMELZ A, ARAND M, et al. Injuries of the cervical spine in patients with ankylosing spondylitis: experience at two trauma centers [J]. *J Neurosurg Spine*, 2006, 5(1): 33-45.
- [16] CORNEFJORD M, ALEMANY M, OLERUD C. Posterior fixation of subaxial cervical spine fractures in patients with ankylosing spondylitis [J]. *Eur Spine J*, 2005, 14(4): 401-8.
- [17] DUHEM-TONNELLE V, DUHEM R, ALLAOUI M, et al. [Fracture luxation of the cervical spine in patients with ankylosing spondylitis: six cases] [J]. *Neurochirurgie*, 2008, 54(1): 46-52.
- [18] SHETTY A P, MURUGAN C, KARUPPANNAN S, SUDHAKARAN S V A, et al. Surgical Approach to Cervical Fractures in Ankylosing Spondylitis Patients: Rationale and Surgical Strategy [J]. *World Neurosurg*, 2023, 173: e321-e8.
- [19] WERNER B C, SAMARTZIS D, SHEN F H. Spinal Fractures in Patients With Ankylosing Spondylitis: Etiology, Diagnosis, and Management [J]. *J Am Acad Orthop Surg*, 2016, 24(4): 241-9.
- [20] LIU B, YANG Z, JI H, et al. A Novel Classification of Cervical Spine Trauma in Ankylosing Spondylitis and Corresponding Surgical Outcomes [J]. *Orthop Surg*, 2023, 15(6): 1590-8.