

Research Article

Abdominal CT Scan Role out of Fatty Liver Disease: A Study in a Selected Hospital

Mohammad Salehin Abedin^{*}, Mohammad Mojibur Rahman, Sohel Rana Sumon, Abdur Rab Akanda, Marzuk Ahamed, Mohammad Motiur Rahman, Mohammad Ripon Sikder

Department of Public Health and Life Science, University of South Asia, Dhaka, Bangladesh

Abstract

Introduction: Fatty liver is a hepatic manifestation that can occur as a result of many medical problems and the use of certain drugs. The global prevalence of fatty liver is on the rise due to the escalating obesity epidemic. CT scans have proven to be useful in noninvasively identifying the presence and determining the degree of liver fat. The aim of this study was to determine the efficacy of CT scan in the diagnosis of non-alcoholic fatty liver disease in individuals. **Purpose:** This study aimed to determine the effectiveness of CT scan in identifying non-alcoholic fatty liver disease in individuals. **Methodology:** The research was carried out in the Radiology and Imaging department of IbnSina Hospital in Dhaka, Bangladesh, spanning from January 2023 to June 2023. The study was conducted using a cross-sectional prospective design. This study encompassed a cohort of 300 individuals, all of whom were above the age of 18 and sought medical attention at the hospital for an abdominal CT scan. These individuals were suspected to have non-alcoholic fatty liver disease. The hepatic fat level in the patients was assessed using a typical CT scan methodology. The acquired data was analyzed using the Statistical Package for Social Sciences (SPSS) software, especially version 23.0. The study gained ethical clearance from the Ethics Committee of the School of Public Health & Life Science at the University of South Asia in Dhaka, Bangladesh. **Findings:** The study included a cumulative total of 300 individuals who were suspected to have the condition. According to age distribution, the maximum 203 (67.66%) of the patients were above 52 years and minimum 3(1%) were between (18-22) years, and followed by 44 (14.66%) (43-52) years, 36(12%), (33-42) years and 14(4.66%) (22-32) years. The majority of the patients were male 160(53.33%) and 140(46.66%) were female. Distribution by clinical presentation, the patients were suffering from Abdominal pain, Nausea-50(16.66%) Abdominal pain, Vomiting-39(13%), Follow Up-60(20%), U. Abdominal pain-91(30.33%) U. Abdominal pain, Jaundice-53(17.66%) and U. Abdominal pain, Nausea-7(2.33%). According to the evaluation of CT scan, 189(63%) patients had fatty liver and 111(37%) patients had normal liver. **Conclusion:** This study investigated 63 % of the study patients were suffering from fatty liver diseases. Therefore, early detection may help them to medicate in a standard approach and to remove health effect in their day to day life.

Keywords

Abdominal, CT Scan, Role Out, Diagnosis, Fatty Liver, Non-Alcoholic, Selected, Hospital

^{*}Corresponding author: salehinabedin@gmail.com (Mohammad Salehin Abedin)

Received: 2 November 2023; **Accepted:** 7 December 2023; **Published:** 12 April 2024



Copyright: © The Author(s), 2023. Published by Science Publishing Group. This is an **Open Access** article, distributed under the terms of the Creative Commons Attribution 4.0 License (<http://creativecommons.org/licenses/by/4.0/>), which permits unrestricted use, distribution and reproduction in any medium, provided the original work is properly cited.

1. Introduction

Fatty liver is a sign of certain medical diseases and the usage of certain drugs [1]. The increasing worldwide obesity crisis has led to a surge in the identification of fatty liver disease [2]. Non-alcoholic fatty liver disease (NAFLD) is a distinct condition characterized by the accumulation of triglyceride droplets in the liver cells, in the absence of significant alcohol intake. NAFLD encompasses various clinical disorders, such as the straightforward buildup of fat in the liver, which has the potential to progress into Steatohepatitis. Each of these occurrences entails the accumulation of adipose tissue in the liver [3, 4]. Steatosis alone, which is the main feature of non-alcoholic fatty liver disease (NAFLD), does not have any clinical importance. Nevertheless, its therapeutic importance is enhanced by its correlation with cardiovascular disease [5, 6]. Non-alcoholic Steatohepatitis (NASH) is a specific form of NAFLD that is identified by the presence of swollen and dead liver cells, with or without the development of Mallory's hyaline and fibrosis, as determined by examining tissue samples under a microscope. NASH has the potential hazard of advancing into chronic hepatic illness and cirrhosis. Identifying Non-Alcoholic Fatty Liver Disease (NAFLD) is linked to a reduced lifespan compared to what would be anticipated for a standard group of patients with similar age and gender. bNAFLD has been demonstrated to have a correlation with insulin resistance and is regarded as a constituent of the metabolic syndrome [7-9]. Ongoing research is researching the relationship between non-alcoholic fatty liver disease (NAFLD) and inflammatory indicators as well as subclinical atherosclerosis. This research aims to explore the connections of NAFLD beyond its impact on the liver. Group-based studies have shown a diverse range of prevalence rates for non-alcoholic fatty liver disease (NAFLD), varying from 3% to 46%. The discrepancies can be ascribed to the diverse diagnostic techniques utilized and the characteristics of the patient cohort. Imaging techniques include computed tomography (CT), magnetic resonance imaging, and ultrasonography might exhibit unique characteristics of fatty liver. Nevertheless, a liver biopsy is required for establishing a conclusive diagnosis [10]. The liver biopsy reveals the existence of steatosis, as well as any accompanying inflammation and fibrosis. This operation is invasive and can lead to consequences, such as hospitalization and substantial bleeding [11]. The test may not be appropriate for identifying the existence of a highly prevalent illness in a population that does not show any symptoms. CT scans have proven to be useful in noninvasively identifying the presence and determining the degree of liver fat. The Hounsfield Unit (HU) attenuation of the liver on CT images generally surpasses that of the spleen. Conversely, if this ratio is reversed, it can suggest the existence of hepatic steatosis and assist in the process of diagnosis. A liver-to-spleen ratio (L/S) below 1.0 can accurately indicate the presence of liver fat [12]. Studies have shown that when the attenuation of the liver measured in

Hounsfield Units (HU) falls below 40 HU, it reliably indicates a liver fat content over 30%. This study examines the occurrence and dependability of measuring hepatic steatosis using non-enhanced computed tomography scans in a sizable and thoroughly validated population-based group of asymptomatic adults. The study utilizes recognized criteria, previously disseminated, for assessing hepatic steatosis. We will also evaluate the frequently mentioned criteria (L/S ratio and liver HU attenuation) that are routinely used in the literature to diagnose NAFLD [13-15]. However, the aim of this study was to determine the outcomes of CT scans conducted on patients who displayed clinical symptoms, such as stomach discomfort, and other issues as recommended by professional physicians.

2. Objectives

General Objective:

To determine the role out of CT scan in the diagnosis of fatty liver disease of non-alcoholic adults

Specific Objectives:

- 1) To evaluate Fatty Liver in CT Scan of Abdomen
- 2) To find out CT Number (HU) of Liver

3. Methodology

This was a cross-sectional prospective study carried out at the department of Radiology and Imaging in IbnSina Hospital, Dhaka, Bangladesh during January, 2023 to June, 2023. The aims, benefits, and possible risks of this study were conveyed to the participants or their caregivers in the local language. Obtained written informed permission from the study participants or their caretakers. This analysis included a cohort of 300 participants, all of whom were 18 years of age or older who sought an abdominal CT scan at the hospital. This study utilized a planned random sampling technique. The hepatic and splenic attenuation were evaluated utilizing non-contrast CT images. The assessment was performed using a tube voltage of 120 kilovolts peak (kVp), a tube current of 50 milliamperes (mAs), and a tube rotation duration of 750 milliseconds (ms). The patient was lying flat on their back, and five sequential cross-sectional images, each with a thickness of 3 mm, were acquired near the approximate center of the liver picture on the tomogram. We selected one image at random from each of the five consecutive sections to assess the deterioration of the liver and spleen in each patient. The liver was divided into five discrete regions of interest (ROIs), with particular attention given to the arteries, bile ducts, calcifications, and artifacts. Furthermore, four separate regions of interest (ROIs) were discovered within the spleen. The estimate of the average decrease in the size of the liver and spleen excludes the extreme values at both ends of the spectrum. Consequently, the mean size was ascertained by em-

playing three measurements of the liver and two measures of the spleen. The liver attenuation indices (LAIs) were determined by computing the average attenuation values of the liver and spleen using the available data. The LAIs comprised three measurements: (1) CTLP refers to the average reduction in intensity of the liver tissue; (2) LS ratio is the proportion of the average liver intensity to the average spleen intensity; and (3) LS dif is the disparity between the average liver intensity and the average spleen intensity. 5. The patients were categorized into two groups according on their LS dif. The liver-spleen density difference (LS dif) is a commonly employed metric for assessing the extent of fatty liver disease by computed tomography (CT) imaging. Subjects with an LS divergence greater than 5 were categorized as normal. Patients exhibiting a liver stiffness differential (LS dif) below 5 were diagnosed with fatty liver. Data was gathered using a pre-designed Case Record Form (CRF). The gathered data underwent a process of cleansing, editing, and inputting into a computer system for the purpose of analysis. The acquired data was analyzed utilizing the Statistical Package for Social Sciences (SPSS) software, especially version 23.0. A statistical analysis was performed to draw conclusions, and the results were presented in tables and charts, illustrating the frequency and percentage. The study obtained ethical approval from the Ethics Committee of the School of Public Health & Life Science at the University of South Asia in Dhaka, Bangladesh. The director and registrar of IbnSina Hospital in Dhaka, Bangladesh were also formally consulted for authorization. The following were the inclusion and exclusion criteria for this study:

3.1. Inclusion Criteria

- 1) Suspected cases with pain in abdomen
- 2) Come to conduct CT scan of abdomen
- 3) Aged above 18 years
- 4) Willing to participate in the study
- 5) Non-alcoholic

3.2. Exclusion Criteria

- 1) Aged below 18 years
- 2) Unwilling to participate in the study.
- 3) Non referred to CT scan of abdomen
- 4) Alcoholic

4. Results

Table 1. Age distribution of the study patients (n=300).

Age in years	Frequency	Percentage
18- 22	3	1

Age in years	Frequency	Percentage
22-32	14	4.66
33-42	36	12
43-52	44	14.66
>52	203	67.66
Total	300	100

Table 1 shows that maximum 203 (67.66%) of the patients were above 52 years and minimum 3(1%) were between (18-22) years, and followed by 44 (14.66%) (43-52) years, 36(12%), (33-42) years and 14(4.66%) (22-32) years.

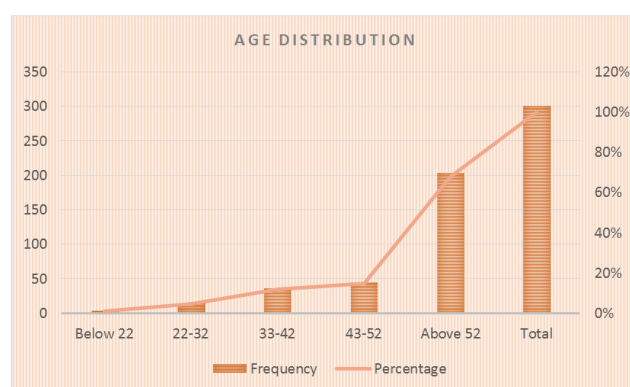


Figure 1. Shows the age distribution of the study patients (n=300).

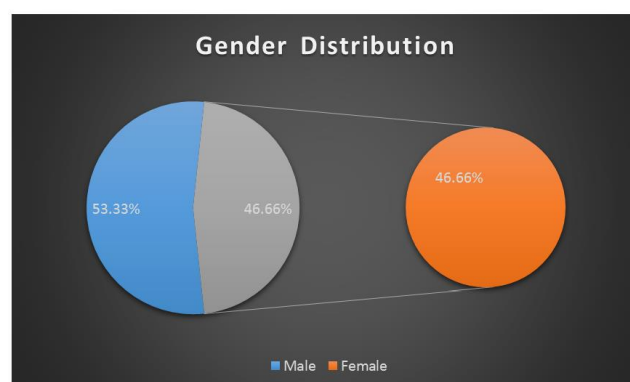


Figure 2. Shows the sex distribution of the study patients (n=300).

Table 2. Clinical characteristics of the study patients (n=300).

Clinical Presentations	Frequency	Percentage
Abdominal pain, Nausea	50	16.66
Abdominal pain, Vomiting	39	13
Follow Up	60	20
U. Abdominal pain	91	30.33

Clinical Presentations	Frequency	Percentage
U. Abdominal pain, Jaundice	53	17.66
U. Abdominal pain, Nausea	7	2.33
Total	300	100

Table 2 shows the clinical characteristics of the study patients. The patients were suffering from Abdominal pain, Nausea-50(16.66%) Abdominal pain, Vomiting- 39(13%), Follow Up-60(20%), U. Abdominal pain-91(30.33%) U. Abdominal pain, Jaundice-53(17.66%) and U. Abdominal pain, Nausea-7(2.33%)

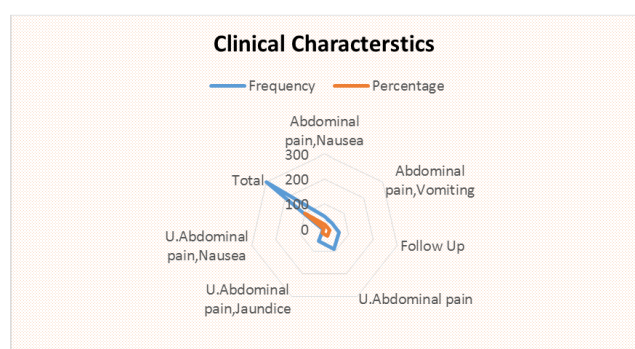


Figure 3. Shows the clinical characteristics of the study patients (n=300).

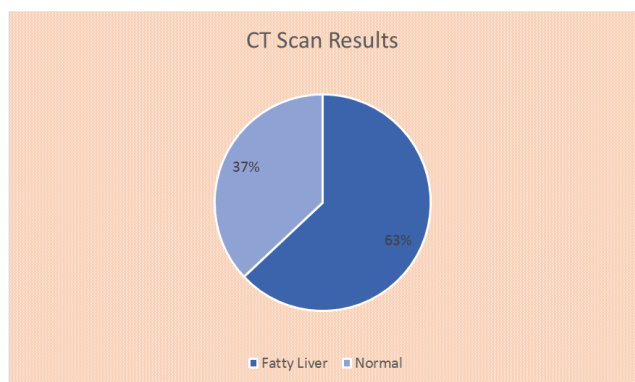


Figure 4. Shows the CT scan results of the study patients (n=300).

Table 3. Clinical characteristics of the study patients (n=300).

Results of CT Scan	Frequency	Percentage
Fatty Liver	189	63
Normal	111	37
Total	300	100

Table 3 shows the clinical characteristics of the study patients. Among the study patients, 189(63%) were counted fatty liver in CT scan test results and the rest 111(37%) were counted Normal study in liver.

5. Discussion

The assessment of hepatic steatosis using CT scans depends on the measurement of the attenuation value of liver tissue, which is expressed in Hounsfield units (HU). The attenuation value of fat, often about -100 HU, is far lower than that of soft tissue, which typically ranges from 30 to 40 HU. The attenuation of liver parenchyma decreases as hepatic steatosis advances. The user's input is a string containing the characters "[16]". While some studies suggest that contrast enhanced portal venous CT images can be used to evaluate hepatic steatosis with similar diagnostic accuracy as unenhanced CT scans, it is more beneficial to use unenhanced CT scans for this purpose. Differences in injection approach and scan delay can have an impact on the attenuation value of the liver parenchyma after contrast injection. There is a significant association between the estimated absolute attenuation value of liver tissue on unenhanced CT scan and the degree of hepatic steatosis shown on histological inspection. However, the precise attenuation value of liver tissue on CT scans without contrast can be affected by other factors, including the specific CT scanner and the reconstruction technique employed. Therefore, the direct assessment of the attenuation value of liver tissue on unenhanced CT scans is not widely used to evaluate hepatic steatosis. The disparity in attenuation between the liver and spleen (CTL-S) on unenhanced CT scans is frequently employed as a quantitative measure to evaluate hepatic steatosis. This method circumvents potential inaccuracies in quantifying attenuation values due to discrepancies in CT scanners and reconstruction methods, by utilizing the spleen's attenuation as an internal reference. Normally, the attenuation value of the liver tissue on an unenhanced CT scan is slightly higher than that of the spleen. As hepatic steatosis progresses, the attenuation value of liver tissue decreases, leading to a decrease in CTL-S. CTL-S has exhibited a comparatively elevated degree of precision in detecting mild to severe hepatic steatosis. When the threshold value of CTL-S was set at -9, the reported specificity and sensitivity for identifying moderate to severe hepatic steatosis were 100% and 82% respectively. The threshold CTL-S value for identifying moderate to severe hepatic steatosis has exhibited variation in different research, typically falling within the range of around -10 [17-19]. Nevertheless, CTL-S technology cannot be considered reliable for the detection of mild hepatic steatosis. The limited diagnostic precision of CT in identifying moderate hepatic steatosis, coupled with the utilization of ionizing radiation, represents a notable drawback. Various variables can affect the attenuation value of liver tissue on unenhanced CT scans, in addition to hepatic steatosis. The liver tissue shows a higher attenuation value on an unenhanced CT scan

because of the excessive accumulation of iron, which is commonly seen in cases of hemochromatosis or hemosiderosis. Administration of certain drugs, particularly amiodarone, which includes iodine and builds up in the liver, has been found to increase the attenuation measurement of liver tissue on a CT scan without the need for contrast [20]. Dual energy computed tomography (DECT) uses two distinct energy levels to distinguish various chemical compositions, such as adipose tissue, within biological structures. Hence, DECT has the capacity to provide enhanced diagnostic precision in identifying hepatic steatosis as compared to conventional single energy CT. However, a research conducted on animals using DECT showed similar effectiveness in diagnosing hepatic steatosis compared to single energy CT. Nevertheless, the investigation failed to furnish evidence substantiating the theoretical advantage of DECT in assessing hepatic steatosis. Yes, a study conducted on humans using Dual-Energy Computed Tomography (DECT) to evaluate hepatic steatosis produced similar results. Given the limited accuracy of CT scans in identifying moderate levels [21]. In light of the aforementioned literature and parameters, the current study recruited 300 adults (aged 18 and up) referred by the radiology and imaging specialists at IbnaSina Hospital in Dhaka, Bangladesh, to undergo CT scans of the abdomen in order to diagnose fatty liver disease in patients experiencing a variety of symptoms, including abdominal pain. This current study observed among the patients, the maximum 203 (67.66%) of the patients were above 52 years and minimum 3(1%) were between 18-22) years, and followed by 44 (14.66%) (43-52) years, 36(12%), (33-42) years and 14(4.66%) (22-32) years and the proportion of male 160(53.33%) and female 140(46.33%). To investigate, the clinical characteristics, this study observed the patients were suffering from Abdominal pain, Nausea-50(16.66%) Abdominal pain, Vomiting-39(13%), Follow Up-60(20%), U. Abdominal pain-91 (30.33%) U. Abdominal pain, Jaundice-53(17.66%) and U. Abdominal pain, Nausea-7(2.33%). Finally, this present study observed 189(63%) patients had fatty liver and the rest 111(37%) had normotensive liver. Almost similar observation was noted in some other studies [22-25].

6. Conclusion

This study investigated 63 % of the study patients were suffering from fatty liver diseases. Therefore, early detection may help them to medicate in a standard approach and to remove health effect in their day to day life.

7. Limitations of the Study

This was a single center study with a limited purposive sample size and short study duration. So, the findings of this study may not reflect the whole country.

8. Recommendations of the Study

A further study may be conducted with a large statistical calculated sample size in multi-centers across the country to justify the epidemiology of fatty liver diseases in Bangladesh.

Ethical Approval

The ethical clearance of this study was obtained from the Ethics Committee of School of Public Health & Life Science, University of South Asia, and Dhaka, Bangladesh.

Conflicts of Interest

The authors declare no conflicts of interest.

References

- [1] Fauci AS, B E, Kasper DL, et al., editors. Harrison's Principles of Internal Medicine. 17. McGraw-Hill: Companies Inc.; 2008. Nonalcoholic Fatty Liver Disease; pp. 1982–83. [Google Scholar]
- [2] Wanless IR, Lentz JS. Fatty liver hepatitis (steatohepatitis) and obesity: an autopsy study with analysis of risk factors. *Hepatology*. 1990; 12(5): 1106-10 [PubMed] [Google Scholar].
- [3] Adler M, Schaffner F. Fatty liver hepatitis and cirrhosis in obese patients. *Am J Med*. 1979; 67(5): 811–6. [PubMed] [Google Scholar]
- [4] Nasrallah SM, Wills CE, Jr, Galambos JT. Hepatic morphology in obesity. *Dig Dis Sci*. 1981; 26(4): 325–7.
- [5] Clain DJ, Lefkowitz JH. Fatty liver disease in morbid obesity. *Gastroenterol Clin North Am*. 1987; 16(2): 239–52.
- [6] Dixon JB, Bhathal PS, O'Brien PE. Nonalcoholic fatty liver disease: predictors of nonalcoholic steatohepatitis and liver fibrosis in the severely obese. *Gastroenterology*. 2001; 121(1): 91–100. [PubMed] [Google Scholar]
- [7] Adams LA, Lymp JF, St Sauver J, et al. The natural history of nonalcoholic fatty liver disease: a population-based cohort study. *Gastroenterology*. 2005; 129(1): 113–21. [PubMed] [Google Scholar]
- [8] Ekstedt M, Franzen LE, Mathiesen UL, et al. Long-term follow-up of patients with NAFLD and elevated liver enzymes. *Hepatology*. 2006; 44(4): 865–73. [PubMed] [Google Scholar]
- [9] Younossi ZM, Gramlich T, Liu YC, et al. Nonalcoholic fatty liver disease: assessment of variability in pathologic interpretations. *Mod Pathol*. 1998; 11(6): 560–5. [PubMed] [Google Scholar]
- [10] Hamaguchi M, Kojima T, Takeda N, et al. Nonalcoholic fatty liver disease is a novel predictor of cardiovascular disease. *World J Gastroenterol*. 2007; 13(10): 1579–84. [PMC free article] [PubMed] [Google Scholar]

- [11] Targher G, Day CP, Bonora E. Risk of cardiovascular disease in patients with nonalcoholic fatty liver disease. *N Engl J Med*. 2010; 363(14): 1341–50. [PubMed] [Google Scholar]
- [12] Matteoni CA, Younossi ZM, Gramlich T, Boparai N, Liu YC, McCullough AJ. Nonalcoholic fatty liver disease: a spectrum of clinical and pathological severity. *Gastroenterology*. 1999; 116(6): 1413–9. [PubMed] [Google Scholar]
- [13] Powell EE, Cooksley WG, Hanson R, Searle J, Halliday JW, Powell LW. The natural history of nonalcoholic steatohepatitis: a follow-up study of forty-two patients for up to 21 years. *Hepatology*. 1990; 11(1): 74–80. [PubMed] [Google Scholar]
- [14] Goto T, Onuma T, Takebe K, Kral JG. The influence of fatty liver on insulin clearance and insulin resistance in non-diabetic Japanese subjects. *Int J Obes Relat Metab Disord*. 1995; 19(12): 841–5. [PubMed] [Google Scholar]
- [15] Zelber-Sagi S, Nitzan-Kaluski D, Halpern Z, Oren R. Prevalence of primary non- alcoholic fatty liver disease in a population-based study and its association with biochemical and anthropometric measures. *Liver Int*. 2006; 26(7): 856–63. [PubMed] [Google Scholar]
- [16] Shores NJ, Link K, Fernandez A, et al. Non-contrasted Computed Tomography for the Accurate Measurement of Liver Steatosis in Obese Patients. *Digestive Diseases and Sciences*. 2011; 56: 2145-2151. PMid: 21318585 PMCID: PMC3112485. <https://doi.org/10.1007/s10620-011-1602-5>
- [17] Jang S, Lee CH, Choi KM, et al. Correlation of fatty liver and abdominal fat distribution using a simple fat computed tomography protocol. *World Journal of Gastroenterology: WJG*. 2011; 17: 3335-3341. PMid: 21876622 PMCID: PMC3160538. <https://doi.org/10.3748/wjg.v17.i28.3335>
- [18] Wells MM, Li Z, Addeman B, et al. Computed Tomography Measurement of Hepatic Steatosis: Prevalence of Hepatic Steatosis in a Canadian Population. *Canadian Journal of Gastroenterology & Hepatology*. 2016; 2016: 4930987. PMid: 27446844 PMCID: PMC4904663. <https://doi.org/10.1155/2016/4930987>
- [19] Attar BM, Van Thiel DH. Current concepts and management approaches in nonalcoholic fatty liver disease. *ScientificWorld Journal*. 2013; 2013: 481893.
- [20] Zeb I, Li D, Nasir K, Katz R, Larijani VN, Budoff MJ. Computed tomography scans in the evaluation of fatty liver disease in a population based study: the multi-ethnic study of atherosclerosis. *Acad Radiol*. 2012 Jul; 19(7): 811-8. Epub 2012 Apr 21. PMID: 22521729; PMCID: PMC3377794. <https://doi.org/10.1016/j.acra.2012.02.022>
- [21] Lee SS, Park SH, Kim HJ, et al. Non-invasive assessment of hepatic steatosis: prospective comparison of the accuracy of imaging examinations. *J Hepatol*. 2010; 52(4): 579–85. [PubMed] [Google Scholar].
- [22] Davidson LE, Kuk JL, Church TS, Ross R. Protocol for measurement of liver fat by computed tomography. *J Appl Physiol*. 2006; 100(3): 864–8. [PubMed] [Google Scholar].
- [23] Longo R, Ricci C, Masutti F, et al. Fatty infiltration of the liver. Quantification by 1H localized magnetic resonance spectroscopy and comparison with computed tomography. *Invest Radiol*. 1993; 28(4): 297–302. [PubMed] [Google Scholar].
- [24] Nomura H, Kashiwagi S, Hayashi J, Kajiyama W, Tani S, Goto M. Prevalence of fatty liver in a general population of Okinawa, Japan. *Jpn J Med*. 1988; 27(2): 142–9. [PubMed] [Google Scholar]
- [25] Kawata R, Sakata K, Kunieda T, Saji S, Doi H, Nozawa Y. Quantitative evaluation of fatty liver by computed tomography in rabbits. *AJR Am J Roentgenol*. 1984; 142(4): 741–6. [PubMed] [Google Scholar]