



Case Report

## A Secondary Urothelial Carcinoma of the Penis Diagnosed on a Surgical Specimen: A Case Report

**Faye Samba Thiapato<sup>1,\*</sup> , Diallo Thierno Amadou<sup>2</sup>, Thiam Jafar Abou Talib<sup>3</sup>,  
Niang Rokhaya Désiré<sup>4</sup>, Kikalulu Kiambote Hamidou<sup>1</sup>, Dembele Mamadou<sup>1</sup>,  
Jalloh Mohamed<sup>2,5</sup> , Kane Racine<sup>1</sup>, Niang Lamine<sup>2,5</sup>**

<sup>1</sup>Urology Department, Principal Main Hospital of Dakar, Dakar, Senegal

<sup>2</sup>Urology Department, Idrissa POUYE General Hospital, Dakar, Senegal

<sup>3</sup>Oncological Surgery Department, Dalal Jam Hospital, Dakar, Senegal

<sup>4</sup>Medical Oncology Department, Hôpital Général Idrissa POUYE, Dakar, Senegal

<sup>5</sup>Department of Surgery and Surgical Specialties, Faculty of Medicine, Pharmacy and Odontology of Cheikh Anta Diop University of Dakar, Dakar, Senegal

### Abstract

**Aim:** Penile cancer is one of the rarest urogenital cancers. Penile metastases after cystectomy are possible and seem to be associated with the existence of an extensive tumor on the surgical specimen. **Case Presentation:** We report here the case of old man 78 years old, with a history of Radical Cysto-Prostatectomy with Bricker type urinary diversion, indicated for a pT3N0M0R0 infiltrating urothelial carcinoma of the bladder. He had consulted 7 years post surgery for an indurated lesion of the penis with urethrorrhagia. On examination, he presented an ulcerative-necrotic lesion under the left lateral coronal area of the penis, a diffuse induration of corporal bodies from the glans to the bulb, bilateral inguinal macro lymphadenopathies. Magnetic Resonance Imaging of the penis suggested a tumor extending over the entire penis, infiltrating the corpora cavernosa and spongiosa, with invasion of the albuginea, adjacent fat and skin. In view of this picture, a total penectomy with emasculation was performed. The histology of the surgical specimen showed a poorly differentiated urothelial carcinoma with an immunohistochemical study in favor of a primary urothelial origin (GATA3+). The tumor infiltrated both corpora cavernosa and the urethra with positive margins of resection. The right inguinal lymph node dissection showed one metastatic node out of two. The left inguinal lymph node dissection showed one metastatic lymph node out of six with capsular rupture. Thoracic-abdominopelvic CT Scan showed a right inguinal adenopathy with no other lesions suggestive of secondary localization. The diagnosis of secondary urothelial carcinoma of the penis classified as pT4N2M0R1 was made and the patient underwent chemotherapy on tumor board meeting. **Conclusion:** Secondary cancers of the penis, although rare, can occur years after radical treatment of the primary tumor. Immuno-histochemistry was essential to differentiate from primary squamous cell carcinoma in our case.

### Keywords

Secondary Malignancy, Penile Cancer, Bladder Cancer, Immuno-Histochemistry

\*Corresponding author: thiapatomaleme@gmail.com (Faye Samba Thiapato)

**Received:** 9 March 2024; **Accepted:** 1 April 2024; **Published:** 28 April 2024



## 1. Introduction

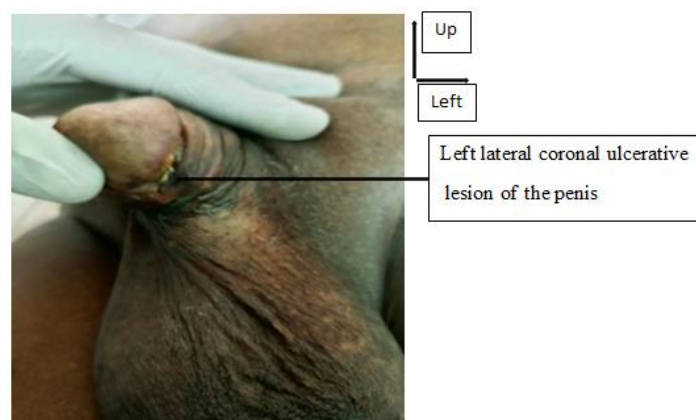
Penile cancer is one of the rarest urogenital cancers. In 2020, its incidence was estimated to 36,068/100 000 inhabitants cases worldwide and 2,064 cases/100 000 inhabitants in Africa [1]. In Senegal, the data remain underestimated due to the absence of a functional cancer registry. Pathologically, squamous cell carcinoma is the most frequent accounting for 95% of cases and secondary penile cancers are rare [2]. Some authors report that the appearance of penile metastases after cystectomy seems to be readily associated with the existence of an extensive tumor on the surgical specimen [3]. Immuno-histochemistry is essential for histological confirmation but remains difficult to access in our regions, thus delaying the results and impacting the quality of the management. Treatment may require major genital surgery, in particular total penectomy associated or not with castration, which has considerable social consequences and has been reported by some authors [4]. Delayed diagnosis is still a reality in our context, as is the case for most urogenital cancers such as penile cancer, which often requires palliative treatment, especially chemotherapy.

We report a case of secondary cancer of the penis after

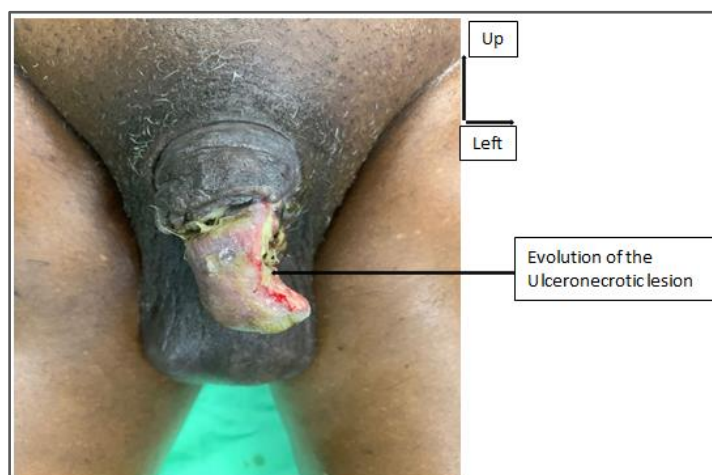
radical cystoprostatectomy for infiltrating urothelial bladder carcinoma.

## 2. Observation

It is the case of a 78-year-old male patient, with a history of high blood pressure and a cardiomyopathy under beta-blocker. He underwent a Radical Cysto-Prostatectomy with Bricker urinary diversion in 2015 to treat an infiltrating urothelial carcinoma of the bladder which was classified pT3N0M0R0. Postoperative course was simple apart from erectile dysfunction secondary to surgery. He consulted 7 years after surgery for an indurated lesion of the penis with urethrorrhagia. On examination he presented with good general condition (ECOG1), retraction of the penis with a small ulcerative-necrotic lesion under the left lateral coronal area (Figure 1), diffuse induration of the erectile bodies from the glans to the bulb and bilateral inguinal lymphadenopathies mobile on both planes.



**Figure 1.** Clinical finding in a patient presenting penile cancer from Urothelial carcinoma of the bladder.

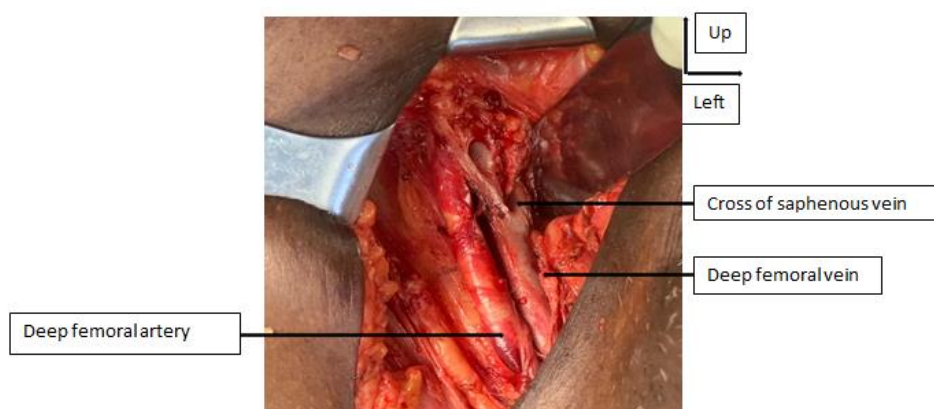

**Figure 2.** Clinical aspect of the penis preoperatively (after biopsy).

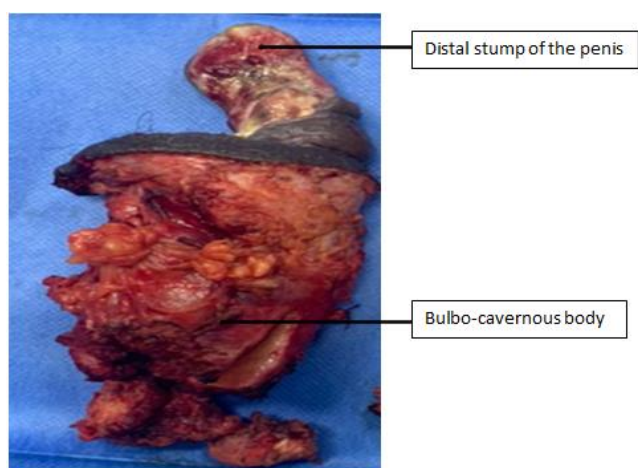
A left ileostomy was in place, draining clear urine. Magnetic Resonance Imaging (MRI) of the penis showed an aspect in favor of a malignant tumor extending all over the penis, infiltrating the cavernous and spongiosum, with invasion of the albuginea, the adjacent fat and the skin. A malignant tumor of the penis was evoked and a biopsy was performed. Pathological examination was suggestive of squamous cell carcinoma of the penis. Thoracic-abdominopelvic CT Scan showed a right inguinal lymphadenopathy with no other lesions suggestive of secondary localizations. The clinical evolution

was marked by a rapid extension of the lesion to all the glans with an important retraction of the corpora cavernosa at three weeks after the first consultation due to the biopsy (figure 2).

The indication of a total penectomy with emasculation and bilateral extended inguinal lymph node dissection was decided at the tumour board meeting. He underwent the surgery after psychological counselling and patient's informed consent. Figures 3 and 4 show the right inguinal lymph node dissection and the total penectomy specimen.



**Figure 3.** Intraoperative view of lymph node dissection on the right side.



**Figure 4.** Surgical specimen for total penectomy.

Pathology of the surgical specimen showed a poorly differentiated urothelial carcinoma with immunohistochemical signature of primary urothelial cancer (GATA3+) in agreement with the patient's history. The tumor infiltrated both corpora cavernosa and the urethra with positive margins of resection. Inguinal lymph node dissection showed one positive lymph node out of two on the right side and one positive lymph node out of six with capsular rupture. The diagnosis of

secondary urothelial carcinoma of the penis, classified as pT4N2M0R1 according to the International Union for the Control of Cancer (UICC) classification was made and the indication for adjuvant chemotherapy was decided on tumor board meeting.

### 3. Discussion

Malignant tumors of the penis are essentially constituted by squamous cell carcinoma with 95% of cases [2]. They are very rare before 55 years of age and most often affect men over 75 years of age [5], as in our patient. Studies report very few secondary cancers of the penis. In the majority of cases, the primary tumor was located in the urogenital tract [6] with a predominance of bladder cancer (30 to 35%) followed by prostate cancer (28 to 30%), kidney cancer (10%) and testicular cancer (5%) [7]. The occurrence of metastases in the corpora cavernosa after radical treatment of urothelial carcinoma of the bladder is variable and is estimated by several authors to be between 1 and 8%. These secondary localizations occur mostly within 18 months [8, 9]. Bordeau KP et al. reported a case of secondary urothelial carcinoma to the corpora cavernosa occurring 4 years after radical cysto prostatectomy [10]. In our patient, the delay between surgery and the diagnosis of the secondary location on the penis was 7 years. Confirmation of the diagnosis is made by pathology and the

collegial therapeutic decision is ideally taken at tumor board meeting. Total penectomy with emasculation was indicated for our patient and was not delayed by any tendency to refuse treatment as reported by several authors [11]. It's important to note that in our case, erectile dysfunction and Briker's ileostomy facilitated the decision making. Nevertheless, psychological support was provided before and after the surgery. The result of the pathological examination of the surgical specimen is decisive for further course of treatment. In our case, the pathology of the surgical specimen was in favor of a secondary urothelial carcinoma with a primary bladder origin (GATA 3 positive). This reflects the importance of the immunohistochemical study for diagnostic confirmation. Even though the initial penile biopsy had indicated squamous cell carcinoma, we believe that the examination of the surgical specimen is more valuable especially because of the immunohistochemical examination. This discrepancy may justify a re-reading of the biopsy. To our knowledge, this case of secondary urothelial carcinoma of the penis is the first case reported in our Sub-Saharan African setting. [4, 11-13]. Adjuvant chemotherapy is our complementary therapeutic option, even if it is questionable according to some recommendations [5]. The response to chemotherapy remains to be evaluated, but from a functional point of view, the surgical procedure performed will not have any consequences on the mictional status of our patient who already had a non-continuous urinary shunt and an irreversible erectile dysfunction.

## 4. Conclusion

Secondary cancers of the penis, although rare, can occur years after radical treatment of the primary tumor. The post-operative evaluation after radical cystoprostatectomy must take this into account in order to propose an adjuvant treatment as soon as possible. However, if cavernous invasion is found, suggesting urothelial carcinoma, a primary urethral location cannot be excluded. It is necessary to underline the important role of immunohistochemistry in this case and to promote its accessibility in our daily practice.

## Abbreviations

MRI: Magnetic Resonance Imaging  
 ECOG: Eastern Cooperative Oncology Group  
 CT Scan: Computerized Tomography (CT) Scan  
 UICC: International Union for the Control of Cancer  
 GATA3: GATA Binding Protein 3

## Author Contributions

**Faye Samba Thiapato:** Conceptualization, Writing final draft

**Diallo Thierno Amadou:** Writing - original draft

**Thiam Jafar Abou Talib:** Conceptualization

**Niang Rokhaya Désiré:** Conceptualization

**Kikalulu Kiambote Hamidou:** Writing – original draft

**Dembele Mamadou:** Writing – original draft

**Jalloh Mohamed:** Writing – review & editing

**Kane Racine:** Writing – review & editing

**Niang Lamine:** Writing – review & editing

## Ethical Approval

Our study is exempt from ethical approval by the ethics committee of the Principal Main Hospital of Dakar, and informed consent was obtained from the patient for scientific publication of the clinical case.

## Conflicts of Interest

The authors declare no conflicts of interest.

## References

- [1] GLOBOCAN. Estimated number of new cases, worldwide. International Agency for Research on Cancer 2020. <https://doi.org/10.3322/caac.21660>
- [2] LESOURD A. Anato-pathology of malignant penile tumours. *Prog Urol* 2005; 15 801-804.
- [3] MONDET F., MKAOUAR S., CHARTIER-KASTLER E, BITKER MO, DELCOURT A, RICHARD F. Cavernous metastases of bladder tumours after cystoprostatectomy. *Prog Urol* 2003; 13: 1330-1333.
- [4] SOW Y, THIAM A, FALL B, COULIBALI M, SARR A, DIAO B ·ET AL. Penile cancer in Senegal: clinical and therapeutic aspects. *Basic Clin. Androl.* 2012; 22: 102–107. <https://doi.org/10.1007/s12610-012-0176-1>
- [5] SAVOIE PH, MOREL-JOURNÉL N, MUREZ T, FERRETTI L, ROCHER L, FLECHON A. French ccAFU guidelines - update 2020-2022: penile cancer]. *Prog Urol.* 2020; 30(12S): S252-S279. [https://doi.org/10.1016/S1166-7087\(20\)30753-3](https://doi.org/10.1016/S1166-7087(20)30753-3)
- [6] CARDOSO GUIMARÃES G, RODRIGUES DE SOUZA R, PAIVA GADELHA GUIMARÃES A, FILHO WD, VALESCHKA DE MATOS GRANJA N, KARAN KALIL R, ET AL. Penile metastasis of chondrosarcoma of the jaw. *Urology.* 2003; 61(4): 837. [https://doi.org/10.1016/s0090-4295\(02\)02431-7](https://doi.org/10.1016/s0090-4295(02)02431-7)
- [7] PEREZ LM, SHUMWAY RA, CARSON CC, FISHER SR, HUDSON WR. Penile metastasis secondary to supraglottic squamous cell carcinoma: review of the literature. *J Urol.* 1992 Jan; 147(1): 157-60. [https://doi.org/10.1016/s0022-5347\(17\)37171-9](https://doi.org/10.1016/s0022-5347(17)37171-9)
- [8] Ammani A, Alami E, Kasmaoui E. H, Bazine K, BEDDOUCH A ET LEZREK M. *Penile metastases after cystoprostatectomy for urothelial carcinoma of the bladder.* *Afr J Urol* 2009; 15(3): 214-219. <https://doi.org/10.1007/s12301-009-0039-y>

- [9] Touzani MA, Yddoussalah O. Cavernous metastasis from bladder tumor]. Pan Afr Med J. 2017; 21(28): 60. <https://doi.org/10.11604/pamj.2017.28.60.13244>
- [10] Bordeau KP, Lynch DF. Transitional cell carcinoma of the bladder metastatic to the penis. Urology. 2004; May; 63(5): 981-3. <https://doi.org/10.1016/j.urology.2003.12.033>
- [11] GUEYE S. M, DIAGNE B. A, BA M. SYLLA C., MENSAH A. *CANCER OF THE PENIS: EPIDEMIOLOGICAL ASPECTS AND THERAPEUTIC PROBLEMS IN SENEGAL. M édecine d'Afrique Noire: 1992, 39 (8/9).*
- [12] DJE K, AVION KP, AKASSIMADOU N, COULIBALY N. Squamous cell carcinoma of the penis: a case report in an immunocompromised patient. Rev int sc m é d -RISM-2017; 19(1): 85-87.
- [13] GUIRASSY S, BAH OR, BAH I, BARRY MII, DIALLO A, DIALLO AB. Squamous cell carcinoma of the penis: a case report of 4 patients at the Urology Department of Conakry University Hospital. Uro' Andro 2018; 1(10): 470-73.

## Research Field

**Faye Samba Thiapato:** oncology, lithiasis, prostate, bladder, kidney, Erectile dysfunction

**Jalloh Mohamed:** Reconstructive Urology, Endourology, Prostate Cancer, Bladder cancer, HBP, Lithiasis

**Diallo Thierno Amadou:** Urology resident

**Thiam Jafar Abou Talib:** Surgical Oncologist, Gynecological Cancer

**Niang Rokhaya Désir é** Medical Oncologist, Chemotherapist

**Kikalulu Kiambote Hamidou:** Urology Resident

**Dembele Mamadou:** Urology Resident

**Kane Racine:** Andrology, Male infertility, Varicocele, Endourology, Kidney stones, Bladder cancer

**Niang Lamine:** Endourology, Kidney stones, Bladder cancer, Prostate cancer, Kidney Cancer, HBP