

Comprehensive Foveal Avascular Zone and Retinal Evaluation with Their Correlation to Visual Acuity and Glycemic Control in Diabetics Without Macular Edema

Mohamed M. Halfawy¹, Abdelrahman Gaber Salman¹, Azza M. A. Said¹, Tarek El Beltagi², Marwa A. Karim¹

¹Faculty of Medicine, Ain Shams University, Cairo, Egypt

²Research Institute of Ophthalmology, Giza, Egypt

Email address:

marwa_abdelkarim@med.asu.edu.eg (M. A. Karim)

To cite this article:

Mohamed M. Halfawy, Abdelrahman Gaber Salman, Azza M. A. Said, Tarek El Beltagi, Marwa A. Karim. Comprehensive Foveal Avascular Zone and Retinal Evaluation with Their Correlation to Visual Acuity and Glycemic Control in Diabetics Without Macular Edema.

International Journal of Ophthalmology & Visual Science. Vol. 7, No. 1, 2022, pp. 6-13. doi: 10.11648/j.ijovs.20220701.12

Received: December 31, 2021; **Accepted:** January 19, 2022; **Published:** January 25, 2022

Abstract: *Background:* Evaluating Foveal avascular zone by OCTA (Optical Coherence Tomography angiography) in diabetic patients, has a crucial role in early detection of pathophysiological changes affecting the macular area, and has a predictive value for early retinal neuro degenerative changes. *Materials and experiments:* *Aim:* To evaluate dimensions of Foveal Avascular Zone (FAZ) at level of superficial and deep capillary plexuses (SCP/DCP) in patients with different grades of non proliferative diabetic retinopathy without Diabetic Macular Edema (DME) using OCTA. Eighty type II diabetes mellitus patients and 20 healthy control, excluding proliferative diabetic retinopathy and DME. Divided to four groups according to ETDRS Classification. All underwent: measurement of glycosylated hemoglobin level, standard Structural OCT for the macula and optic nerve head with OCTA for evaluation of FAZ in both SCP and DCP networks of all eyes using (Heidelberg engineering, OCT spectralis, Germany) (SD-OCT). *Results:* Mean FAZ in SCP in control group (0.32 ± 0.12) mm² versus (0.44 ± 0.17) mm² in patients' group, while FAZ IN DCP (0.23 ± 0.12) in controls versus (0.34 ± 0.16) mm² in patients. There was a statistically significant wider FAZ in DR patients (P-value 0.003). *Conclusion:* Enlargement of FAZ in SCP and DCP in patients with moderate to severe NPDR without DME was detected using OCTA, Preceded by reduction in thickness of ORL and GCC layer. This can be used to monitor the progression of the disease and to evaluate the response to treatment.

Keywords: Diabetic Retinopathy, Foveal Avascular Zone, Optical Coherence Tomography Angiography

1. Background

Diabetic retinopathy (DR) is the major preventable blindness cause between working-age individuals in most of the developed countries, affecting one in three diabetic patients [1, 2]. The most frequent ocular complication is diabetic retinopathy (DR), which may range from being asymptomatic and may progress to severe vision loss [3]. The diabetic maculopathy, which include diabetic macular oedema (DME) and diabetic macular ischemia (DMI) are considered the most serious sight-threatening complications of DR [4]. Moreover PDR cosequential complications like - vitreous haemorrhage and retinal detachment. Early detection of DR and DME in routine screening of diabetics could be done by thorough

analysis of retinal fundus digital images [5-7]. Although it has high sensitivity and specificity, it has a low negative predictive value [7]. Optical Coherence Tomography (OCT) is privileged by being a non-invasive, rapid imaging modality that uses low-coherence interferometry to capture high resolution two dimensional images from different retinal layers optical scattering, thus allows imaging of the cross-sectional structures of the retina [8] OCT considered a vital tool for DME detection and monitoring [9] besides evaluation of DMI and inner retinal thinning [10]. Optical coherence tomography angiography (OCTA) is a novel breakthrough, allows retina and choroid microvasculature visualization without dye injection [11]. Its mechanism depends on repeated scans at the same location with detection of OCT reflectance signal

changes from the flow through blood vessels [12, 13]. It provides depth-resolved images for retinal vasculature. This intensifies its significant role in retinal conditions such as retinal arterial occlusion, retinal venous occlusion, DR, uveitis, and age-related macular degeneration [14, 15]. Studies have proved that the FAZ circumference, maximum and mean diameter are significantly wider in diabetic eyes compared to healthy controls. Microinfarction within the surrounding vascular arcades explains the pathophysiology of FAZ enlargement in DR [16].

2. Methods

The aim of our study to evaluate dimensions of foveal avascular zone FAZ at level of superficial and deep capillary plexuses (SCP, DCP) in patients with different grades of non-proliferative diabetic retinopathy DR without diabetic macular edema DME, using optical coherence tomography angiography OCTA; and to correlate these changes with the best corrected visual acuity, glycemic control of the patients and retinal neuro degenerative changes.

This cross sectional study was carried out from February 2018 to August 2018 on 100 eyes of patients attending outpatient clinic of Ophthalmology Department of Research Institute of Ophthalmology in Giza. The ethical standards stated by the ethical committee of Ain Shams University hospitals, were followed. This study was followed the tenets of the Declaration of Helsinki on Ethical Principles for Medical Research Involving Humans.

Inclusion Criteria: Age: 40-60 years, history of diabetes mellitus type II for more than 5 years.

2.1. Exclusion Criteria

Proliferative diabetic retinopathy., OCT evidence of diabetic macular edema of diverse types, refractive error of more than 6 diopters, opaque media, previous intra ocular surgeries except cataract extraction of more than one-year, previous treatment of diabetic retinopathy or DME, congenital or acquired retinal and optic nerve disorder with effect on the results, uncooperative patients, and patient with poor fixation.

2.2. Study Tools

1. Control group: 20 eyes of 20 normal healthy individuals of the same age and sex matched group. Right eye was examined by everyone as recommended for correct statistical analysis.
2. Study group: 80 eyes of diabetic patients were subdivided into four groups according to ETDRS Classification of Non Proliferative Diabetic Retinopathy (13).
 - 1) Study group (a): 20 eyes with diabetic patients without DR.
 - 2) Study group (b): 20 eyes with mild NPDR.
 - 3) Study group (c): 20 eyes with moderate NPDR.
 - 4) Study group (d): 20 eyes with severe NPDR.

All subjects were evaluated by: history, full ophthalmological examination,

measurement of glycosylated hemoglobin level (HbA1c), standard Structural Optical coherence tomography the macula and optic nerve head using (Heidelberg engineering, OCT spectralis, Germany) (SD-OCT) with imaging protocol of Macula scan and Optic disc scan, also Optical coherence tomography angiography for evaluation of foveal avascular zone FAZ of all eyes using the same machine. FAZ area was measured in both superficial and deep capillary networks (SCP and DCP layers) using software "Draw region" tool to outline FAZ area (inner border of the most visible central blood capillaries) manually, and software automatically calculate the outlined area.

This manual measurement was done by two independent investigators who were masked to all other results including BCVA (Best Corrected Visual Acuity) and retinal thickness. The average of their measurements were calculated and used to optimize the study results.

This study was followed the tenets of the Declaration of Helsinki on Ethical Principles for Medical Research Involving Humans. Study protocol was approved by the local research ethics committee.

2.3. Statistical Analysis

We used Statistical Package for Social Science (IBM SPSS) version 23. Chi-square test and Fisher exact test. Independent t-test, Mann-Whitney test, One Way ANOVA, Kruskal-Wallis test, and Spearman's correlation coefficients were also used.

3. Results

This study included 100 eyes of 66 patients, 30 (45.5%) males and 36 (54.5%) females with age ranging from 40 to 60 years, 20 eyes of normal healthy individuals (control group) and 80 eyes of diabetic patients were included. Diabetic divided according to severity to mild, moderate and severe. There was no history of hypertension or other medical conditions in all candidates.

Table 1: summary of demographic data:

1. There was no statistically significant difference found between control group and patients' group regarding mean age (P -value 0.103), also regarding Sex distribution (P -value 0.118).
2. Comparison between patients 'sub groups was done regarding mean duration and revealed highly statistically significant difference (P -value 0.000).
3. The mean HbA1c (\pm SD) in control was ($4.25\% \pm 0.83$), ranged was from 2.3 – 5.4% and in diabetic patients was (8.93 ± 2.33), ranged from 5.5 – 14%, with highly statistically significant difference found between control group and patients group regarding, HbA1c level (P -value 0.00), same for between control group and patients 'sub group (P -value 0.00).

Figure 1: Column graph shows comparison between control group and patients sub groups regarding HbA1c.

Table 1. Summary of demographic data.

		Control group	Patients group	Test value	P-value	Sig.
Age (years)	Mean \pm SD	48.9 \pm 6.72	51.54 \pm 6.32	-1.648*	0.103	NS
	Range	40 – 60	40 – 60			
Sex	Male	12 (60.0%)	18 (39.1%)	2.449*	0.118	NS
	Female	8 (40.0%)	28 (60.9%)			
Eye	Right	20 (100%)	38 (47.5%)	–	–	–
	Left	0 (0.0%)	42 (52.5%)			
	Unilateral DR	20 (100.0%)	12 (26.1%)	–	–	–
	Bilateral DR	0 (0.0%)	34 (73.9%)			
Duration (years)	Mean \pm SD	–	12.69 \pm 4.65	–	–	–
	Range	–	6 – 20			
HbA1c (%)	Mean \pm SD	4.25 \pm 0.83	8.93 \pm 2.33	-8.808*	0.000	HS
	Range	2.3 – 5.4	5.5 – 14			

*: Chi-square test; *: Independent t-test.

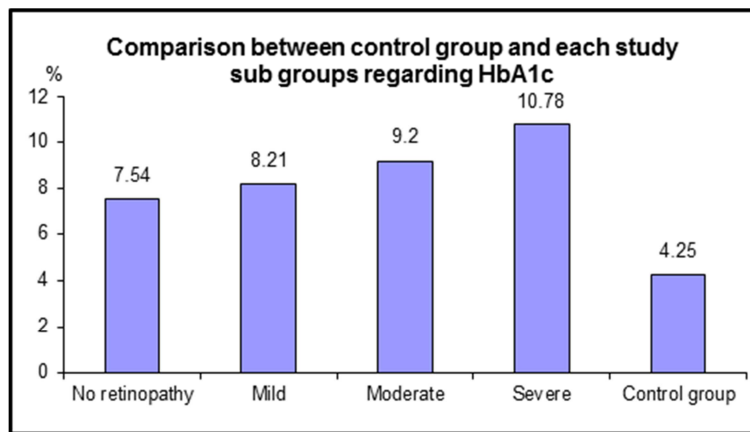


Figure 1. Column graph shows comparison between control group and patients sub groups regarding HbA1c.

3.1. Ophthalmological Examinations

1. Mean BCVA (log. MAR): The mean BCVA (\pm SD) recorded using Log. MAR in control was (0.0 ± 0.0) and in diabetic patient was (0.11 ± 0.11). There was highly statistically significant difference found between: control group and patients group regarding BCVA (*P*-value 0.002) and between control group and patients 'sub group' (*P*-value 0.001).
2. Cup disc ratio: The mean ratio (\pm SD) in control was (0.44 ± 0.07), ranged from 0.35-0.57 and in diabetic patients was (0.40 ± 0.10), ranged from 0.1 – 0.64. With no statistically significant difference found between control group and patients' group (*P*-value 0.098).
3. Structural OCT data: Comparison was done between control group and patients' group as regards:
 - 1) Mean total macular thickness (μ m): there was no statistically significant difference (*P*-values were >0.05) in average, central, superior, inferior, nasal, and temporal quadrants. Average thickness in control group ($322.89 \pm 16.31 \mu$ m) versus ($316.57 \pm 20.21 \mu$ m) in patients' group.
 - 2) Mean peripapillary retinal nerve fiber layer thickness (μ m): there was no statistically significant difference (*P*-values were >0.05) in all quadrants. Average RNFL thickness was ($158.61 \pm 12.99 \mu$ m) in control group vs.

(156.07 ± 22.58) μ m in patients' group.

- 3) Mean GCC layer thickness (μ m): There was no statistically significant difference in all quadrants (*P*-values were >0.05) except the nasal (*P*-value 0.012) and average (*P*-value 0.039) where there was statistically significant difference.

Comparison between control group and patients 'sub group' was done regarding mean GCC layer thickness, revealed a highly statistically significant difference between the control group and;

- 1) The moderate NPDR group regarding only mean superior (*P*-value 0.010).
- 2) The severe NPDR group regarding average and in all quadrants of the mean GCC layer thickness (*P*-values were ≤ 0.05) except the central one as shown in (Table 2).

Mean outer retinal layer thickness ORL (μ m): there was a statistically significant difference in mean average, central and in all quadrant (*P*-value were ≤ 0.05) except the temporal one (*P*-value was 0.13).

Comparison between control group and diabetic retinopathy 'sub group' was done; revealed:

- i. A statistically significant difference between control group and no retinopathy group regarding mean average and inferior ORL.
- ii. A statistically significant difference between control group and the moderate NPDR regarding mean average

and central ORL.
iii. A statistically significant difference between control

group and the severe NPDR regarding mean average and central and inferior ORL (Table 3).

Table 2. Comparison between control group and patient's subgroup regarding mean ganglion cell complex layer thickness.

Ganglion Cell Complex layer thickness (μm)		No retinopathy No. = 20	Mild No. = 20	Moderate No. = 20	Severe No. = 20	Control group No. = 20	Test value	P-value	Sig.
Average	Mean ± SD	43.31 ± 3.2	40.51 ± 6.37	39.92 ± 2.91	37.15 ± 7.82	43.17 ± 4.77	4.554	0.002	HS
	Range	38.2 – 47.6	25 – 49.8	33.2 – 43.8	19 – 47.2	30.6 – 49			
Central	Mean ± SD	14 ± 3.52	13.9 ± 3.57	14.05 ± 3.95	12.5 ± 3.79	14.85 ± 4.18	0.993	0.415	NS
	Range	8 – 21	8 – 22	7 – 23	7 – 20	8 – 22			
Superior	Mean ± SD	52.6 ± 3.25	49.95 ± 7.01	46 ± 7.09	44.35 ± 10.76	51.9 ± 5.33	5.201	0.001	HS
	Range	47 – 58	31 – 60	23 – 55	24 – 60	35 – 58			
Inferior	Mean ± SD	53 ± 3.48	49.1 ± 6.43	49.1 ± 3.6	46.95 ± 10.85	51.7 ± 5.16	2.707	0.035	S
	Range	47 – 58	35 – 58	41 – 57	23 – 69	40 – 59			
Nasal	Mean ± SD	50.25 ± 5.62	47.5 ± 7.33	47.3 ± 2.74	42.8 ± 8.54	51.25 ± 5.75	5.437	0.001	HS
	Range	35 – 58	27 – 58	42 – 53	22 – 57	38 – 58			
Temporal	Mean ± SD	46.7 ± 4.32	42.1 ± 11.96	43.15 ± 3.76	39.15 ± 9.83	46.15 ± 6.82	2.998	0.022	S
	Range	40 – 53	9 – 55	36 – 49	19 – 53	29 – 54			
Post hoc analysis									
	No vs control group		Mild vs control group		Moderate vs control group		Severe vs control group		
Superior	0.757		0.389		0.010		0.001		
Inferior	0.528		0.208		0.208		0.023		
Nasal	0.617		0.063		0.051		0.000		
Temporal	0.828		0.112		0.238		0.007		
Average	0.934		0.119		0.058		0.001		

Table 3. Comparison between control group and patient's subgroup regarding mean (ORL) thickness.

Mean (ORL) thickness		No retinopathy No. = 20	Mild No. = 20	Moderate No. = 20	Severe No. = 20	Control group No. = 20	Test value	P-value	Sig.
Average	Mean ± SD	80.13 ± 2.05	81.89 ± 4.29	80.27 ± 3.5	79.3 ± 3.79	82.56 ± 2.46	3.284	0.014	S
	Range	75.8 – 85	75 – 93.8	75.4 – 89.2	75 – 87.8	79.2 – 88.2			
Central	Mean ± SD	86.2 ± 3.04	88.6 ± 7.39	84.25 ± 4.35	82.95 ± 4.3	88.45 ± 2.86	5.739	0.000	HS
	Range	81 – 91	76 – 107	76 – 92	76 – 92	83 – 93			
Superior	Mean ± SD	78.4 ± 2.28	80.3 ± 2.66	79.6 ± 4.52	78.65 ± 3.5	81.15 ± 2.87	2.459	0.051	NS
	Range	74 – 83	75 – 87	72 – 92	74 – 84	76 – 86			
Inferior	Mean ± SD	77.35 ± 2.54	78.9 ± 2.73	78.05 ± 3.1	77 ± 3.48	79.75 ± 3.01	2.840	0.028	S
	Range	73 – 82	74 – 86	73 – 84	72 – 84	77 – 88			
Nasal	Mean ± SD	79.8 ± 2.31	80.35 ± 2.52	80.05 ± 4.3	79.9 ± 7.12	82.2 ± 2.55	1.132	0.346	NS
	Range	77 – 85	74 – 86	74 – 91	73 – 105	78 – 87			
Temporal	Mean ± SD	78.9 ± 2.29	81.3 ± 8.42	79.4 ± 4.41	78 ± 3.76	81.25 ± 2.77	1.824	0.131	NS
	Range	74 – 84	76 – 110	73 – 93	72 – 86	77 – 88			
Post hoc analysis									
	No vs control group		Mild vs control group		Moderate vs control group		Severe vs control group		
Inferior	0.013		0.371		0.075		0.005		
Central	0.132		0.919		0.006		0.000		
Average	0.023		0.525		0.032		0.003		

3.2. OCTA Data

1. Mean FAZ area in SCP (mm²):

1) There was a statistically significantly wider area in DR patients (*P-value* was 0.003) (Figure 3). Mean FAZ in SCP in control group (0.32 ± 0.12) mm² versus (0.44 ± 0.17) mm² in patients' group.

2) Comparison between control group and patients 'sub group' was done, revealed highly statistically significant difference between control group and moderate NPDR group and severe NPDR group regarding mean FAZ area (mm²). (Table 4).

2. Mean FAZ area in DCP (mm²):

1) FAZ IN DCP (0.23) mm² ± 0.12 in controls versus

(0.34 ± 0.16) mm² in patients.

2) There was a statistically significant wider area in DR patients (*P-value* was 0.006) (Figure 3).

3) Comparison between control group and patients 'sub group' was done regarding mean FAZ area in DCP (mm²) and revealed highly statistically significant difference between control group and severe NPDR group regarding mean FAZ area (mm²) in DCP as shown in (Table 4) (Figure 2).

4) There was no statistically significant difference found between the increases in SCP in patients than control when compared to the increase in DCP in patients than control (*P-value* was 0.320).

Table 4. Comparison between control group and patient's subgroup regarding mean FAZ (mm²) area in SCP and DCP.

		No retinopathy	Mild	Moderate	Severe	Control group	Test value•	P-value	Sig.
		No. = 20	No. = 20	No. = 20	No. = 20	No. = 20			
FAZ IN SVP	Mean ± SD	0.36 ± 0.1	0.35 ± 0.11	0.43 ± 0.16	0.6 ± 0.16	0.32 ± 0.12	14.783	0.000	HS
	Range	0.2 – 0.55	0.16 – 0.57	0.2 – 0.68	0.36 – 0.88	0.18 – 0.62			
FAZ IN DVP	Mean ± SD	0.28 ± 0.09	0.26 ± 0.09	0.31 ± 0.12	0.5 ± 0.18	0.23 ± 0.12	13.937	0.000	HS
	Range	0.16 – 0.46	0.1 – 0.44	0.13 – 0.54	0.17 – 0.83	0.08 – 0.49			
Post hoc analysis									
	No vs control group		Mild vs control group		Moderate vs control group		Severe vs control group		
FAZ IN SVP	0.294	0.358		0.009		0.000			
FAZ IN DVP	0.231	0.409		0.059		0.000			

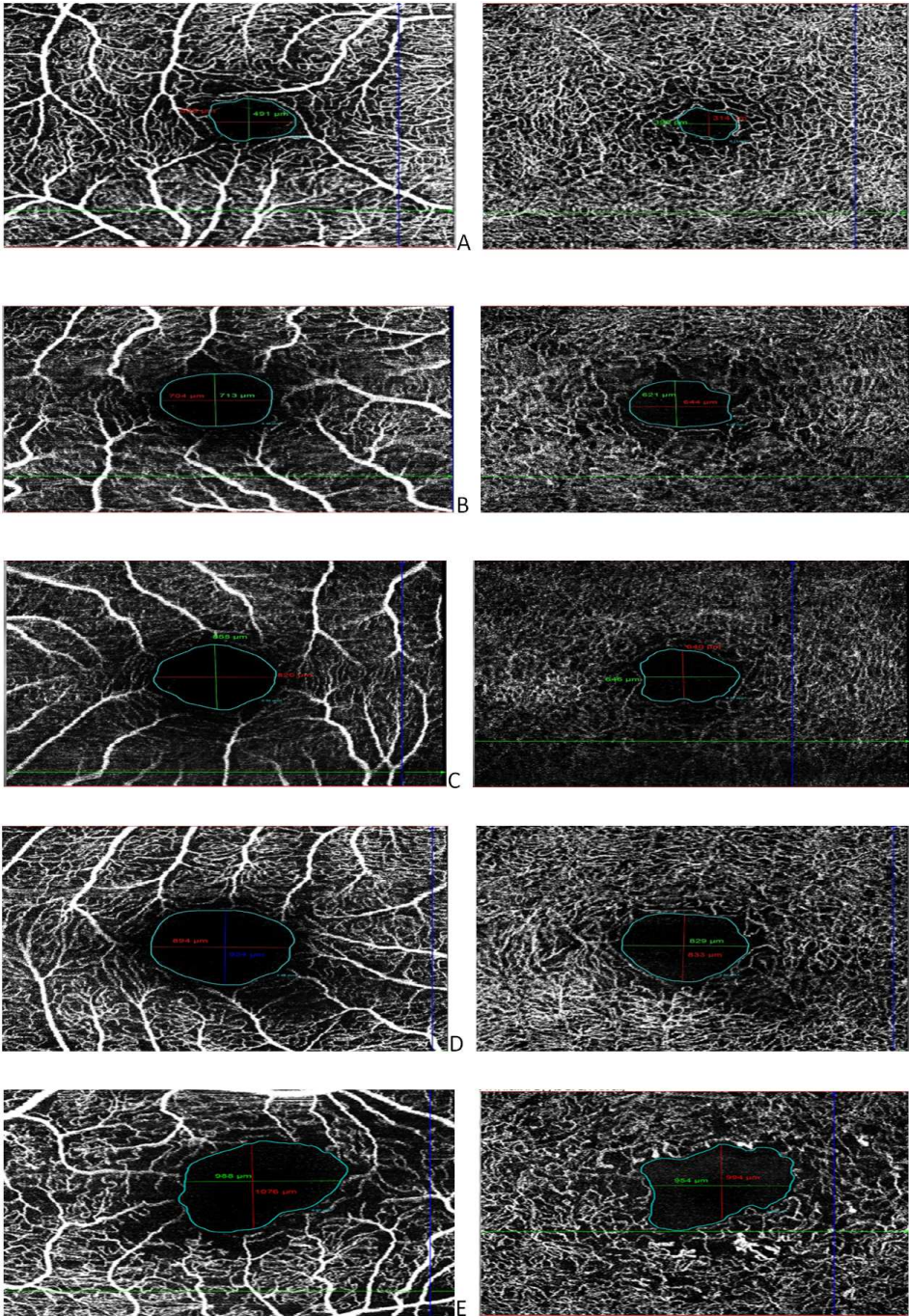


Figure 2. FAZ IN SCP (left) and DCP (right) of A. normal healthy individual B. no retinopathy patient C. mild NPDR patient D. moderate NPDR patient E. severe NPDR patient shows enlargement of FAZ in SCP and DCP In DR patients.

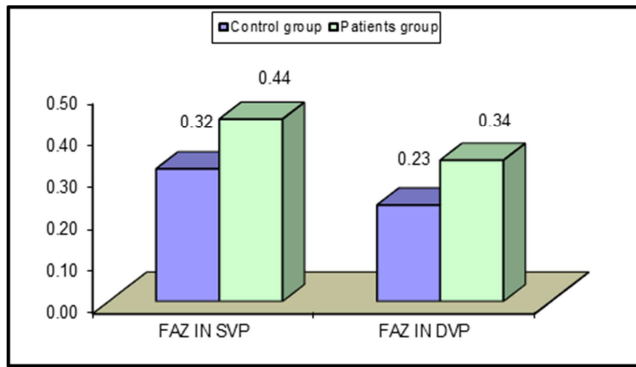


Figure 3. The column graph shows comparison between control group and patients' group regarding mean FAZ area (mm²) in SCP and DCP.

3. Spearman's correlation coefficient:

Correlation was done between various study variables and mean FAZ area (mm²).

- 1) In SCP and in DCP and there was a statistically significant positive correlation between mean FAZ area (mm²) in SCP and mean FAZ area (mm²) in DCP and BCVA (Log. MAR).
- 2) A statistically significant negative correlation between mean FAZ area (mm²) in SCP with mean superior, inferior, nasal, temporal, and central ganglion cell complex layer thickness, mean central ORL thickness.
- 3) No statistically significant correlation was found between the other studied parameters (Table 5).
- 4) There was no statistically significant relation between gender distribution and mean FAZ area (mm²) in SCP (*P-value* was 0.552) and DCP (*P-value* was 0.576).
- 5) Correlation was done between BCVA (Log. MAR) and mean central GCC layer thickness and mean ORL thickness and there was no any statistically significant correlation found between them (*P-values* were > 0.05).

Table 5. Correlation of FAZ in SCP and DCP with the other studied parameters.

	FAZ IN SCP		FAZ IN DCP	
	r	P-value	r	P-value
Age	0.015	0.892	0.043	0.708
Duration	0.150	0.183	0.146	0.197
HbA1c	0.158	0.160	0.135	0.231
BCVA	0.251*	0.025	0.216	0.054
C/D Ratio	-0.056	0.622	-0.105	0.353
FAZ IN SVP			0.896**	0.000
FAZ IN DVP	0.896**	0.000		
Ganglion Cell Complex				
Superior	-0.440**	0.000	-0.481**	0.000
Inferior	-0.228*	0.041	-0.277*	0.013
Nasal	-0.444**	0.000	-0.468**	0.000
Temporal	-0.408**	0.000	-0.495**	0.000
Central	-0.592**	0.000	-0.614**	0.000
Average	-0.489**	0.000	-0.557**	0.000
(ORL) thickness				
Superior	-0.013	0.910	-0.082	0.467
Inferior	-0.008	0.943	-0.108	0.339

	FAZ IN SCP		FAZ IN DCP	
	r	P-value	r	P-value
Nasal	-0.111	0.326	-0.184	0.103
Temporal	-0.092	0.416	-0.115	0.310
Central	-0.337**	0.002	-0.277*	0.013
Average	-0.115	0.309	-0.172	0.128

4. Discussion

OCTA is a novel technique that does not need dye for visualization of the retinal microvasculature. Therefore, the FAZ area can be optimally evaluated without the obscure of dye leakage [15], which occurs in the FFA, where capillary details are best evaluated during the transit phase, for that bilateral reliable evaluation of the FAZ is not possible. The choroidal and retinal circulation cause diffuse fluorescein leakage. Moreover microaneurysms and neovascularization obscure capillary details in FFA but not in OCTA O [17].

OCT images enable comparing the thickness and reflectance measurements of the various cellular layers of the retina in diabetic patients with DR against normal healthy subjects and diabetic patients who have no retinopathy. Thus allows better understanding of early histological changes of the macula in diabetes [18].

In this study, the FAZ areas of SCP and DCP were detected by OCTA in diabetic eyes without DME and correlated with BCVA, HbA1c and neurodegenerative changes. This study revealed a statistically significant enlargement of FAZ in patients with moderate NPDR group in SCP and severe NPDR group in both SCP and DCP.

These results came in agreement with Freiberg FJ et al, who noticed enlargement of the FAZ in SCP in eyes with diabetic retinopathy with significant difference against the control group. [19]

Moreover, Samara W A et al stated that a significantly greater FAZ area and significantly lower vascular density were noticed, in all diabetic eyes when compared with control eyes. [20]

Tang F Y et al reported that DR severity had the most influence and caused FAZ area increase and FAZ circularity decrease, concluding that the OCT-A can quantify the extent of microvascular breakdown (e.g., macular ischemia). [21]

This study found that there was a statistically significant positive correlation between FAZ in SCP and in DCP and BCVA (Log MAR). These results came in agreement with Samara W A et al, who stated that, a positive correlation was noticed between log MAR FAZ area and visual acuity in both the SCP/DCP networks. [20]

There was no statistically significant difference found between control group and patients' group regarding full macular thickness as we exclude DME.

There was no statistically significant difference was found between control group and patients' group regarding peripapillary retinal nerve fiber layer thickness RNFL and cup to disc ratio. This agreed with Vujosevic and Midena, although RNFL thickness was reduced in diabetics versus

controls, it did not reach statistical and clinical significance, probably since in this area, minor changes are more difficult to be clinically detected because of the high density of retinal nerve fibers. [22]

Pekel *et al.*, stated that, there were no statistically significant differences between the diabetic patients and healthy controls regarding RNFL, rim area, disc area, vertical cup-to-disc ratio, cup volume. [23]

In the present study, there was a statistically significant decrease in mean superior, inferior, nasal, temporal, ganglion cell complex layer GCL thickness in severe NPDR group and in mean superior GCL thickness in moderate NPDR group versus controls. There was, a statistically significant negative correlation between FAZ in SCP with superior, inferior, nasal, temporal and central GCL thickness.

This agrees with DE Buc and Somfai, who noticed a reduction of thickness of ganglion cell/inner plexiform layer (GCL+IPL) complex in the pericentral macular area in the mild diabetic retinopathy group. [24]

Fernández *et al.*, reported that the GCL+IPL complex thickness is significantly reduced in the pericentral macular area in the mild diabetic retinopathy group when compared to controls. [25]

The current study shows that there was a statistically significant decrease in mean central and inferior (ORL) thickness in severe NPDR group and in mean central (ORL) thickness in moderate NPDR group and in mean inferior (ORL) thickness in no retinopathy group versus controls and there was a statistically significant negative correlation between FAZ in SCP and central (ORL) thickness.

This was concordant with Wang *et al.*, who found that a significant reduction in the mean (ORL) thickness in DME and non DME groups compared to the control group. [26]

Sohn *et al.*, reported that retinal diabetic neuropathy may precede signs of micro vasculopathy or DR in people with DM, this came in agreement with the present study that there was neurodegenerative change even in no retinopathy patients. [27]

5. Conclusion

Enlargement of FAZ in SCP and DCP in patients with moderate to severe NPDR without DME was detected using OCTA with accurate delineation of the edges of these zones. These finding was preceded by neurodegenerative changes in the form of reduction in thickness of ORL and GCC layer. These vascular and neurological changes were moderately correlated to each other and to BCVA and the severity of the diseases. OCTA has a key role in quantifying the extent of microvascular breakdown in macular area {macular ischemia}, thus may determine the prognosis prior to any further treatment.

List of Abbreviations

DME: Diabetic Macular Edema

DMI: diabetic macular ischemia

ETDRS: Early Treatment Diabetic Retinopathy Study

FAZ: Foveal Avascular Zone

DR: Diabetic retinopathy

HbA1c: glycosylated hemoglobin level

NPDR: Non Proliferative Diabetic Retinopathy

OCT: Optical coherence tomography

OCTA: Optical coherence tomography-angiography

ORL: Outer retinal layer thickness

GC: Ganglion cell layer

PDR: Proliferative Diabetic Retinopathy

SVC: Superficial vascular complex

DVC: Deep vascular complex

SD-OCA: Spectral-domain Optical Coherence Angiography

BCVA: Best corrected Visual acuity

FFA: Fundus fluorescein angiography

Log MAR: Logarithm of Minimal Angle of Resolution

Declarations

1. *Consent to participate:* Informed consent was obtained from all individual participants included in the study.
2. *Consent to publish:* Patients signed informed consent regarding publishing their data and photographs.
3. *Availability of data and material (data transparency):* The datasets used and analyzed during the current study are available from the corresponding author on reasonable request.
4. *Competing interests:* The authors declare that they have no competing interests in this section.
5. *Funding:* No funding was received to assist with the preparation of this manuscript.
6. *Authors' Contribution Statement:*

Mohamed Mahmoud Mostafa was responsible for designing the study protocol, writing the protocol and report, conducting the search, screening potentially eligible studies, extracting and analyzing data, interpreting results, updating reference lists, and creating 'Summary of findings' tables. Abdel Rahman, Azza and Tarek were responsible for designing the study protocol and revising the results and discussion. Marwa contributed by authoring the paper, extracting, and analyzing data, interpreting results, and creating tables. Azza conducted the statistical analyses.

Ethics approval: Approval was obtained from the ethics committee of the Faculty of Medicine, Ain Shams University. The procedures used in this study adhere to the tenets of the Declaration of Helsinki.

Summary Statement

Enlargement of FAZ in SCP and DCP in patients with moderate to severe NPDR without DME was detected by OCTA, preceded by neurodegenerative changes as reduction in thickness of ORL and GCC layer. This gives a potential for monitoring disease progression and treatment response evaluation.

References

- [1] World Health Organization. Global report on diabetes. Geneva: World Health Organization; 2016.
- [2] Englgau MM, Geiss LS, Saaddine JB, et al. The evolving diabetes burden in the United States. *Ann Intern Med.* 2004; 140 (11): 945–50.
- [3] Fong DS, Aiello L, Gardner TW, et al. Diabetic retinopathy. *Diabetes Care.* 2003; 26 (suppl 1): s99–s102.
- [4] Mohamed Q, Gillies MC, Wong TY. Management of diabetic retinopathy systematic review. *JAMA.* 2007; 298 (8): 902–16.
- [5] Saari JM, Summanen P, Kivelä T, Saari KM. Sensitivity, and specificity of digital retinal images in grading diabetic retinopathy. *Acta Ophthalmol Scand.* 2004; 82 (2): 126–30.
- [6] Goh JK, Cheung CY, Sim SS, et al. Retinal imaging techniques for diabetic retinopathy screening. *J Diabetes Sci Technol.* 2016; 10 (2): 282–94.
- [7] D'Aloisio R, Giglio R, Di Nicola M, De Giacinto C, Pastore MR, Tognetti D, et al. Diagnostic accuracy of digital retinal fundus image analysis in detecting diabetic maculopathy in type 2 diabetes mellitus. *Ophthalmic Res.* 2019; 61 (2): 100–6.
- [8] Youngquist RC, Carr S, Davies DE. Optical coherence-domain reflectometry: a new optical evaluation technique. *opt Lett.* 1987; 12 (3): 158–60.
- [9] Virgili G, Menchini F, Casazza G, et al. Optical coherence tomography (OCT) for detection of macular oedema in patients with diabetic retinopathy. *Cochrane Database Syst Rev.* 2015; 1: CD008081.
- [10] Sim DA, Keane PA, Fung S, et al. Quantitative analysis of diabetic macular ischemia using optical coherence tomographic features of diabetic macular ischemia. *Invest Ophthalmol Vis Sci.* 2014; 55 (1): 417–23.
- [11] Fingler J, Readhead C, Schwartz DM, Fraser SE. Phase-contrast OCT imaging of transverse flows in the mouse retina and choroid. *Invest Ophthalmol Vis Sci.* 2008; 49 (11): 5055–9.
- [12] Hagag AM, Gao SS, Jia Y, Huang D. Optical coherence tomography angiography: Technical principles and clinical applications in ophthalmology. *Taiwan J Ophthalmol.* 2017; 7 (3): 115–29.
- [13] Ang M, Tan ACS, Cheung CMG, et al. Optical coherence tomography angiography: a review of current and future clinical applications. *Graefes Arch Clin Exp Ophthalmol.* 2018; 256 (2): 237–45.
- [14] Agarwal A, Grewal DS, Jaffe GJ, et al. Current role of optical coherence tomography angiography: Expert panel discussion. *Indian J Ophthalmol.* 2018; 66 (12): 1696–9.
- [15] Tan ACS, Tan GS, Denniston AK, et al. An overview of the clinical applications of optical coherence tomography angiography. *Eye (Lond).* 2018; 32 (2): 262–86.
- [16] Bresnick G H, Condit R, Syrjala S, et al. Abnormalities of the foveal avascular zone in diabetic retinopathy. *Arch Ophthalmol* 1984; 102 (9): 1286-1293.
- [17] Hwang TS, Jia Y, Gao SS, et al. Optical coherence tomography angiography features of diabetic retinopathy. *Retina* 2015; 35 (11): 2371–2376.
- [18] Gao W, Tátrai E, Ölvédy V, et al. Investigation of changes in thickness and reflectivity from layered retinal structures of healthy and diabetic eyes with optical coherence tomography. *J Biomed SciEng* 2011; 4: 657-665.
- [19] Freiberg FJ, Pfau M, Wons J, et al. Optical coherence tomography angiography of the foveal avascular zone in diabetic retinopathy. *Graefes Arch Clin Exp Ophthalmol* 2016; 254 (6): 1051-1058.
- [20] Samara W A, Shahlaee A, Adam M K, et al. Quantification of diabetic macular ischemia using optical coherence tomography angiography and its relationship with visual acuity. *Ophthalmology* 2017; 124 (2): 235-244.
- [21] Tang F Y, Ng D S, Lam A, et al. Determinants of quantitative optical coherence tomography angiography metrics in patients with diabetes. *Sci Rep* 2017; 7 (1): 2575.
- [22] Vujosevic S, Midená E. Retinal layers changes in human preclinical and early clinical diabetic retinopathy support early retinal neuronal and Müller cells alterations. *J Diabetes Res* 2013; 2013: 905058.
- [23] Pekel E, Altıncık SA, Pekel G. Evaluation of optic disc, retinal nerve fiber and macular ganglion cell layers in pediatric diabetes. *Int Ophthalmol* 2018; 38 (5): 1955-1961.
- [24] DeBuc DC, Somfai, GM. Early detection of retinal thickness changes in diabetes using optical coherence tomography. *Med SciMonit* 2010; 16 (3): 15-21.
- [25] Fernández DC, Somfai GM, Tátrai E, et al. Potentiality of intraretinal layer segmentation to locally detect early retinal changes in patients with diabetes mellitus using optical coherence tomography. *Invest Ophthalmol Vis Sci* 2008; 49 (13): 2751-2751.
- [26] Wang X N, Li ST, Li W, et al. The thickness and volume of the choroid, outer retinal layers, and retinal pigment epithelium layer changes in patients with diabetic retinopathy. *Int J Ophthalmol* 2018; 11 (12): 1957–1962.
- [27] Sohn E H, van Dijk H W, Jiao C, Kok P H, et al. Retinal neurodegeneration may precede microvascular changes characteristic of diabetic retinopathy in diabetes mellitus. *Proc Natl Acad Sci* 2016; 113 (19): 2655-2664.