

# Comparative Analysis of Two Low Cost Graft Fixation Procedures in Pterygium Surgery in a Developing Country

Shreesha Kumar Kodavoor<sup>1,\*</sup>, Raline Solomon Amalakaran<sup>2</sup>, Dandapani Ramamurthy<sup>3</sup>

<sup>1</sup>Department of Cornea & Refractive Services, The Eye Foundation Hospital, Coimbatore, India

<sup>2</sup>Post Graduate Resident, The Eye Foundation Hospital, Coimbatore, India

<sup>3</sup>Department Head, Cornea & Refractive Services, The Eye foundation Hospital, Coimbatore, India

## Email address:

eskay\_03@rediffmail.com (S. K. Kodavoor), solomon\_ral@yahoo.co.in (R. S. Amalakaran),

draramamurthi@theeyefoundation.com (D. Ramamurthy)

\*Corresponding author

## To cite this article:

Shreesha Kumar Kodavoor, Raline Solomon Amalakaran, Dandapani Ramamurthy. Comparative Analysis of Two Low Cost Graft Fixation Procedures in Pterygium Surgery in a Developing Country. *International Journal of Ophthalmology & Visual Science*.

Vol. 4, No. 3, 2019, pp. 46-50. doi: 10.11648/j.ijovs.20190403.12

Received: July 8, 2019; Accepted: August 12, 2019; Published: August 23, 2019

**Abstract:** Aim: To compare surgical outcomes of pterygium excision with conjunctival autograft using Sutures and Autologous blood for primary pterygium. Materials and methods: Retrospective study done in 404 eyes with primary pterygium. Excision of the pterygium and conjunctival autograft fixation using sutures (group 1) or Autologous blood (group 2). Graft related complications such as recurrence, graft loss, graft retraction, granuloma were noted and compared between the two groups. Result: The average time taken for surgery was  $10.66 \pm 0.89$  (group 1) and  $10.44 \pm 0.77$  (group 2) ( $p=0.009$ ). The recurrence rate following pterygium surgery was noted in 5eyes (2.5%) in group 1, and 10 eyes (4.9%) in group 2. Graft retraction was seen in 13 eyes in group 1, 57 eyes in group 2, of the eyes with graft retraction only 2 eyes in group 1, and 7 eyes in group 2 developed recurrence ( $p=0.763$ ). Graft loss was seen in 3eyes (1.49%) and in 7eyes (3.44%) in group 2, all patients who developed graft loss developed graft recurrence. Granuloma formation was seen in 2 eyes (0.99%) in group 1 and in 1eye (0.49%) in group 2. The cost of pterygium surgery using glue and autologous blood for conjunctival autograft fixation is much less than procuring and using fibrin glue. Conclusion: Fixing of graft and suturing it in place is important to prevent recurrence. Duration of surgical procedure is comparable. Recurrence and retraction rates are slightly higher in autologous blood group, but not statistically significant. Hence both sutures and autologous blood are very good treatment options for our patients with primary pterygium.

**Keywords:** Pterygium, Autologous Blood, Sutures, Autograft

## 1. Introduction

Pterygium is a fleshy fibrovascular growth of conjunctiva arising from subconjunctival tissue with extension on cornea and this extension may vary from patient to patient. A small pterygium causes only slight irritation, cosmetic blemish, and slight heaviness or redness in the eyes but with progression it can cause impairment of vision. Once it invades the cornea, it causes corneal opacity. [1] As far as aetiology is concerned apart from tropical environmental conditions and dry and dusty climate, deficiency of the stem cells is considered as one of the reason in various studies. [2] Pterygium

prevalence in rural Central India is about 13% among adult Indians aged above 30 years. [28] The prevalence of pterygium in South Indian population is 9.5%. [29] A number of surgical techniques have been described as methods for management of pterygium, including bare sclera resection, bare sclera resection followed by mitomycin C application at different point of time, doses, and concentrations and pterygium excision plus conjunctival autografting or amniotic membrane placement. [3-5] Conjunctival autografting has also been advocated for the management of recurrent pterygium. [6] Limbal conjunctival autograft is currently the most popular surgical procedure. [7] Glue is widely used due to many advantages like easy fixation of the

graft, shorter operation time, reduction in complications and postoperative discomfort but at the same time has some disadvantages also like high cost, the risk of transmission of infections and inactivation by iodine preparations. [8-10] The cost of procuring and preserving fibrin glue in a developing country like ours has made its use a difficult one for many. This study of ours was done to compare the outcomes of the 2 well known surgical techniques of graft fixation i.e using sutures and the suture-less, glue free graft fixation using autologous blood for pterygium surgery. We hope that this study would add to the growing knowledge and cost-effective management of pterygium surgery.

## 2. Materials and Methods

The study is a retrospective comparative study, at a tertiary eye care hospital in Tamilnadu, India, which forms a major belt of pterygium in southern India. Medical records of patients who underwent pterygium excision with conjunctival autografting between January 2011 and December 2016 were reviewed. 201 eyes of 194 patients [group 1] underwent pterygium excision with conjunctival autograft fixation using 10-0 monofilament nylon (Ethilon, Johnson & Johnson) and 203 eyes of 183 patients autologous blood [group 2] was used to fix the conjunctival autograft. Pterygium was graded based on the following grading: grade I – head of pterygium between limbus and a point midway between limbus and pupillary margin, grade II - head of the pterygium present between a point midway between limbus and pupillary margin (nasal pupillary margin in case of nasal pterygium and temporal margin in case of temporal pterygium), grade III - crossing pupillary margin. [11] Patients with primary pterygium grade 1 and 2, patients with primary pterygium having symptoms of irritation watering and redness and for cosmetic reasons were included. The study excluded patients with recurrent pterygium, fleshy pterygium accompanied by symblepharon or limitation of duction, double headed pterygium, glaucoma filtering bleb and glaucoma suspects. Informed consent was obtained from all patients. The study adhered to the tenets of the declaration of Helsinki and its amendments and was approved by the institutions review board (IRB).

### 2.1. Surgical technique

A single experienced surgeon performed all the surgeries. Topical proparacaine hydrochloride was applied 3 times at an interval of 10 minutes before the start of the surgery. A 0.5-1cc of 2% xylocaine (Astra Zeneca, UK) was injected subconjunctivally into the pterygium tissue. The pterygium was avulsed from the apex using a toothed forceps and a iris spatula, pterygium body and the underlying fibrovascular tissues were delineated from the conjunctiva and excised using conjunctival forceps. Gentle cauterisation was done to achieve haemostasis. Superior or the supero-temporal bulbar conjunctiva was selected as a donor site. 1-2cc of 2% xylocaine was injected subconjunctivally to separate conjunctiva from the Tenon's capsule. A small nick incision

was made using vannas scissors and a thin graft of adequate size was fashioned and placed on the bare scleral bed and sutured using either 10-0 monofilament nylon (Ethilon, Johnson & Johnson) in group 1. The sutures were removed 2 weeks after the surgery in symptomatic patients. For autologous blood graft fixation (group 2), a thin graft of size slightly bigger than the bare scleral defect was taken, a thin film of capillary blood was allowed to ooze over the bare sclera and the graft was placed over the area for a period of 5-6 minutes giving gentle pressure for the graft to adhere to the sclera. Total surgical time was noted from starting of conjunctival dissection to final fixation of graft in both the groups. Overnight patching was done in all the cases and the patient was seen on post-op day 1, 2 weeks, 6 weeks, 6 months and every year thereafter. Postoperatively patients were started on steroid- antibiotic combinations and tear substitutes for a period of 4 weeks.

### 2.2. Statistical Methods

Recurrence was considered as primary outcome variable. Complications following the procedure and time taken for the procedure were considered as other outcome variables. Study group (Suture Vs Auto blood) was considered as Primary explanatory variable.

Descriptive analysis was carried out by frequency and proportion for categorical variables. Data was also represented using appropriate diagrams like bar diagram, error bar and cluster bar diagram. The association between Study group (Suture Vs Auto blood) and recurrence was assessed by comparing the mean values. The mean differences along with 95% confidence interval was presented. Independent sample t-test was used to assess statistical significance. The association between explanatory variables and categorical outcomes was assessed by cross tabulation and comparison of percentages. Chi square test was used to test statistical significant P value < 0.05 was considered statistically significant. IBM SPSS version 22 was used for statistical analysis. [27]

## 3. Results

A total of 404 eyes were included in the final analysis. The mean age was  $47.32 \pm 10.99$  (group 1)  $46.6 \pm 11.96$  (group 2). The male: female ratio was comparable across the study groups. [Table 1] There were no statistically significant differences in age and gender across the study groups. The average time taken for surgery was  $10.66 \pm 0.89$  (group 1) and  $10.44 \pm 0.77$  (group 2), the results were statistically significant ( $p=0.009$ ) [Table 2]. The rate of recurrence following pterygium surgery was noted in 5 eyes (2.5%) in group 1, and 10 eyes (4.9%) in group 2. There was no significant correlation between the 2 groups ( $p=0.195$ ) [table 3]. Graft retraction was seen in 13 eyes in group 1, 57 eyes in group 2. Of the eyes with graft retraction only 2 eyes in group 1, and 7 eyes in group 2 developed recurrence ( $p=0.763$ ). Table 4 shows other complications related to graft fixation i.e in group 1, graft loss was seen in 3 (1.49%) eyes

and in 7 (3.44%) eyes in group 2, all patients who developed graft loss developed graft recurrence. Granuloma formation was seen in 2 (0.99%) eyes in group 1 and in 1 (0.49%) eye in group 2, however the results were not statistically

significant ( $p=0.556$ ) across the groups. 94.3% in Group 1 and 87.7% of patients in the group 2 had no graft related complications (Figures 1, 2).

**Table 1.** Demography of the study population ( $N=404$ ).

	GROUP 1 (N=201)	GROUP 2 (N=203)
AGE	47 $\pm$ 10.99	46.6 $\pm$ 11.96
MALES: FEMALES	80: 113	69: 114

**Table 2.** Comparison of mean duration in minutes between study groups ( $N=404$ ).

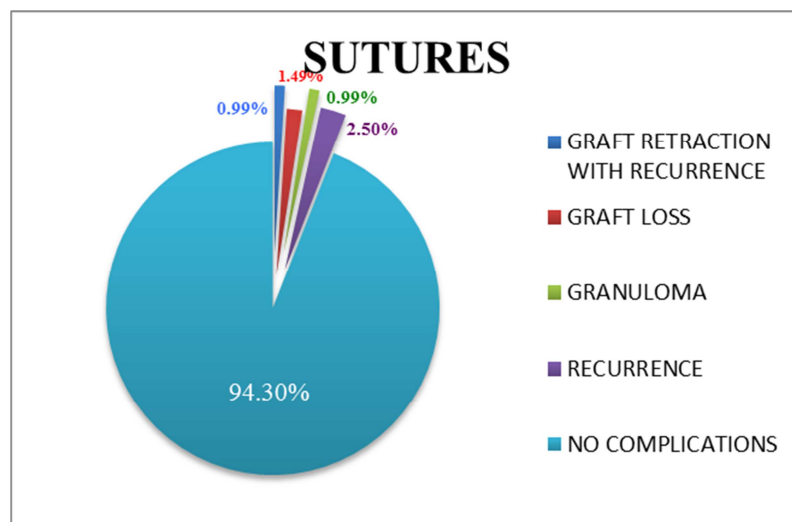
PARAMETER	SUTURE	AUTOLOGOUS BLOOD	P-VALUE
DURATION (in minutes)	10.66 $\pm$ 0.89	10.44 $\pm$ 0.77	0.009

**Table 3.** Comparison of recurrence between study groups ( $N=404$ ).

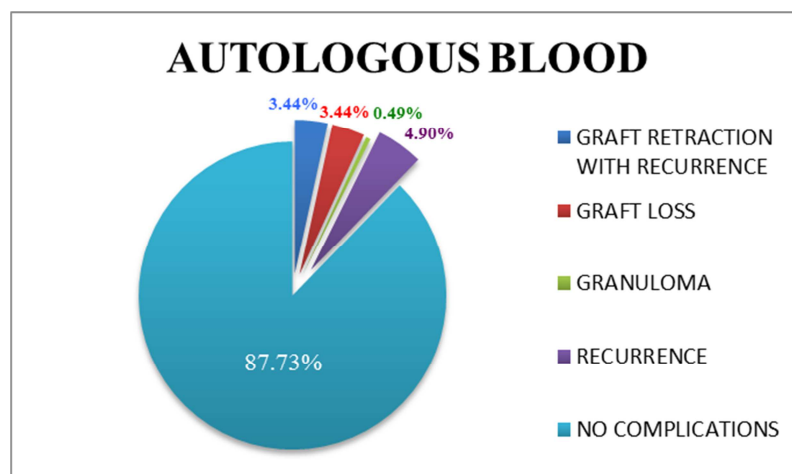
	SUTURE (N=201)	AUTOLOGOUS BLOOD (N=203)	P-VALUE
RECURRENCE	5 (2.5%)	10 (4.9%)	0.195

**Table 4.** Comparison of graft complication between study groups ( $N=404$ ).

GRAFT COMPLICATIONS	SUTURE (N=201)	AUTOLOGOUS BLOOD (N=203)	P-VALUE
Graft retraction with recurrence	2 out of 13 (15.38%)	7 out of 57 (12.28%)	0.763
Graft Loss	3 (1.49%)	7 (3.44%)	0.205
Granuloma	2 (0.99%)	1 (0.49%)	0.556



**Figure 1.** Pie chart showing graft related complications in group 1.



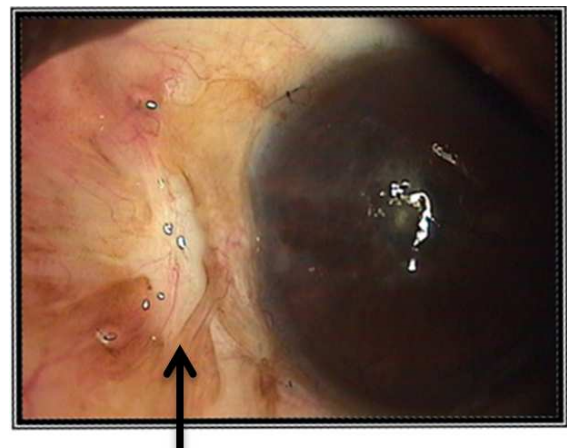
**Figure 2.** Pie chart showing graft related complications in group 2.

## 4. Discussion

The aim of performing pterygium surgery should not only be excision of pterygium but also prevention of its recurrence. Generally, the pterygium recurrences occur within the first 6 months after surgery. [12] Limbal conjunctival autograft transplantation re-establishes the barrier function of limbus and hence significantly lowers the recurrence rate. It is either attached with sutures, or with biological adhesive like fibrin glue, which is derived from pooled human plasma, or with autologous fibrin. Suturing of the autograft is rather time consuming and not comfortable to the patient. [14] Suzuki *et al.*, reported that use of silk or nylon suture causes conjunctival inflammation and Langerhan's cell migration into the cornea. [13] In addition, sutures may cause, dellen formation, symblepharon or graft tear. [15-16] Fibrin glue has low recurrence rates with shorter operation time, but disadvantages include potential risk of infection transmission, rarely hypersensitivity reactions, and higher cost. [17, 18] Glue less, sutureless technique has the advantages of eliminating the risk of transmitted infections and hypersensitivity reactions by using the patient's blood serum. A few studies have been done to evaluate the effectiveness of this novel technique. [19-23] Singh *et al.* suggested the recurrence rates of both fibrin glue-assisted conjunctival autografting and in situ coagulum were similar, however they reported that the complications such as graft displacement and graft retractions were seen more common in autologous blood group. [23]

In our study, we compared the two techniques i.e. sutured conjunctival limbal autograft (group 1) and sutureless and glue-free conjunctival limbal autograft (group 2) for primary pterygium surgery. We wanted to analyse the results of the two relatively inexpensive techniques having in mind the socio-economic status of the study population and the high prevalence of the condition in our study population. In our study, the average surgical time was only 10.65 minutes for group 1 and 10.44 minutes for group 2. A study by Javadekar *et al* duration of the surgery was  $13.96 \pm 3.212$  minutes in the autologous blood group, while it was  $30 \pm 4.641$  minutes in sutured group. [24] Singh *et al* suggested the recurrence rates of both fibrin glue-assisted conjunctival autografting and in situ coagulum were similar, however they reported that the complications such as graft displacement and graft retractions were seen more common in autologous blood group. [23] A study by Choudhury *et al* compared the effectiveness of suture-assisted technique (10/0 nylon sutures) and autologous blood coagulum. The rate of recurrence was equal in both groups (one patient in each group, 6.25%) and complications regarding graft failure and graft retraction were more common in group 2 (two patients, 12.5%) than group 1 (one patient, 6.25%). However, the difference was not statistically significant ( $Z=0.61$ ). [22] In our study the recurrence of pterygium was seen in 5 eyes (2.4%) in group 1 and in 10 eyes (4.9%) in group 2, after a minimum follow-up period of 6 months, the difference was not statistically significant ( $p$ -value=0.19). On comparing the graft retraction rates between

the 2 groups based on the study reports published by Choudhury *et al*, the graft retraction rate in the group 2 (57 eyes, 28%) was higher compared to group 1 (13 eyes, 6.4%) in our study. [22] However the number of patients who developed recurrence following a graft retraction in suture group was 1 eye and in autologous blood group were 7 eyes with no statistical significance ( $p=0.093$ ). Graft retraction was defined as the sliding of the graft from the side opposite to the limbal end, with the graft being firmly attached at the limbal side (Figure 3). The higher retraction in group 2 was because of weak adhesion bond (blood clot) between the bare sclera and the graft. This also explains the higher number of graft loss in the Autologous blood group (7 eyes) on comparison with the group 1 (3 eyes), and all the eyes which had graft loss had recurrence, but was not statistically significant ( $p=0.206$ ). In a study by Ashok sharma *et al* conjunctival granuloma was not seen in autologous blood group, although suture group reported 1 eye (4%) each of granuloma and recurrence after follow up of 6 months. [25] In our study granuloma formation was seen in 2 eyes (0.9%) in group 1, of which one needed excision and in only 1 eye (0.4%) in group 2.



Graft Retraction

**Figure 3.** Graft retraction at 6 months review.

The other important aspect of our study was to analyse the cost of surgery using sutures and autologous blood. In literature, Koranyi *et al* reported the cost of 0.5mL of fibrin glue was equal to the price of five 7/0 vicryl sutures. [8] Likewise, in a study by Bahar *et al*, they reported 2mL of fibrin glue was equal to five 7/0 vicryl sutures. [26] In our set up the cost of fibrin glue is 9 times the cost of 10-0 Nylon suture. There was no literature to compare the cost of surgery using sutures and autologous blood as the cost difference is very minimal and with the equally good outcomes between the two procedures, they could be offered to patients with a lower socio-economic background or in whom the cost of procuring and preserving fibrin glue would be expensive. The two surgical techniques can be extremely useful in places where the pterygium surgery load is high and where paying for other materials for surgery such as fibrin glue may add a financial burden on the patients from a lower socio-economic background.

## 5. Conclusion

Both sutures and autologous blood for conjunctival autograft fixation are safe and effective. Postoperative results of both techniques are comparable. Hence both sutures and autologous blood are viable, cost effective treatment options for primary pterygium in a country like ours where the prevalence of pterygium is high and affordability to a higher priced graft fixation material is low.

## Conflicts of Interest

No conflicts to report.

## References

- [1] Oldenburg JB, Garbus J, McDonnell JM, McDonnell PJ. Conjunctival pterygia: Mechanism of corneal topographic changes. *Cornea*. 1990; 9: 200-04.
- [2] Coroneo MT, Di Girolamo N, Wakefield D. The pathogenesis of pterygia. *Current opinion in ophthalmology*. 1999; 10 (4): 282-8.
- [3] D'Ombrian A. The surgical treatment of pterygium. *Br J Ophthalmol*. 1948; 32: 65-71.
- [4] Kunitomo N, Mori S. Studies on the pterygium: A treatment of the pterygium by mitomycin C instillation. *Acta Soc Ophthalmol Jpn*. 1963; 67: 601-07.
- [5] Mahar PS, Nwokora GE. Role of mitomycin C in pterygium surgery. *Br J Ophthalmol*. 1993; 77: 433-35.
- [6] Kenyon KR, Wagoner MD, Hettinger ME. Conjunctival autograft transplantation for advanced and recurrent pterygium. *Ophthalmology*. 1985; 92: 1461-70.
- [7] Malik KP, Goel R, Gupta A, Gupta SK, Kamal S, Mallik VK, et al. Efficacy of sutureless and glue-free limbal conjunctival autograft for primary pterygium surgery. *Nepal J Ophthalmol*. 2012; 4: 230-35.
- [8] Koranyi G, Seregard S, Kopp ED. Cut and paste: A no suture, small incision approach to pterygium surgery. *Br J Ophthalmol*. 2004; 88: 911-14.
- [9] Foroutan A, Beigzadeh F, Ghaempanah MJ, Eshghi P, Amirizadeh N, Sianati H, et al. Efficacy of autologous fibrin glue for primary pterygium surgery with conjunctival autograft. *Iranian Journal of Ophthalmology*. 2011; 23: 39-47.
- [10] Gilmore OJ, Reid C. Prevention of intraperitoneal adhesions: A comparison of noxythiolin and a new povidone - iodine/PVP solution. *British Journal of Surgery*. 1979; 66 (3): 197-9.
- [11] Maheshwari S. Pterygium-induced corneal refractive changes. *Indian Journal of Ophthalmology*. 2007; 55 (5): 383-386.
- [12] Adamis AP, Starck T, Kenyon KR. The management of pterygium. *Ophthalmol Clin North Am*. 1990; 3: 611-23.
- [13] Suzuki T, Sano Y, Kinoshita S. Conjunctival inflammation induces Langerhans cell migration into the cornea. *Current eye research*. 2000; 21 (1): 550-3.
- [14] Ti SE, Chee SP, Dear KB, Tan DT. Analysis of variation in success rates in conjunctival autografting for primary and recurrent pterygium. *Br J Ophthalmol*. 2000; 84: 385-89.
- [15] Kim HH, Mun JH, Park YJ, Lee KW, Shin PJ. Conjunctivolimbic autograft using a fibrin adhesive in pterygium surgery. *Korean J Ophthalmol*. 2008; 22: 147-54.
- [16] Elwan SAM. Comparison between sutureless and glue-free versus sutured limbal conjunctival autograft in primary pterygium surgery. *Saudi Journal of Ophthalmology*. 2014; 28: 292-98.
- [17] Ratnalingam V, Eu AL, Ng GL, Taharin R, John E. Fibrin adhesive is better than sutures in pterygium surgery. *Cornea*. 2010; 29 (5): 485-9.
- [18] Uy HS, Reyes JM, Flores JD, Lim-Bon-Siong R. Comparison of fibrin glue and sutures for attaching conjunctival autografts after pterygium excision. *Ophthalmology*. 2005; 112: 667-671.
- [19] Wit D, Athanasiadis I, Sharma A, Moore J. Sutureless and glue free conjunctival autograft in pterygium surgery: a case series. *Eye*. 2010; 24: 1474-1477.
- [20] Malik KPS, Goel R, Gupta A, Gupta SK, Kamal S, Malik VK, et al. Efficacy of sutureless and glue free limbal conjunctival autograft for primary pterygium surgery. *Nepal J Ophthalmol*. 2012; 4 (8): 230-23.
- [21] Kurian A, Reghunadhan I, Nair KG. Autologous blood versus fibrin glue for conjunctival autograft adherence in sutureless pterygium surgery: a randomised controlled trial. *Br J Ophthalmol*. 2015; 99 (4): 464-70.
- [22] Choudhury S, Dutta J, Mukhopadhyay S, Basu R, Bera S, Savale S, et al. Comparison of autologous in situ blood coagulum versus sutures for conjunctival autografting after pterygium excision. *Int Ophthalmol*. 2014; 34 (1): 41-48. 18.
- [23] Singh PK, Singh S, Vyas C, Singh M. Conjunctival autografting without fibrin glue or sutures for pterygium surgery. *Cornea*. 2013; 32 (1): 104-107.
- [24] Javadekar S et al. Autologous fibrin glue versus sutures for conjunctival autografting in pterygium surgery: a prospective comparative study. *International Journal of Recent Trends in Science And Technology*. 2013; 7 (1): 1-5.
- [25] Sharma A, Raj H, Gupta A, Raina AV. Sutureless and glue-free versus sutures for Limbal Conjunctival autografting in primary Pterygium surgery: a prospective comparative study. *Journal of clinical and diagnostic research: JCDR*. 2015; 9 (11): NC06.
- [26] Bahar I, Weinberger D, Dan G, Avisar R. Pterygium surgery: fibrin glue versus Vicryl sutures for conjunctival closure. *Cornea*. 2006; 25 (10): 1168-72.
- [27] Machines IB. IBM SPSS Statistics for Windows, Version 22.0. IBM Corp Armonk, NY; 2013.
- [28] Nangia V, Jonas JB, Nair D, Saini N, Nangia P, Panda-Jonas S. Prevalence and associated factors for pterygium in rural agrarian central India. The central India eye and medical study. *PLoS one*. 2013 Dec 4; 8 (12): e82439.
- [29] Asokan R, Venkatasubbu RS, Velumuri L, Lingam V, George R. Prevalence and associated factors for pterygium and pinguecula in a South Indian population. *Ophthalmic and Physiological Optics*. 2012 Jan; 32 (1): 39-44.