

Normative Study to Correlate the Effects of Morphological Variables on Macular and Choroidal Thickness Using SD-OCT

Sumeet Chopra¹, Preet Kanwar Singh Sodhi^{2,*}, Akash Deep Goel³, Sehajpreet Kaur¹, Gurkirat Singh Bajwa¹

¹Department of Ophthalmology, Dayanand Medical College and Hospital, Baba Farid University of Health Sciences, Ludhiana, India

²Department of Vitreo-Retina, Sodhi Eye Hospital, Patiala, India

³Department of Cornea, LV Prasad Eye Institute, Hyderabad, India

Email address:

choprasumeet36@gmail.com (S. Chopra), psodhi56@yahoo.co.in (P. K. S. Sodhi), akashdeep.goel@gmail.com (A. D Goel),

sehaj2605@gmail.com (S. Kaur), gbajwa9@rediffmail.com (G. S. Bajwa)

*Corresponding author

To cite this article:

Sumeet Chopra, Preet Kanwar Singh Sodhi, Akashdeep Goel, Sehajpreet Kaur, Gurkirat Singh Bajwa. Normative Study to Correlate the Effects of Morphological Variables on Macular and Choroidal Thickness Using SD-OCT. *International Journal of Ophthalmology & Visual Science*. Vol. 4, No. 1, 2019, pp. 1-6. doi: 10.11648/j.ijovs.20190401.11

Received: January 2, 2019; **Accepted:** January 21, 2019; **Published:** February 13, 2019

Abstract: To determine macular and choroidal thickness in healthy north Indian eyes and determine its variation with age and height using SD-OCT. The macula of 400 randomly selected healthy subjects (800 eyes) with no retinal and choroidal pathology was imaged with Cirrus SD-OCT. Macular thickness from all 9 regions of Early Treatment Diabetic Retinopathy Study was evaluated. Choroid was visualized by enhanced depth imaging technique. Choroidal thickness was measured sub foveally and at 500 microns intervals upto 1500 microns temporal and nasal to the fovea. The mean age of the subjects was 33.60 years \pm 14.033 and mean height was 163.5 cms \pm 11.715. Mean central macular thickness (CMT) was 242.59 μ m \pm 16.802 and mean sub foveal choroidal thickness was 325.18 μ m \pm 47.087. CMT correlated significantly (Pearson's correlation coefficient) with age ($r=0.120$, $p<0.001$) and height ($r=0.258$, $p<0.001$). Choroidal thickness decreased with age and the correlation was statistically significant. Choroidal thickness also decreased with height with a statistically significant correlation, but no specific pattern was found. This normative database of choroidal and macular thickness by OCT will serve as baseline for diagnosing retinal pathologies and help in future research.

Keywords: Choroidal Thickness, Macular Thickness, Normative Study, Spectral-Domain Optical Coherence Tomography (SD-OCT), North Indian

1. Introduction

Macular edema is a common cause of visual impairment, and the degree of macular thickening is significantly correlated with visual acuity. [1] The assessment of the macular region is an important parameter in the management of several ophthalmic conditions like diabetic retinopathy, age-related macular degeneration, central serous chorio-retinopathy (CSCR), retinal vein occlusion etc where an increase in retinal thickness can be seen due to fluid accumulation.

Choroidal abnormalities such as vascular hyper

permeability or loss and thinning are critical to the onset and progression of many chorioretinal diseases such as central serous chorioretinopathy, Vogt-Koyanagi-Harada disease, high myopia-related chorioretinal atrophies, age-related macular degeneration and polypoidal choroidal vasculopathy. The choroidal thickness (CT) may be affected by many local and systemic conditions.

With the recent development of enhanced depth imaging (EDI), in-vivo assessment of choroid has become an area of interest. EDI helps in better visualization of choroid and the chorio-scleral junction, which allows an accurate quantitative assessment of the choroid, which was not possible before. [2]

Studies have reported significant differences in macular thickness amongst subjects of different race, gender and age. [3, 4] Thus it is desirable that measurements derived from the normative population be as close as possible to the population for which the instrument is to be used.

Recent literature has shown the effect of age, sex, axial length (AXL), refractive error, and diurnal variation on the Choroidal Thickness. [5, 6] Various studies have reported a normal range of choroidal thickness. [7-9] Previous reports on CT are mostly from the western world and from the Asian countries including Japan and China. Hence, we undertook this prospective study for evaluating the normal retinal and choroidal thickness in normal healthy north Indian subjects and also evaluated the effect of various morphological variables on the thicknesses.

2. Materials and Methods

This prospective observational study consisted of 400 randomly selected subjects (800 eyes), who visited the OPD, at Department of Ophthalmology, Dayanand Medical College & Hospital, Ludhiana, Punjab, India in whom the chorio-scleral junction could be identified with an image quality of $\geq 6/10$. Prior approval from the Institutional Review Board of the institute was taken and informed consent was obtained from each subject. This study was conducted in accordance with the tenets of the Declaration of Helsinki for research involving human subjects. All subjects had a best corrected visual acuity of 20/20. Patients with any retinal or choroidal pathology, Refractive error of $> \pm 6$ Diopters sphere or $> \pm 3$ diopters cylinder, media opacities, intra ocular pressure > 21 mm, history of use of any drug causing retinopathy, history of any systemic disease with known ocular involvement, pregnant females, history of use of oral contraceptive pills, glaucoma were excluded from study.

Both eyes per subject were scanned. All scans had an image quality factor of 6/10 or greater and were taken as close to fovea as possible, such that the thinnest point of the macula was imaged. OCT scanning was performed using CIRRUS HD-OCT (MODEL 5000, SD-OCT, CARL ZEISS MEDITEC, INC, DUBLIN, USA) with software version 6.5.

The fast macula thickness map was used, which comprises 3 concentric circles centred at the fovea that divided the macula into 3 zones; the fovea (1 mm diameter), the inner macula (1 to 3 mm) and the outer macula (3 to 6 mm). The 3 mm inner ring and 6 mm outer ring are further divided into

four equal regions. The choroid was visualized by enhanced depth imaging (EDI) technique with spectral domain optical coherence tomography using a standardized scanning protocol. A single line of 6 mm length centered horizontally on the fovea was used for the visualization of the choroid. The vertical distance between the posterior edge of the hyper reflective RPE layer and the chorio-scleral interface was measured manually using the software calipers. Choroidal thickness was measured sub foveally and 500 microns intervals up to 1500 microns temporal and nasal to the fovea.

All the data including OCT parameters were stored in a MS Excel 2007 spreadsheet. Statistical analysis was done using SPSS software version 18.0.

3. Results

We included 800 eyes of 400 healthy subjects for analysis in this study. There were 206 men (412 eyes) and 194 women (388 eyes). Mean age of the subjects was $33.60 \text{ years} \pm 14.033$ and mean height was $163.5 \text{ cm} \pm 11.715$. All patients were phakic.

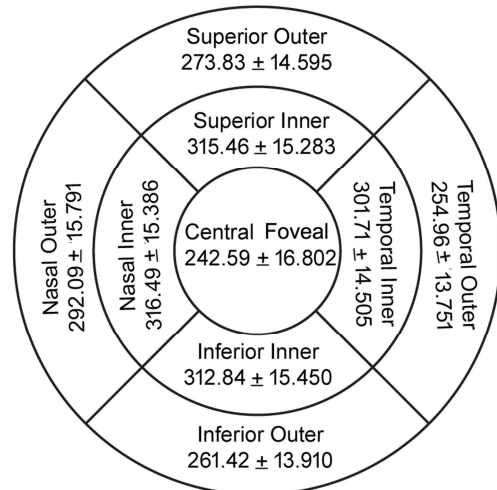


Figure 1. Normative Data for Retinal Thickness in Various ETDRS Sub Fields.

Mean Foveal thickness was $242.59 \mu\text{m} \pm 16.802$. The inner circle of ETDRS grid showed maximum retinal thickness and there was a decrease towards periphery. The retina was the thickest on nasal side with maximum thickness of inner nasal macula (Figure 1).

Table 1. Normative Data for Choroidal Thickness.

Area of Measurement	Mean Choroidal Thickness (μm) \pm Standard Deviation
Temporal 1500 μm	293.40 \pm 46.686
Temporal 1000 μm	306.59 \pm 46.358
Temporal 500 μm	316.32 \pm 46.723
Sub Foveal	325.18 \pm 47.087
Nasal 500 μm	314.42 \pm 47.889
Nasal 1000 μm	302.81 \pm 49.649
Nasal 1500 μm	286.09 \pm 52.013

Mean sub foveal choroidal thickness was $325.18 \mu\text{m} \pm 47.087$. The choroid was thickest at subfoveal area. A gradual decrease of choroidal thickness was noted towards periphery. This decrease was more on nasal side than on the temporal side (Table 1).

Table 2. Mean Retinal Thickness (μm) Variations with Age \pm S.D.

ETDRS Sub Field	Group A (≤ 20 Years) N=188	Group B (21-30 Years) N=178	Group C (31-40 Years) N=154	Group D (41-50 Years) N=180	Group E (51-60 Years) N=86	Group F (> 60 Years) N=14	Total N=800	Overall p value
Foveal	240.53 \pm 15.657	243.15 \pm 15.168	241.76 \pm 20.315	243.36 \pm 16.459	244.69 \pm 16.674	249.36 \pm 11.222	242.59 \pm 16.802	0.192
Temporal Inner	300.65 \pm 14.416	303.08 \pm 13.528	300.74 \pm 14.379	302.00 \pm 14.515	301.03 \pm 17.352	309.43 \pm 5.095	301.71 \pm 14.505	0.186
Superior Inner	313.79 \pm 15.085	316.89 \pm 14.637	314.82 \pm 14.159	315.63 \pm 17.143	315.64 \pm 15.283	323.36 \pm 9.516	315.46 \pm 15.283	0.164
Nasal Inner	315.28 \pm 15.237	317.42 \pm 15.056	315.84 \pm 15.601	316.83 \pm 15.850	316.56 \pm 15.992	323.43 \pm 5.971	316.49 \pm 15.386	0.413
Inferior Inner	311.37 \pm 15.145	314.16 \pm 15.217	312.31 \pm 15.443	312.53 \pm 16.328	313.87 \pm 15.456	319.29 \pm 8.260	312.84 \pm 15.450	0.299
Temporal Outer	254.03 \pm 14.283	255.01 \pm 12.999	254.29 \pm 12.306	255.97 \pm 15.447	255.36 \pm 13.117	258.50 \pm 12.113	254.96 \pm 13.751	0.671
Superior Outer	272.06 \pm 14.671	273.43 \pm 13.272	274.19 \pm 15.110	274.49 \pm 12.739	276.00 \pm 19.094	276.71 \pm 14.019	273.83 \pm 14.595	0.326
Nasal Outer	290.93 \pm 15.875	291.49 \pm 16.520	292.29 \pm 13.528	293.06 \pm 17.121	292.84 \pm 14.939	296.00 \pm 16.678	292.09 \pm 15.791	0.698
Inferior Outer	260.50 \pm 13.041	260.97 \pm 15.042	261.93 \pm 12.697	261.55 \pm 14.990	262.87 \pm 13.281	263.43 \pm 13.535	261.42 \pm 13.910	0.783

Central foveal thickness was minimum in age < 20 years and maximum in the older age group with age > 60 years while it was almost similar in age groups from 21-60 years (Table 2). The central foveal thickness had a significant positive correlation with age ($r = 0.120$, $p < .001$) with an increase of 1.43 μm thickness per decade. The retinal thickness in the superior outer quadrant had a statistically significant negative correlation with age with a decrease of 0.067 μm per decade (Table 3).

Table 3. Retinal thickness correlation with age.

ETDRS Sub Field	Minimum Thickness (μm)	Maximum Thickness (μm)	Mean Thickness (μm) \pm S.D.	Change per Decade (μm)	Correlation (r)	Significance (p-Value)
Central foveal	190	305	242.59 \pm 16.802	1.43	0.120	0.000
Temporal Inner	219	338	301.71 \pm 14.505	-0.18	-0.017	0.314
Superior Inner	208	360	315.46 \pm 15.283	-0.4	-0.022	0.270
Nasal Inner	267	357	316.49 \pm 15.386	0.11	-0.010	0.384
Inferior Inner	250	349	312.84 \pm 15.450	0.22	0.020	0.283
Temporal Outer	222	357	254.96 \pm 13.751	0.42	0.043	0.114
Superior Outer	241	395	273.83 \pm 14.595	-0.69	-0.067	0.030
Nasal Outer	247	341	292.09 \pm 15.791	-0.43	-0.038	0.139
Inferior Outer	205	321	261.42 \pm 13.910	-0.16	-0.016	0.329

Table 4. Mean Choroidal Thickness (μm) Variations with Age \pm S.D.

Area of Measurement	Group A (≤ 20 Years) N=188	Group B (21-30 Years) N=178	Group C (31-40 Years) N=154	Group D (41-50 Years) N=180	Group E (51-60 Years) N=86	Group F (> 60 Years) N=14	Total N=800	Over all p value
Temporal 1500 μm	292.98 \pm 48.724	291.26 \pm 49.012	293.94 \pm 46.666	294.75 \pm 43.600	296.17 \pm 44.318	285.93 \pm 47.433	293.40 \pm 46.686	0.943
Temporal 1000 μm	305.86 \pm 47.940	305.06 \pm 47.837	305.76 \pm 47.990	308.91 \pm 43.995	308.99 \pm 43.104	300.29 \pm 41.926	306.59 \pm 46.358	0.943
Temporal 500 μm	315.70 \pm 48.061	314.78 \pm 47.671	315.51 \pm 47.991	318.48 \pm 45.445	318.65 \pm 42.998	310.93 \pm 46.861	316.32 \pm 46.723	0.958
Sub Foveal	324.25 \pm 48.058	324.26 \pm 47.239	324.31 \pm 48.508	327.78 \pm 45.843	326.34 \pm 45.144	318.29 \pm 50.237	325.18 \pm 47.087	0.955
Nasal 500 μm	313.46 \pm 48.067	313.44 \pm 48.903	314.45 \pm 48.214	316.07 \pm 47.206	316.17 \pm 47.043	307.36 \pm 50.066	314.42 \pm 47.889	0.978
Nasal 1000 μm	302.81 \pm 48.538	302.03 \pm 51.200	302.62 \pm 49.307	302.61 \pm 49.896	306.31 \pm 50.043	295.86 \pm 50.118	302.81 \pm 49.649	0.980
Nasal 1500 μm	287.84 \pm 49.167	284.43 \pm 55.195	286.33 \pm 52.495	284.69 \pm 51.630	289.77 \pm 52.826	276.50 \pm 48.381	286.09 \pm 52.013	0.921

Choroidal thickness was the least in the individuals with age > 60 years (Table 4). The subfoveal choroidal thickness had a significant negative correlation with age ($r = -0.297$, $p < .001$) with a decrease of 9.97 μm per decade (Table 5).

Table 5. Choroidal thickness correlation with age.

Area of Measurement	Minimum Thickness (μm)	Maximum Thickness (μm)	Mean Thickness (μm) \pm S.D.	Change per Decade (μm)	Correlation (r)	Significance (p-Value)
Temporal 1500 μm	134	443	293.40 \pm 46.686	-10.29	-0.309	0.000
Temporal 1000 μm	144	436	306.59 \pm 46.358	-9.95	-0.301	0.000
Temporal 500 μm	154	439	316.32 \pm 46.723	-10.19	-0.306	0.000
Sub Foveal	157	436	325.18 \pm 47.087	-9.97	-0.297	0.000
Nasal 500 μm	160	448	314.42 \pm 47.889	-9.14	-0.268	0.000
Nasal 1000 μm	141	438	302.81 \pm 49.649	-7.97	-0.225	0.000
Nasal 1500 μm	112	413	286.09 \pm 52.013	-7.01	-0.189	0.000

Table 6. Mean Retinal Thickness (μm) Variations with Height \pm S.D.

ETDRS Sub Field	Group X	Group Y	Group Z	Total N=800	Over all p value
	($\leq 150\text{Cms}$) N=110	(151-165 Cms) N=352	(>165 Cms) N=338		
Foveal	238.95 \pm 16.193	238.69 \pm 16.427	247.83 \pm 15.992	242.59 \pm 16.802	<0.001
Temporal Inner	298.50 \pm 10.982	297.84 \pm 14.065	306.78 \pm 14.459	301.71 \pm 14.505	<0.001
Superior Inner	311.69 \pm 10.596	312.11 \pm 14.837	320.17 \pm 15.798	315.46 \pm 15.283	<0.001
Nasal Inner	313.00 \pm 10.868	312.87 \pm 15.540	321.40 \pm 15.156	316.49 \pm 15.386	<0.001
Inferior Inner	309.68 \pm 11.298	309.25 \pm 15.172	317.61 \pm 15.664	312.84 \pm 15.450	<0.001
Temporal Outer	250.99 \pm 9.613	252.49 \pm 14.626	258.82 \pm 13.006	254.96 \pm 13.751	<0.001
Superior Outer	270.95 \pm 10.866	273.44 \pm 16.985	275.16 \pm 12.716	273.83 \pm 14.595	0.025
Nasal Outer	289.98 \pm 12.022	291.04 \pm 16.121	293.86 \pm 16.372	292.09 \pm 15.791	0.020
Inferior Outer	259.40 \pm 12.302	259.80 \pm 14.568	263.77 \pm 13.383	261.42 \pm 13.910	<0.001

Retinal thickness was the maximum in group-Z i.e. with a height more than 165 cms, while it was almost similar in other height groups (Table 6). The retinal thickness had a significant positive correlation with height with a variation in the range of 2.250-5.550 μm in the each height group in various ETDRS sub fields (Table 7).

Table 7. Retinal thickness correlation with height.

ETDRS Sub Field	Minimum Thickness (μm)	Maximum Thickness (μm)	Mean Thickness (μm) \pm S.D.	Change per Group (μm)	Correlation (r)	Significance (p-Value)
Central foveal	190	305	242.59 \pm 16.802	-5.55	0.258	0.000
Temporal Inner	219	338	301.71 \pm 14.505	-5.34	0.288	0.000
Superior Inner	208	360	315.46 \pm 15.283	-5.115	0.261	0.000
Nasal Inner	267	357	316.49 \pm 15.386	-5.415	0.275	0.000
Inferior Inner	250	349	312.84 \pm 15.450	-5.295	0.268	0.000
Temporal Outer	222	357	254.96 \pm 13.751	-4.32	0.245	0.000
Superior Outer	241	395	273.83 \pm 14.595	-2.25	0.120	0.000
Nasal Outer	247	341	292.09 \pm 15.791	-2.58	0.127	0.000
Inferior Outer	205	321	261.42 \pm 13.910	-2.685	0.151	0.000

Table 8. Mean Choroidal Thickness (μm) Variations with Height \pm S.D.

Area of Measurement	Group X	Group Y	Group Z	Total N=800	Over all p value
	($\leq 150\text{Cms}$) N=110	(151-165 Cms) N=352	(>165 Cms) N=338		
Temporal 1500 μm	288.96 \pm 46.586	297.00 \pm 47.269	291.09 \pm 45.969	293.40 \pm 46.686	0.142
Temporal 1000 μm	304.77 \pm 48.705	309.97 \pm 45.412	303.66 \pm 46.458	306.59 \pm 46.358	0.184
Temporal 500 μm	313.17 \pm 48.646	319.97 \pm 45.231	313.53 \pm 47.482	316.32 \pm 46.723	0.145
Sub Foveal	321.93 \pm 49.868	328.80 \pm 45.171	322.47 \pm 47.987	325.18 \pm 47.087	0.155
Nasal 500 μm	310.25 \pm 50.341	317.54 \pm 46.269	312.53 \pm 48.667	314.42 \pm 47.889	0.241
Nasal 1000 μm	298.67 \pm 50.955	305.79 \pm 48.607	301.05 \pm 50.258	302.81 \pm 49.649	0.294
Nasal 1500 μm	281.59 \pm 52.693	288.95 \pm 51.212	284.58 \pm 52.602	286.09 \pm 52.013	0.337

The maximum choroidal thickness was observed in Group-Y i.e. with height range from 151-165 cms and it showed a fall in other groups that is with higher and lower height groups (Table 8). The choroidal thickness had a significant negative correlation with height with a decrease in the range of 4.020 to 5.580 μm at various points of measurements (Table 9).

Table 9. Choroidal thickness correlation with height.

Area of Measurement	Minimum Thickness (μm)	Maximum Thickness (μm)	Mean Thickness (μm) \pm S.D.	Change per group (μm)	Correlation (r)	Significance (p-Value)
Temporal 1500 μm	134	443	293.40 \pm 46.686	4.020	-0.067	0.029
Temporal 1000 μm	144	436	306.59 \pm 46.358	5.580	-0.094	0.004
Temporal 500 μm	154	439	316.32 \pm 46.723	5.385	-0.090	0.005
Sub Foveal	157	436	325.18 \pm 47.087	5.445	-0.090	0.005
Nasal 500 μm	160	448	314.42 \pm 47.889	4.785	-0.078	0.014
Nasal 1000 μm	141	438	302.81 \pm 49.649	4.980	-0.078	0.013
Nasal 1500 μm	112	413	286.09 \pm 52.013	4.335	-0.065	0.033

4. Discussion

The assessment of the macular and choroidal region is an important parameter in the management of several ophthalmic diseases. Prior to labeling the macula or choroid as abnormal, it is important to determine the range of normal macular and choroidal thickness and the factors on which they depend.

Our study consisted of 487 subjects initially out of which those 400 were included in whom the chorio-scleral junction could be identified with an image quality of $\geq 6/10$. Out of the 400 included patients 206 (51.50%) were males and 194 (48.50%) were females. All the patients were phakic and both eyes were evaluated. The mean age of the subjects was 33.60 ± 14.033 years (range 9-67 years).

The mean foveal thickness was $242.59 \mu\text{m} \pm 16.802$. Previous studies have shown that Asians and African-Americans have thinner maculae when compared to Caucasians. [10, 11] The mean thickness in the central 1 mm diameter area was found to be $176.4 \mu\text{m}$ in Chinese, [12] $181.2 \pm 18.4 \mu\text{m}$ in Indians, [13] $183.2 \pm 1.3 \mu\text{m}$ in Thai, [14] $209.5 \pm 26.7 \mu\text{m}$ in Japanese, [15] and $212 \pm 20 \mu\text{m}$ in Caucasians [16] using different OCT machines. Our study showed almost similar retinal thickness with the studies done by Song et al. [17], Gupta et al. [18] using Cirrus HD-OCT. The difference in the measurements is due to the fact that time domain (TD-OCT) measures retinal thickness as the distance between internal limiting membrane (ILM) and the third hyper-reflective band, whereas SD OCT measures the distance between ILM and the retinal pigment epithelium (RPE) resulting in higher SD OCT readings compared to those obtained by TD-OCT.

On evaluating the macular thickness in the 9 ETDRS regions in our population, the nasal macula (inner and outer areas) was significantly thicker than the temporal macula, a finding consistent with previous studies. [4, 18, 20] This could be because of the thicker papillo-macular bundle of the retinal nerve fiber layer (RNFL) in this region.

We found no specific pattern of retinal variation with height, although a positive statistically significant correlation was found at all the measured points ($p < .001$). A positive and significant correlation between the retinal thickness and body height has been reported by Takehiro Yamashita et al. [20]

Using the criteria of mean ± 2 Standard Deviations, which includes 95% of the population, we suggest that 210-275 μm be taken as the normal range for central foveal thickness in the north Indian population using CIRRUS OCT.

Our study of a healthy north Indian population showed a mean subfoveal choroidal thickness of $325.18 \pm 47.087 \mu\text{m}$ with a mean age of 33.60 years, which was more than a Korean population [21] ($307.3 \pm 95.2 \mu\text{m}$) with a mean age of 40.18 years, an adult Spanish population [22] ($305.6 \pm 102.6 \mu\text{m}$) with a mean age of 53 years and a Chinese population [23] ($261.9 \pm 88.4 \mu\text{m}$) with a mean age of 49.73 years and lesser than a Japanese population [24] ($354 \pm 111 \mu\text{m}$) with a

mean age of 39.4 ± 16.0 , a mixed ethnic population of UK [25] ($332 \pm 90 \mu\text{m}$) with a mean age of 24.46 ± 1.12 and a Turkish population [26] in which the mean subfoveal CT was $348 \pm 68 \mu\text{m}$. The differences in mean subfoveal choroidal thickness may result from differences in the mean age of each study.

Choroidal thickness was thickest below the fovea. The present study also showed that the nasal choroid was significantly thinner than the subfoveal and temporal choroid. The reason for could be the choroidal watershed, which isolates the choroidal circulation, as seen on fluorescein or indocyanine green angiography.

Choroidal thickness was strongly negatively correlated with age at all the measured locations suggesting that progressive choroidal thinning occurs over time in normal eyes. However, our study did not have the power to show a statistically significant difference between younger subjects and subjects older than 60 years of age due to small number of subjects older than 60 years with good quality images.

We found no specific pattern of choroidal variation with height, although a small negative statistically significant correlation was found below the fovea ($r = -.090$ $p = .005$), so its clinical significance cannot be commented on.

According to our knowledge, this is the first study which describes normative values in healthy North Indian subjects. Intra-observer and Intra-observer variations could alter the results, these could not be evaluated in the study done. Intra-eye variations were evaluated though, which didn't show any statistically significant co-relation.

5. Conclusions

A normative database was established for the north Indian population of the retinal and choroidal thickness which is important to diagnose the abnormalities. Normal central retinal thickness for a north Indian population is $242.59 \mu\text{m} \pm 16.802$ and subfoveal choroidal thickness is $325.18 \mu\text{m} \pm 47.087$ using Cirrus HD-OCT. Central macular thickness is positively correlated ($r = 0.120$, $p < .001$) while sub foveal choroidal thickness is negatively correlated ($r = -0.297$, $p < .001$) with age. Central macular thickness is positively correlated ($r = .0258$, $p < .001$) while sub foveal choroidal thickness is negatively correlated ($r = -0.090$, $p = .005$) with height.

Acknowledgements

The authors acknowledge the role of the entire staff of Department of Ophthalmology, Dayanand Medical College and Hospital, Ludhiana, Punjab where the study was conducted. The management's role for the conduct of study is also acknowledged. The role of Dr Sanjeev Maheshwari for biostatistics and preparation of the manuscript is also deeply acknowledged.

References

- [1] Nussenblatt RB, Kaufman SC, Palestine AG, Davis MD, Ferris FL. Macular thickening and visual acuity: Measurements in patients with cystoid macular edema. *Ophthalmology*. 1987; 94:1134–1139.
- [2] Spaide RF, Koizumi H, Pozonni MC. Enhanced depth imaging spectral-domain optical coherence tomography. *Am J Ophthalmol*. 2008; 146 (4): 496-500.
- [3] Choovuthayakorn J, Watanachai N, Chaikitmongkol V, Patikulsila D, Kunavisarut P, Ittipunkul N: Macular thickness measured by spectral-domain optical coherence tomography in healthy Thai eyes. *Jpn J Ophthalmol*. 2012; 56 (6):569-76.
- [4] Zia S Pradhan, Andrew Braganza, Lekha M Abraham: Determinants of macular thickness in normal Indian eyes. *J. Clin Oph. Res*. 2013; 1 (1):11-16.
- [5] Barteselli G, Chhablani J, El-Emam S, Wang H, Chuang J, Kozak I, et al. Choroidal volume variations with age, axial length, and sex in healthy subjects: A three dimensional analysis. *Ophthalmology* 2012; 119:2572-8.
- [6] Tan CS, Ouyang Y, Ruiz H, Sadda SR. Diurnal variation of choroidal thickness in normal, healthy subjects measured by spectral domain optical coherence tomography. *Invest Ophthalmol Vis Sci*. 2012; 53:261-6.
- [7] Manjunath V, Taha M, Fujimoto JG, Duker JS. Choroidal thickness in normal eyes measured using Cirrus HD optical coherence tomography. *Am J Ophthalmol*. 2010; 150 (3):325-9.
- [8] Hirata M, Tsujikawa A, Matsumoto A, Hangai M, Ooto S, Yamashiro K, et al. Macular choroidal thickness and volume in normal subjects measured by swept source optical coherence tomography. *Invest Ophthalmol Vis Sci*. 2011; 52:4971-8.
- [9] Ikuno Y, Kawaguchi K, Nouchi T, Yasuno Y. Choroidal Thickness in healthy Japanese subjects. *Invit Ophthalmol Vis Sci*. 2010; 51 (4):2174-6.
- [10] Kelty PJ, Payne JF, Trivedi RH, Kelty J, Bowie EM, Burger BM. Macular thickness assessment in healthy eyes based on ethnicity using Stratus OCT optical coherence tomography. *Invest Ophthalmol Vis Sci*. 2008; 49 (6):2668-72.
- [11] Huang J, Liu X, Wu Z, Xiao H, Dustin L, Sadda S. Macular thickness measurements in normal eyes with time-domain and Fourier domain optical coherence tomography. *Retina* 2009; 29 (7):980-7.
- [12] Duan X. R., Liang Y. B., Friedman D. S., et al. Normal macular thickness measurements using optical coherence tomography in healthy eyes of adult Chinese persons. *Ophthalmology*. 2010; 117 (8):1585–1594.
- [13] Tewari H, Wagh V, Sony P, Venkatesh P, Singh R. Macular thickness evaluation using the optical coherence tomography in normal Indian eyes. *Indian J Ophthalmol*. 2004; 52 (3):199-204.
- [14] Manassakorn A, Chaidaroon W, Ausayakhun S, Aupapong S, Wattanikorn S. Normative database of retinal nerve fiber layer and macular retinal thickness in a Thai population. *Jpn J Ophthalmol*. 2008; 52 (6):450-6.
- [15] Oshitari T, Hanawa K, Adachi-Usami E. Macular and retinal nerve fiber layer thickness in Japanese measured by Stratus optical coherence tomography. *Clin Ophthalmol*. 2007; 1:133-40.
- [16] Chan A, Duker JS, Ko TH, Fujimoto JG, Schuman JS. Normal macular thickness measurements in healthy eyes using Stratus optical coherence tomography. *Arch Ophthalmol*. 2006; 124 (2):193-8.
- [17] Song WK, Lee SC, Lee ES, Kim CY, Kim SS. Macular Thickness Variations with Sex, Age, and Axial Length in Healthy Subjects: A Spectral Domain–OCT Study. *Invest Ophthalmol Vis Sci*. 2010; 51 (8):3913-8.
- [18] Gupta P, Sidhartha E, Tham YC, Chua DK, Liao J, Cheng CY, et al. Determinants of macular thickness using spectral domain optical coherence tomography in healthy eyes: the Singapore Chinese Eye study. *Invest Ophthalmol Vis Sci*. 2013; 54:7968-76.
- [19] Bindu Appukuttan, Anantharaman Giridhar, Mahesh Gopalakrishnan, and Sobha Sivaprasad. Normative spectral domain optical coherence tomography data on macular and retinal nerve fiber layer thickness in Indians. *Indian J Ophthalmol*. 2014 Mar; 62 (3): 316–321.
- [20] Terasaki H, Shirasawa M, Yamashita T, et al. Comparison of foveal microstructure imaging with different spectral domain optical coherence tomography machines. *Ophthalmology*. 2012; 119 (11):2319-27.
- [21] Kim M, Kim SS, Koh HJ, Lee SC. Choroidal thickness, age and refractive error in healthy Korean subjects. *Optom Vis Sci*. 2014; 91:491–496.
- [22] Ruiz-Moreno JM, Flores-Moreno I, Lugo F, Ruiz-Medrano J, Montero JA, Akiba M. Macular choroidal thickness in normal pediatric population measured by swept-source optical coherence tomography. *Invest Ophthalmol Vis Sci*. 2013; 54:353–359.
- [23] Xiaoyan Ding, Jiaqing Li, Jing Zeng, Wei Ma, Ran Liu, Tao Li, Shanshan Yu, and Shibo Tang. Choroidal Thickness in Healthy Chinese Subjects. *IOVS*, December 2011; Vol. 52, No. 13:9555-9560.
- [24] Yasushi Ikuno, Kana Kawaguchi, Takeyoshi Nouchi,, and Yoshiaki Yasuno Choroidal Thickness in Healthy Japanese Subjects. *Investigative Ophthalmology & Visual Science*, April 2010; Vol. 51, No. 4: 2174-2176.
- [25] Rahman W, Chen FK, Yeoh J, Patel P, Tufail A, Da Cruz L. Repeatability of manual subfoveal choroidal thickness measurements in healthy subjects using the technique of enhanced depth imaging optical coherence tomography. *Invest Ophthalmol Vis Sci* 2011; 52:2267-71.
- [26] Ihsan Yilmaz, Abdullah O, Murat K, Sibel A, Hande M. O, Dilek Y, Alper A, Ahmet T. Y, Ahmet D. Correlation of choroidal thickness and Body Mass Index. *Retina* 35:2085–2090, 2015.