

# New Possible Clinical Variant of Syndrome Associating, Posterior Microphthalmos, Retinitis Pigmentosa, Foveoschisis, and Optic Disc Drusen: Report Case and Review of the Literature

**Said Iferkhass\*, Nihad Elhalouat, Hatim Boui, Anas Bouassel, Abdalkader Laktaoui**

Ophthalmology Department, Military Hospital My Ismail, Meknes, Morocco

## Email address:

Said224@yahoo.fr (S. Iferkhass), elhalouatnihad8@gmail.com (N. Elhalouat), boui.hatim@gmail.com (H. Boui),  
atta.anass@gamil.com (A. Bouassel), laktaouia@gmail.com (A. Laktaoui)

\*Corresponding author

## To cite this article:

Said Iferkhass, Nihad Elhalouat, Hatim Boui, Anas Bouassel, Abdalkader Laktaoui. New Possible Clinical Variant of Syndrome Associating, Posterior Microphthalmos, Retinitis Pigmentosa, Foveoschisis, and Optic Disc Drusen: Report Case and Review of the Literature. *International Journal of Ophthalmology & Visual Science*. Vol. 3, No. 4, 2018, pp. 55-59. doi: 10.11648/j.ijovs.20180304.12

**Received:** November 3, 2018; **Accepted:** November 15, 2018; **Published:** December 24, 2018

---

**Abstract:** To report a possible new clinical variant of the syndrome: posterior microphthalmia - retinitis pigmentosa – retinoschisis and papillary drusen and review the literature for this clinical entity. This is a 9 years old child without particular pathological story. His parents had had consanguineous marriage. His best visual acuity was improved to 3/10 with +16.00 SD (diopter spherical) OD (right eye) and 2/10 OS (left eye) with +17.00 SD. Anterior segment examination was normal. On the dilated fundus, we found a crowded optic disc associated to a bilateral maculopathy with white spots at the retinal periphery in the both eyes. Therefore we realized: Ultrasound imaging, Fluorescent angiography, Optical coherence tomography, and visual evoked potential with electroretinography. A and B scan ultrasonography revealed a posterior microphthalmia. Autofluorescence images and fluorescent angiography showed peripapillary atrophy with drusen. Optical coherence tomography (OCT) analysis of the macula at the vertical scan line revealed retinoschisis and prominent retinal fold in the papillomacular region. An OCT section across a retinal white spot shows a hyper-reflective deposit in the subretinal space, pushing the line of the photoreceptors. The electroretinogram showed a very marked decrease in rod response and cone hypovoltage in favor to retinal dystrophy compatible with retinitis pigmentosa. This case shows a new clinical variant of the posterior microphthalmia syndrome - retinitis pigmentosa, papillary drusen and retinoschisis described only once in the literature characterized by the presence of retinal white spots. In this clinical situation, the contribution of electroretinography in diagnosis is crucial. From this clinical description other studies may be realized to discover the new gene mutations related to this entity.

**Keywords:** Posterior Microphthalmia, Retinitis Pigmentosa, Retinoschisis, Papillary Drusen, White Spots

---

## 1. Introduction

Microphthalmia is defined as total axial length of eyeball at least 2 standard deviations below age – similar controls [1].

“Posterior microphthalmia” (PM) is a rare type of microphthalmia. It affects the posterior ocular segment which is foreshortened, whilst the anterior segment dimensions including corneal diameter, anterior chamber depth and anteroposterior length of the lens are normal [2-3].

This type of microphthalmia, associated with retinitis pigmentosa, and foveoschisis with papillary drusen, represent a rare recent syndrome.

Our case describes a new clinical variant of this entity.

## 2. Case Report

A nine year old boy, only child in his family, was referred to us for the evaluation of decreased vision. According to the patient’s parents, he had never seen well, even though he had

been wearing glasses since he was two years old.

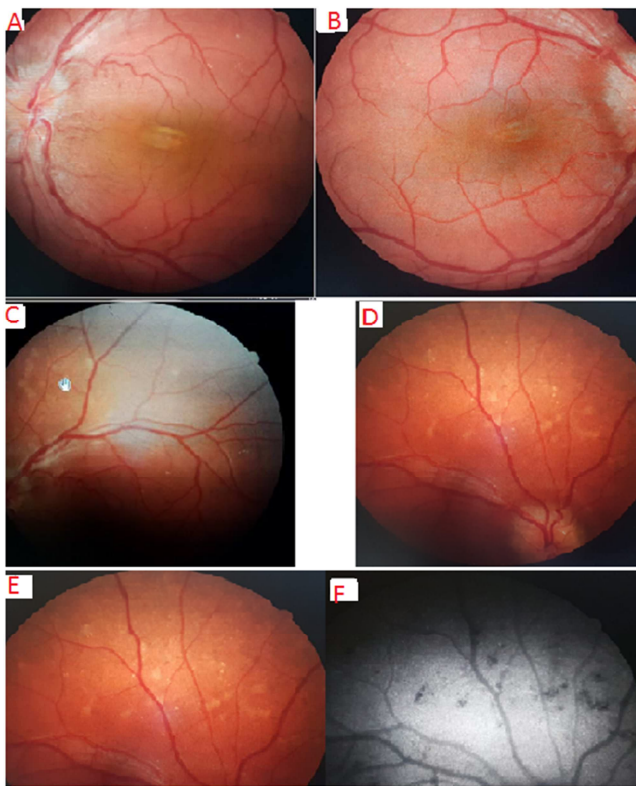
His medical, surgical, drug and birth history were uneventful. His parents had had consanguineous marriage.

On examination, the best visual acuity was improved to 3/10 with +16.00 SD (spherical diopter) OD (right eye) and 2/10 OS (left eye) with +17.00 SD.

The patient was orthophoric and had normal oculomotricity.

His anterior segment examination was unremarkable and the intraocular pressure was 12 and 14 mm Hg in the OD and OS respectively

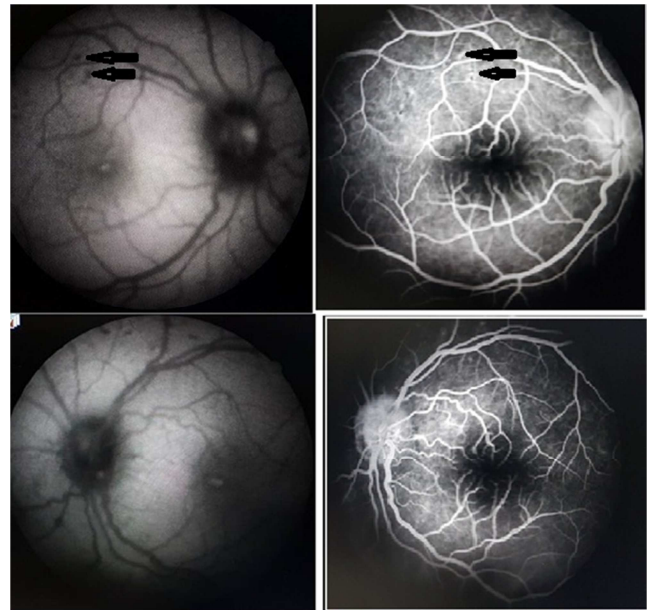
Examining the dilated fundus, we found a crowded optic disc with blurred margin (papilledema or pseudo-papilledema), associated to a bilateral maculopathy (figure 1), with white spots at the retinal periphery in the both eyes (figure 1).



**Figure 1.** Fundus photo of the right (A) and the left (B) eye showing bilateral crowded optic disc and slightly elevated horizontal papillomacular retinal folds (dolphin shaped). White spots in retinal periphery of the right eye (C) and the left eye (D). Deep round spots of yellow-white color in retinography of the right eye (E), these spots are hypofluorescent (F).

So a bilateral neuroretinitis was therefore suspected. We realized an autofluorescence images (figure 2) which showed a hypofluorescent peripapillary zone with some autofluorescent spots in it, representing papillary drusen, and the white retinal spots appears hypofluorescent. Fluorescent angiography (figure 2) showed peripapillary atrophy with small autofluorescent peripapillary formations

at the early sequences, impregnated at the last ones. In addition, we found a reduction in the foveal avascular area of both eyes. The white spots found in retinal periphery were impregnated with fluorescein.



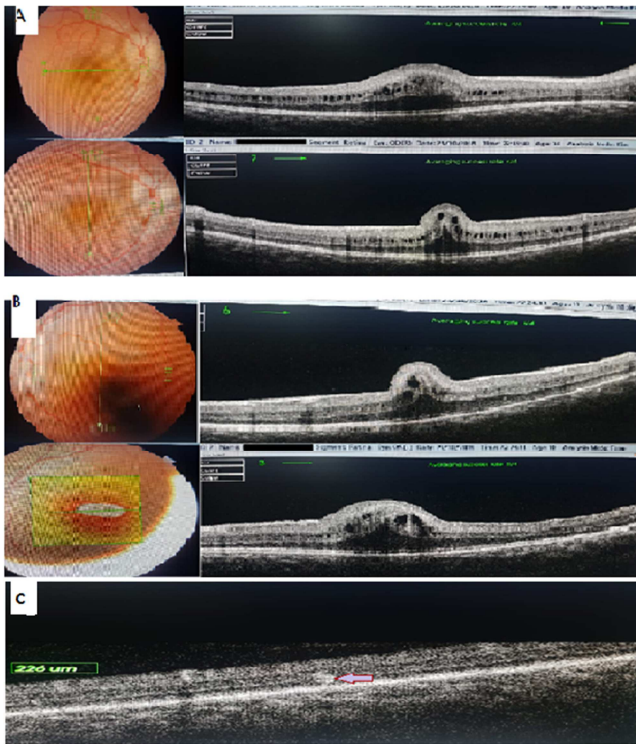
**Figure 2.** Fundus fluorescein angiography: showed peripapillary atrophy with small peripapillary formations impregnated at the intermediate sequences. White spots found in retinal periphery were impregnated with fluorescein (Arrows). In addition, it shows a reduction of the foveal avascular region in both eyes.

A and B scan ultrasonography revealed a reduced total axial length measured from the corneal apex to the back of the globe TAL= 15.7 mm (OD) / 15.5 mm (OS). The posterior segment lengths (PSL) from the back of the lens to the back of the globe, was also reduced to 8, 6 mm (OD) and 8, 5 mm (OG). However, the anterior segment length (ASL) from the cornea to the back of the lens was normal: 7.1 mm (OD) / 7.0 mm (OS). The diagnosis of posterior microphthalmia was retained.

Optical coherence tomography (OCT) analysis of the macula at the vertical scan line revealed retinoschisis and prominent retinal fold in the papillomacular region, including the neural retina, without involvement of the choroidal EPR band in both eyes (figure 3). An OCT section across a retinal white spot shows a hyper-reflective deposit in the subretinal space, pushing the line of the photoreceptors (figure 3).

Visual evoked potentials were requested in which a latency time was slightly high. The electroretinogram showed a very marked decrease in rod response and cone hypovoltage.

This association of posterior microphthalmia, papillary drusen, retinoschisis and retinal dystrophy, suggests the syndrome PM-retinitis pigmentosa-papillary drusen.



**Figure 3.** OCT macular of the right eye (A) and the left eye (B): Vertical line scan of macula revealed a retinal fold, including the neural retina, with retinoschisis in the both eyes; Horizontal line scan of macula shows a macular thickness with cystic edema in both eyes. (c): an OCT section across a retinal white spot shows a hyper-reflective deposit in the subretinal space, pushing the line of the photoreceptors.

### 3. Discussion

Microphthalmia was described by Boynton and Purnell in 1975 [1-4], it is defined by a globe with a total axial length (TAL) at least two standard deviations below the mean for age.

The term of posterior microphthalmia was introduced by Spitznas et al. [2] in 1983. It is a rare subset of microphthalmia in which the anterior segment of the eye is within normal dimensions but the posterior segment is foreshortened. The total axial length is thereby reduced. It is usually not associated to other ocular syndromes [5-6-7]

The pathogenesis of the disease is still controversial. Based on the current theory, the outer ocular coats, including retinal pigment epithelium (RPE), choroid, and sclera, lags behind in development, and as the sensory retina continues to grow normally, this disproportion may cause typical papillomacular retinal folds [4].

The transmission of this syndrome, according to the majority of authors [3-6-7] seems to be autosomal recessive mode with low penetrance and great expressiveness.

In the case that we introduced, the child was the only one of his family. His parents had had consanguineous marriage, they were not farsighted and their fundus was normal. This is an additional argument supporting the recessive autosomal mode of transmission.

The existence of high hyperopia (often more than 10

diopeters) is characteristic of this disease [2-9]. Visual acuity is usually diminished with profound amblyopia.

The existence of a papillo-macular fold is pathognomonic of posterior microphthalmia [3].

So, we should not hesitate to perform an ultrasonographic examination of eyes with normal appearance and high hyperopia, particularly in young children, to diagnose this syndrome as early as possible [10]. This Ocular ultrasound in A and B mode confirm the diagnosis by measuring the anterior and posterior segment.

In posterior microphthalmia, the anterior segment is normal, the axial length and the posterior segment is decreased, it is associated with sclerochoroidal thickening [4].

OCT is able to distinguish retinal folds from chorioretinal folds [4-7]. Coronal scan or C scan studies the extent, the shape, the orientation of the macular fold and also the vitreoretinal junction and detects the small lesions in the retinal layers. As we have seen in our clinical case, cystic spaces in the retinal tissue corresponding to retinoschisis.

In our case, we used OCT to study the papillomacular folds. It provides objective and accurate data. The longitudinal scan or B scan evaluates the importance of the retinal fold, the thickness of the retina and analyzes the foveal position related to the retinal fold [4-11]. OCT is finally, a non-invasive examination that can be repeated during microphthalmic to follow it —up later.

In fundus fluorescein angiography, the papillo-macular fold is not visible. It shows the absence of leakage and anomalies of the pigment epithelium in the macula [6]. In our case it shows the absence of papilledma.

Spitznas and al. [2] noted an association with the disappearance or marked reduction of the capillary-free central zone that we have found in our observation.

The image of autofluorescence shows, in our patient, papillary drusens and the presence of white spots in the middle retinal periphery.

Many other clinical associations with posterior microphthalmia have been reported by various authors. These include; retinoschisis, dialysis [7], esotropia, optic nerve hypoplasia [12], chorioretinal folds, uveal effusion syndrome, pigmentary retinopathy, retinitis punctata albescens, absent or marked reduction of the capillary - free zone [8] as we noticed in our case, Duane retraction syndrome [11] and iridocorneal anomaly. [12-13]

A new rare ophthalmic syndrome associating posterior microphthalmia, retinitis pigmentosa, foveoschisis and a papillary drusens has recently been reported by different authors [14-15].

It was first described by Drs. Buys and Pavlin [16] of the Toronto Hospital in 1999. These authors reported the case of a 68-year-old man presenting a table associating a nanophthalmic, retinitis pigmentosa and optic disk drusens, in addition to chronic angle glaucoma. After that, other cases of nanophthalmia in this context have been reported [17-18].

Zenteno and al (2006) [14] presented a Mexican family of 4, affected by these 3 changes and classified it, for the first time, as syndrome that associates posterior microphthalmia



with anteroposterior diameter between 13 and 18.5 mm, hyperopia beyond +8 D, papillary drusen, retinal dystrophy compatible with retinitis pigmentosa confirmed by electroretinogram and the presence of foveoschisis et / or foveolar thickening.

The same authors [15-19] suggested that a genetic defect in MFRP "OMIM 606227" (membrane-type frizzled related protein), located on chromosome 11q23 as being responsible for this syndrome.

Nisha Patel and al [17], using a multi-gene panel of new generation sequencing (i-panel) in their study in 2018 on a cohort of 147 patients in 93 families with various forms of microphthalmia, Found mutations PRSS56 and MFRP exclusively in patients diagnosed with posterior microphthalmia.

The white spots in the form of multiple round lesions [7] or albinoscent spots [7-11], are already been described in the context of posterior microphthalmos, but in these reported cases, retinoschisis and papillary drusen, are not mentioned.

Our patient had a posterior microphthalmia. The anteroposterior diameter was 15.7 mm (OD) / 15.5 mm (OS), with a hyperopia of +16 (OD), + 17 (OS). We found papillary drusen, foveoschisis, macular fold and white spots in retinal periphery associated to alteration of electroretinography.

It meets, therefore, the criteria mentioned above by Zenteno and al [14]. The feature of our patient is that he has white spots in the middle retinal periphery. These spots are localized in the subretinal space and have the characteristics of drusen. It is probably a particular form of retinal dystrophy.

Such a morphological association has only been reported once in the literature [20]. It constitutes thus, a new possible clinical variant of this syndrome.

In this variant, these spots, associated with retinal dystrophy, confirmed by electroretinogram, may be compatible with retinitis pigmentosa.

Careful examination at presentation and close follow up including correction of hyperopia and amblyopic therapy, are mandatory to improve or maintain visual function that may be compromised by the three components of this syndrome.

## 4. Conclusion

Posterior microphthalmia is a challenging diagnosis. Its timely diagnosis is critical to prevent the patient from the misdiagnosis of papilledema and thus unnecessary investigations.

OCT is a very useful advance that helps to see the macular fold and thus pose the diagnosis of posterior microphthalmia.

This posterior microphthalmia associated with retinitis pigmentosa, foveoschisis, and papillary drusen constitutes a new syndrome which is rare.

This case shows a new clinical variant of the posterior microphthalmia syndrome - papillary retinitis pigmentosa, described only once in the literature, characterized by the presence of retinal white spots. These spots, associated with retinal dystrophy, confirmed by electroretinogram, may be compatible with retinitis pigmentosa.

From this clinical description other studies may be realized to discover the new gene mutations related to this entity

## Conflict of Interest

All the authors do not have any possible conflicts of interest.

## References

- [1] Elder MJ. Aetiology of severe visual impairment and blindness in microphthalmos. *Br J Ophthalmol* 1994; 78: 332-4.
- [2] Spitznas M, Gerke E, Bateman VB. Hereditary posterior microphthalmos with papillomacular fold and high hyperopia. *Arch Ophthalmol* 1983; 101: 413-7.
- [3] Meire F, Leys M, Boghaert S, De Laey JJ. Posterior microphthalmos. *Bull Soc Belge Ophtalmol* 1989; 231: 101-6.
- [4] Boynton JR, Purnell EW. Bilateral microphthalmos without microcornea associated with unusual papillomacular retinal folds and high hyperopia. *Am J Ophthalmol* 1975; 79: 820-6.
- [5] Kida Y, Kurome H, Hayasaka S. Bilateral microphthalmos with poor visual acuity, high hyperopia, and papillomacular retinal folds in siblings. *Jpn J Ophthalmol* 1995; 39: 177-9.
- [6] Goldblum D, Mojon DS - Posterior microphthalmos associated with papillomacular fold and high hyperopia. *J Pediatric Ophthalmol Strabismus*, 1999; 36: 351-2.
- [7] Kim JW, Boes DA, Kinyoun JL - Optical coherence tomography of bilateral posterior microphthalmos with papillomacular fold and novel features of retinoschisis and dialysis. *Am J Ophthalmol*. 2004; 138(3): 480-1.
- [8] Khairallah M, Messaoud R, Zaouali S, Ben Yahia S, Ladjimi A, Jenzri S. Posterior segment changes associated with posterior microphthalmos. *Ophthalmology*. 2002; 109: 569-74.
- [9] Ryckewaert M, Zanlonghi X, Bertrand-Cuigner H, Constantinides G - High hyperopia with papillomacular fold. *Ophtalmologica*, 1992; 204: 49-53.
- [10] Nguyen AT, Johnson MA, Hutcheson KA. Good visual function in posterior microphthalmos. *J AAPOS* 2000; 4: 240-2. *Ophthalmology* Volume 109, Number 3, March 2002 574.
- [11] Tran HV, Borruat FX, R-Gruber S, Schorderet D, Munier F - Evanescent white linear flecks and posterior microphthalmos: new features of a recently established disease. *Klin Monatsbl Augenheilkd*. 2006; 223(5): 397-9.
- [12] Slotnick S, FitzGerald DE, Sherman J, Krumholz DM. Pervasive ocular anomalies in posterior microphthalmos. *Optometry*. 2007; 78.
- [13] Erdol H, Kola M, Turk A, Akyol N. Ultrasound biomicroscopy and OCT findings in posterior microphthalmos. *Eur J Ophthalmol*. 2008; 18: 479-82.
- [14] Ayala-Ramirez R, Graue-Wiechers F, Roberdo V, Amato-Almanza M, Horta-Diez I, Zenteno JC. A new autosomalrecessive syndrome consisting of posterior microphthalmos, retinitis pigmentosa, foveoschisis, and optic disc drusen is caused by a MFRP gene mutation. *Mol Vis*. 2006; 4: 1483-9.3.

- [15] Alberto Neri, 1 Rosachiara Leaci, 1 Juan C. Zenteno, 2, 3 Cristina Casubolo, 1 Elisabetta Delfini, 1 Claudio Macaluso1 Membrane frizzled-related protein gene-related ophthalmological syndrome: 30-month follow-up of a sporadic case and review of genotype-phenotype correlation in the literature . *Molecular Vision* 2012; 18: 2623-2632.
- [16] Buys YM, Pavlin CJ. Retinitis pigmentosa, nanophthalmos, and optic disc drusen: A case report. *Ophthalmology*. 1999; 106: 619–22.
- [17] Crespi J, Buil JA, Bassaganyas F, Vela-Segarra JI, Díaz-Cascajosa J, Ayala-Ramírez R, Zenteno JC. A novel mutation confirms MFRP as the gene causing the syndrome of nanophthalmos-retinitis pigmentosa-foveoschisis-optic disc drusen *Am J Ophthalmol*. 2015 Aug; 160(2): 401.
- [18] Juan Carlos Zenteno, Beatriz Buentello-Volante, Miguel A. Quiroz-González, and Miguel A. Quiroz-Reyes Compound heterozygosity for a novel and a recurrent MFRP gene mutation in a family with the nanophthalmos-retinitis pigmentosa complex . *Mol Vis*. 2009; 15: 1794–1798.
- [19] Patel, N., Khan, A. O., Alsahli, S., Abdel-Salam, G., Nowilaty, S. R., Mansour, A. M., Alkuraya, F. S. (2018). Genetic investigation of 93 families with microphthalmia or posterior microphthalmos. *Clinical Genetics*, 93(6), 1210–1222. doi:10.1111/cge.13239.
- [20] P. Plaza, O. Iturralde y C. Abascal. Síndrome del microftalmos posterior-drusas papilares-retinosis pigmentaria asociado a puntos blancos. Caso clínico. *Arch Soc Esp Oftalmol*. 2017. <http://dx.doi.org/10.1016/j.oftal.2017.01.003>.