

Case Report

Intestinal Type Adenocarcinoma from Inverted Papilloma

Rim Bechraoui*, Sana Mahfoudhi, Mohamed Dhaha, Azza Mediouni, Jihene Marrakchi, Houda Chahed, Mohamed Ben Amor, Najeh Beltaief, Rim Zainine, Ghazi Besbes

Department of Oto-Rhino-Laryngology and Cervico-Facial Surgery of 'Rabta' Hospital Tunisia, Medecine Faculty, El Manar University, Tunis, Tunisia

Email address:

rbechraoui@yahoo.fr (R. Bechraoui)

*Corresponding author

To cite this article:

Rim Bechraoui, Sana Mahfoudhi, Mohamed Dhaha, Azza Mediouni, Jihene Marrakchi, Houda Chahed, Mohamed Ben Amor, Najeh Beltaief, Rim Zainine, Ghazi Besbes. Intestinal Type Adenocarcinoma from Inverted Papilloma. *International Journal of Otorhinolaryngology*. Vol. 4, No. 1, 2018, pp. 13-15. doi: 10.11648/j.ijo.20180401.14

Received: December 1, 2017; Accepted: February 1, 2018; Published: March 19, 2018

Abstract: Sinonasal inverted papilloma is a rare benign tumor that accounts for 0.5-4% of all primitive nasosinus tumor. It has the potential to recur and exhibit malignant characteristics. Inverted papilloma recurring as adenocarcinoma is rare and even after exhaustive literature search only few cases could be found. The aim of the present study was to investigate the clinicopathological features and prognosis of intestinal type adenocarcinoma from inverted papilloma. We report a case of 54 old man who was operated two years ago from naso-sinus inverted papilloma. He presented after one year nasal blockage and nasal bleeding. Clinical exam found a naso-sinus tumor. He was operated and anatomopathological exam found an intestinal Adenocarcinoma type from inverted papilloma. A radiotherapy was indicated. The majority of inverted nasal papilloma are benign and treatment is complete local surgical removal. There is an associated real, but small risk of malignancy, which may coexist at the time of presentation or develop at a later time. Surgery plus postoperative radiotherapy was the predominant form of treatment.

Keywords: Inverted Papilloma, Tumor, Malignant, Surgery, Radiotherapy

1. Introduction

Sinonasal inverted papilloma (SNIP) is a rare benign tumor that accounts for 0.5-4% of all primitive nasosinus tumor [1, 2]. It has the potential to recur and exhibit malignant characteristics. Inverted papilloma (IP) recurring as adenocarcinoma is rare and even after exhaustive literature search only few cases could be found. The aim of the present study was to investigate the clinicopathological features and prognosis of intestinal type adenocarcinoma from IP.

2. Case Report

It was a 54 old man. He was operated two years ago by paralateronasal technic for a right sinonasal inverted papilloma. He consulted for right nasal blockage and nasal bleeding. A preoperative sinus computed tomography showed a collapsed maxillary sinus filled with soft irregular tissue mass

and destruction of osteomeatal complex (Figure 1).

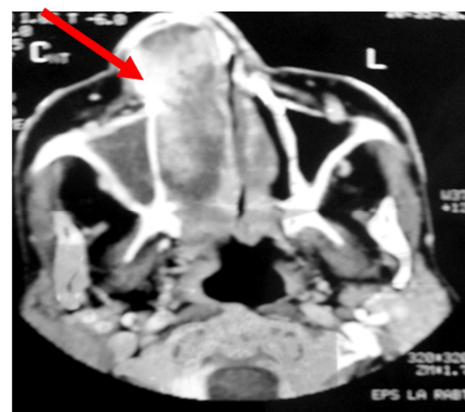


Figure 1. Computerized Tomography (CT) head and neck showing soft tissue mass (arrow) in naso maxillary sinus along with local bony destruction.

A brain magnetic resonance imaging was practiced and showed a nasal and maxillary tumor with hyposignal T1 and hyper signal T2 (Figures 2, 3).

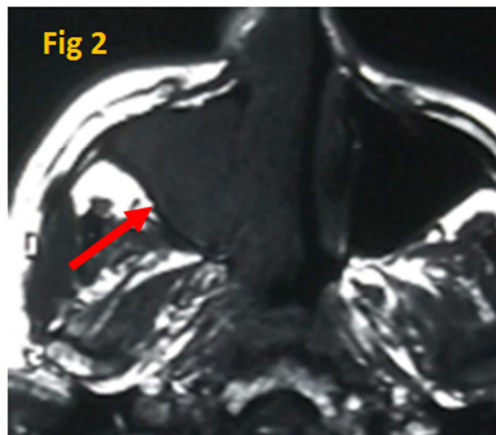


Figure 2. A brain magnetic resonance imaging showed a nasal and maxillary tumor with hyposignal T1.

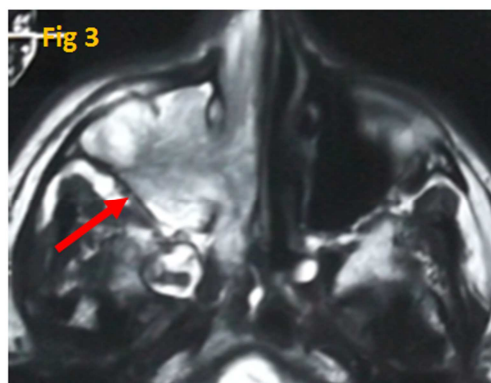


Figure 3. A brain magnetic resonance imaging showed a nasal and maxillary tumor with hyper signal T2

A tumor biopsy had concluded to an IP without malignant signs. The patient was operated, a paralateronasal technic, with resection of all the tumor on monobloc. The Histopathological analysis concluded to a naso-sinusal intestinal adenocarcinoma type from IP. Margins were positive and incomplete excision was suspected. Computed tomography abdomen revealed no abnormality. A postoperative radiotherapy was practiced. The evolution was favorable with no recurrences. The follow-up was three years.

3. Discussion

Currently, the specific mechanism underlying SNIP malignancy remain unclear [1]. From the perspective of pathogenesis, malignant nasosinusal inverted papillomas are borderline tumors, and they can undergo malignant transformation with disease progression [1, 2]. Most commonly, malignant nasosinusal inverted papilloma is associated with squamous cell carcinoma, followed by malignant adenocarcinoma, while small cell carcinoma is rare.

Squamous cell carcinoma that originates from the papilloma often has a high level of differentiation [1, 2]. Association of inverted papilloma with squamous cell carcinoma has been well documented in literature, but rarely adenocarcinoma or small cell carcinoma has been reported [3]. Incidence of squamous cell carcinoma associated with inverted papilloma is 5 to 15% in literature [3, 4]. Three studies have described occurrence of adenocarcinoma in existing inverted papilloma cases [3]. In the study of Kerschner, they reported a rare case of inverted papilloma associated with squamous cell carcinoma and adenocarcinoma [4]. There are two main ways in which SNIP may become malignant: The nasosinusal inverted papilloma and malignancy may occur in the same lesion, or the malignancy may occur in the site from which a nasosinusal inverted papilloma was previously resected [3]. Most commonly patient presents with nasal obstruction, epistaxis, rhinorrhea, mass in cheek and exophthalmos [3]. Sinus computed tomography scan and brain magnetic resonance imaging can show the range of tumor tissue types preoperatively, and may aid in the clinical classification of the tumor and the corresponding preoperative preparation [3, 5, 6]. Patients with Intestinal adenocarcinoma type from inverted papilloma should be fully examined to rule out any metastasis from gastro-intestinal or breast [3]. Preoperative biopsy is an ineffective method of identifying malignant of inverted papilloma [7, 8]. With the development of endoscopic surgical techniques for the treatment of malignant nasosinusal inverted papilloma, the traditional method of open surgical procedures has been replaced by minimally invasive endoscopic surgery or endoscopic-assisted surgery combined with radiotherapy [7, 8, 9]. Surgery associated with postoperative radiotherapy at the tumor site has been found to be the most effective treatment [7, 10, 11].

4. Conclusion

Sinonasal adenocarcinoma is a rare aggressive neoplasms with high mortality reported. The complete removal of the tumor, to ensure negative margins and facilitate thorough histological examination, supplemented with postoperative radiotherapy, can improve the prognosis of intestinal adenocarcinoma from inverted papilloma. Long term follow up is recommended because inverted papillomas are known to have recurrence as malignancy and not every time the transformation is into squamous cell carcinoma, but rarely into adenocarcinomas also.

References

- [1] Huan-Xin Yu, Gang Liu. Malignant transformation of sinonasal inverted papilloma: A retrospective analysis of 32 cases. *Oncol Lett.* 2014; 8(6): 2637-41.
- [2] Katori H, Nozawa A, Tsukuda M. Histopathological parameters of recurrence and malignant transformation in sinonasal inverted papilloma. *Acta Otolaryngol.* 2006;126:218-41.

- [3] Singh G, Singh M, Chandana M, Singh S, Nargotra N. Intestinal type adenocarcinoma from inverted papilloma: A rare recurrence. *J Clin Diagn Res.* 2016 Nov; 10(11):12-13.
- [4] Kerschner JE, Futran ND, Chaney V. Inverted papilloma associated with squamous cell carcinoma and adenocarcinoma: Case report and review of the literature. *Am J Otolaryngol.* 1996;17:257–59.
- [5] Mirza S, Bradley PJ, Acharya A. Sinonasal inverted papillomas: recurrence, and synchronous and metachronous malignancy. *J Larygol Otol.* 2007;121:857–64.
- [6] Von Buchwald C, Bradley PJ. Risks of malignancy in inverted papilloma of the nose and paranasal sinuses. *Curr Opin Otolaryngol Head Neck Surg.* 2007;15:95–98.
- [7] Lawson W, Kaufman MR, Biller HF. Treatment outcomes in the management of inverted papilloma: an analysis of 160 cases. *Laryngoscope.* 2003;113:1548–56.
- [8] Wang F, Yang Y, Wang S, Chen H, Wang D, Wang Q. Management of maxillary sinus inverted papilloma via endoscopic partial medial maxillectomy with an inferior turbinate reversing approach. *Eur Arch Otorhinolaryngol.* 2017; 274(12):4155-9.
- [9] Liang N, Huang Z, Liu H, Xian J, Huang Q, Zhou B. Bone involvement: Histopathological evidence for endoscopic management of sinonasal inverted papilloma. *Laryngoscope.* 2017;127(12):2703-8.
- [10] Leoncini G, Zanetti L. The papillomas of the sinonasal tract. A comprehensive review. *Pathologica.* 2017;109(1):31-4.
- [11] Sun Q, An L, Zheng J, Zhu D. Advances in recurrence and malignant transformation of sinonasal inverted papillomas. *Oncol Lett.* 2017;13(6):4585-92.