

Dermoid Cyst of the Anterior Fontanelle: A Case Report and Literature Review

**Sanou Abdoulaye¹, Ouattara Ousmane^{2,*}, Comboigo Somnéré Louis Junior³,
Sabourin Justo Luis Delis¹, Haro Yakouba¹, Zoungana Inoussa¹, Zabsonre Denléwendé Sylvain¹,
Kabre Abel¹**

¹Neurosurgery Department, Yalgado Ouedraogo Teaching Hospital, Joseph Ki Zerbo University, Ouagadougou, Burkina Faso

²Surgery Department, Souro Sanou Teaching Hospital, Nazi Boni University, Bobo Dioulasso, Burkina Faso

³Surgery Department, Regional Teaching Hospital of Ouahigouya, University of Ouahigouya, Ouahigouya, Burkina Faso

Email address:

sanou_abdou2002@yahoo.fr (Sanou Abdoulaye), ousman.watt@yahoo.fr (Ouattara Ousmane),

comboigoslouisjunior@gmail.com (Comboigo Somnéré Louis Junior), justoluisd@gmail.com (Sabourin Justo Luis Delis),

yaksterharo@gmail.com (Haro Yakouba), zoungranainous@gmail.com (Zoungana Inoussa),

szabsonre@gmail.com (Zabsonre Denléwendé Sylvain), kabrel@yahoo.fr (Kabre Abel)

*Corresponding author

To cite this article:

Sanou Abdoulaye, Ouattara Ousmane, Comboigo Somnéré Louis Junior, Sabourin Justo Luis Delis, Haro Yakouba, Zoungana Inoussa, Zabsonre Denléwendé Sylvain, Kabre Abel. Dermoid Cyst of the Anterior Fontanelle: A Case Report and Literature Review. *International Journal of Neurosurgery*. Vol. 6, No. 2, 2022, pp. 90-93. doi: 10.11648/j.ijn.20220602.20

Received: September 23, 2022; **Accepted:** October 11, 2022; **Published:** October 21, 2022

Abstract: Background: Dermoid cysts are benign congenital lesions that usually appear on the surface of the skull mainly at the anterior fontanelle. They develop from abnormal sequestration and inclusion of the surface ectoderm along the lines of skin fusion during embryologic development. They are rare lesions and characterized by the presence of hair follicles, sweat glands, and sebaceous glands. It is described predominantly in children. Besides physical evaluation, diagnostic imaging such as ultrasonography, computer tomography or magnetic resonance imaging are necessary to correctly analyse these lesions. Here, we report a case about dermoid cyst of the anterior fontanelle which was managed successfully by surgery. Case information: We describe a case of a 7-years-old male, who was admitted to the neurosurgery department of Yalgado Ouedraogo teaching Hospital for a scalp swelling evolving since birth. The swelling increased in size progressively but was not painful. Computed tomography of the head revealed extracranial cystic lesion over the bregma with no intracranial extension. Cyst was excised completely with no postoperative complications. On histopathology, it was dermoid cyst. Conclusion: Few cases of bregmatic dermoid cysts of the scalp have been reported in the literature. The present paper analyses a case of dermoid cyst of the anterior fontanelle in a child and reviews the available literature. It is important to remember that these lesions must be diagnosed and treated early by neurosurgeons in the view of varied differential diagnosis and to avoid more extensive surgeries.

Keywords: Dermoid Cyst, Anterior Fontanelle, Scalp, Neurosurgery

1. Introduction

Dermoid cysts are benign soft tissue tumors that develop from abnormal sequestration and inclusion of the surface ectoderm along the lines of skin fusion during embryologic development [1]. These cysts are rare lesions, with an incidence of 0.1-0.5% of cranial tumors located in the midline [2]. They can occur at various sites in the skull, but more often over the anterior fontanelle. In fact, 25% of them

are located in the anterior fontanelle and they are among the most common pediatric skull tumors [3]. Dermoid cysts are considered congenital lesions and they usually present in the first few months of life and then gradually enlarge due to internal desquamation and ultimately become symptomatic as a result of aggrandizement, rupture, and extension into surrounding structures [4, 5]. Computed tomography and/or magnetic resonance imaging are important for the preliminary diagnosis of these lesions and histopathology

examinations must establish the definitive diagnosis after surgical removal [2]. In this work, we report a case of dermoid cyst of the anterior fontanelle that was managed successfully by surgery and available literature is reviewed.

2. Case Presentation

A seven-year-old male with no significant past medical history presented to the Neurosurgery Department of Yalgado Ouedraogo Teaching Hospital with a scalp swelling over the anterior fontanelle since birth. The patient was born without complications. The swelling gradually increased in size and family decided to consult for aesthetic reasons. Physical examination showed a well-defined mass of 6 cm diameter, covered by undamaged skin located on the area of anterior fontanelle. It was soft consistency, fluctuant and negative for transillumination. The lesion was neither pulsating nor painful (figure 1).

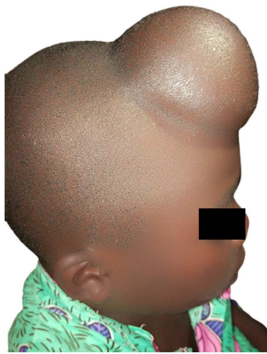

Figure 1. Overview of the patient with dermoid cyst of the anterior fontanelle.

The computed tomography (CT) demonstrated an extracranial, heterogeneous hypodense mass located over the anterior fontanelle, without intracranial extension (figure 2). The underlying bone was thin. There was no extension to the superior sagittal sinus and the anterior fontanelle was closed.

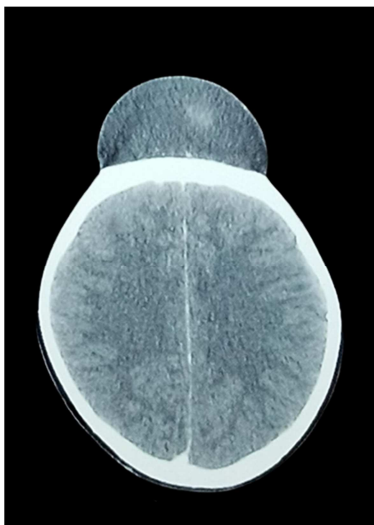


Figure 2. Computed tomography of the skull that confirms the extracranial position of the cyst without intracranial communication.

The patient underwent complete surgical excision of the scalp lesion under general anesthesia. Surgery consisted of a skin incision just above the cyst. Then, the cyst was dissected from the underlying tissue and removed completely with no complications. A skull depression underneath the lesion could be observed. Patient was discharged in stable state. The histological analysis showed the presence of keratin, hair follicles, sweat, and sebaceous glands delimited by a layer of stratified squamous epithelium (figure 3). Also, the fluid inside the cyst was yellow and pultaceous, basically composed of glucose and protein. Features were consistent with dermoid cyst. The child was doing well at follow-up. He recovered without complaints and very satisfied with the functional and aesthetical results.

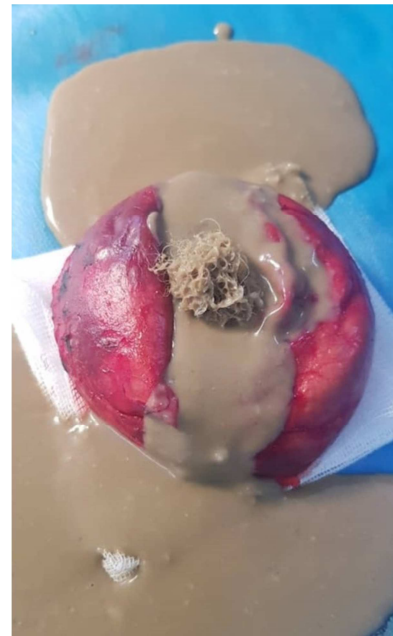

Figure 3. Detail of the lesion excision, that revealed a cyst containing pultaceous liquid with hair.

3. Discussion

Dermoid cysts are benign inclusion cysts, arising from dermal elements during ectodermal folding of the neural tube at the end of the 1st month of embryogenesis [1]. They are considered congenital lesions, but not all of them are diagnosed at birth. This reflects the natural history of dermoid cysts, which may lie dormant for a period of time and then grow and become symptomatic because of local mass effect, rupture, or even extension to surrounding structures and because of brain compression [3]. In fact, Dermoid cysts may slowly increase in size due to production of keratin and sebaceous material [6]. In their report, Orozco-Covarrubias *et al.*, showed an increase in size in 66% of patients with dermoids cysts, whereas 29% of cysts remained unchanged [4]. The delayed diagnosis in our case at 7 years old may be explained by the progressive enlargement of the cyst with aesthetic problems. In addition, the financial and geographical accessibility of neurosurgery centers could play

a major role in the delay in diagnosis because our country has few specialized centers in neurosurgery and the costs of health care are borne by the family.

On clinical examination, the patient had normal growth and development and no associated neurological or systemic abnormalities. This could be explained by the fact that the cyst was entirely extracranial and had no communication with the intracranial cavity. On paraclinic imaging, the patient underwent a computed tomography. This was the imaging exploration of choice in our context where Magnetic resonance imaging (MRI) was difficult to access. On computed tomography, the dermoid cyst is observed as a cystic well-defined mass, with an attenuation coefficient similar to soft tissues, and we can appreciate the separation between the intra and extracranial structures [2, 7]. Moreover, Cranium involvement and the state of the anterior fontanelle can be studied by CT. Indeed, dermoid cysts may enlarge and erode the cranium, thus being potentially susceptible of epidural extension. Finally CT can discuss the differential diagnosis of dermoids cyst. The most common differential diagnosis of these lesions, described in the literature, are epidermoid cyst, encephalocele, lipoma, cephalohematoma, hemangioma, and sinus pericranii [7, 8].

Magnetic resonance imaging is the best exam to describe the cyst, but it is not always necessary. The MRI may show a homogenous lesion, hypointense on T1-weighted, and hyperintense on T2-weighted images, without vascular structures [2, 3, 8]. Another interesting exam to study dermoid cyst of the scalp is Doppler ultrasound. Ultrasonography may show a subcutaneous hypoechogenic cystic lesion with absence of blood flow in the lesion [2]. It is more accessible than CT and MRI, but its ability to explore intracranial extension is limited.

The definitive diagnosis is made with histologic study. Histologically, dermoid cysts show a well-defined wall, lined by stratified squamous epithelium, and a lumen that can be filled with mature adnexal structures of mesodermal origin, such as hair follicles and shafts, sebaceous and eccrine glands [9]. These features differentiate dermoid cysts from epidermoid cysts, in which these structures are not present. In the scalp, epidermoid cysts are less frequent than dermoid tumors [10].

Treatment of dermoid cyst is essentially surgical. The fact that these cysts are benign lesions could suggest a conservative management with planned follow-up. But a more aggressive management with surgical excision has been advocated because cysts characteristically tend to enlarge with aesthetic problem and are able to erode the cranial bone with possible consequent epidural extension [3]. Another important advantage of surgical excision is the possibility of obtaining a histologic diagnosis because malignant tumors must be considered in the differential diagnosis of a solitary lump in the head of a child [2, 3]. Although rare, there have been reports of malignant transformation of scalp dermoid cysts [11, 12]. So, Early recognition and surgical management recommended to avoid this complication and prevent a more extensive surgery in the future [13]. The

recommended technique is generally blunt dissection of the tumor from the underlying tissues such as the dura mater or cranium through a curvilinear skin incision along the plane of the coronal suture [2-4]. Although it may seem simple, there are structures (superior longitudinal sinus for example) that we must take into account to avoid a poor outcome from our patient [2, 5]. In a child with open anterior fontanelle and proximity of the cyst to the sagittal suture, the capacity to extend intracranially or intradurally is high. In our case, the fontanelle was closed and the risk of lesion of superior longitudinal sinus was poor. Although recurrence after complete resection is rare, close follow - up is highly recommended. Some cases of recurrence have been reported in the literature [14].

An alternative to surgical treatment has been described in the literature. It is ethanol sclerotherapy. This treatment consist to aspire the content of the cyst and inject absolute ethanol in the cyst cavity. Sclerotherapy may not eradicate dermoid cysts, but has potential to decrease cyst size. It can be used for patients who cannot undergo operation for whatever reason, or as preoperative therapy to reduce the tumor volume [15].

4. Conclusion

Dermoid cysts are rare benign inclusion cysts which occur most frequently on the head. They must be diagnosed and treated early in view of the varied differential diagnosis, and to avoid more extensive surgeries and potential adverse effects related to lack of treatment. Prognosis is excellent and recurrence after excision is rare.

References

- [1] Ravi D. Bregmatic dermoid cyst in a patent anterior fontanelle. *J Neurosci Rural Pr.* 2013; 4 (1): 2–5.
- [2] Ponce-ayala A, Llano JPN De, Degollado-garcia J, Hernández-álvarez N. Anterior Fontanelle Dermoid Cyst : Surgical Technique. *Cureus.* 2021; 13 (7): 1–8.
- [3] Prior A, Anania P, Pacetti M, Secci F, Ravegnani M, Pavanello M, et al. Dermoid and Epidermoid Cysts of Scalp : Case Series of 234 Consecutive Patients. *World Neurosurg.* 2018; 120: 119–24.
- [4] Orozco-covarrubias L, Lara-carpio R, Saez-de-ocariz M, Duran-mckinster C, Palacios-lopez C, Ruiz-maldonado R. Dermoid Cysts : A Report of 75 Pediatric Patients. *Pediatr Dermatol.* 2013; 1–6.
- [5] Khalid S, Ruge J. Considerations in the management of congenital cranial dermoid cysts. *J Neurosurg Pediatr.* 2017; 21: 1–5.
- [6] Udina C, Calligaris L, Berti I, Cattaruzzi E, Barbi E. Inclusion cyst of anterior fontanelle. *Arch Dis Child.* 2018; 0: 1.
- [7] Aslan O, Aozveren F, Kotil K, Ozdemir B, Kuscuoglu U, Bilge T. Congenital Dermoid Cyst of the Anterior Fontanelle in Turkish Children. *Neurol Med Chir.* 2004; 44: 2003–5.

- [8] Alperin E, Boulouis G, Méary E, Legrand L, Mellerio C, Laouisset L, et al. Tumeurs de la voûte crânienne. EMC - Radiol Imag Méd. 2022; 14 (19): 1–22.
- [9] Reissis D, Pfaff MJ, Steinbacher DM. Craniofacial Dermoid Cysts : Histological Analysis and Inter-site Comparison. Yale J Biol Med. 2014; 87: 349–57.
- [10] Saadi A, Boutarfa A, Boualta K, Guenane L, Abdennebi B. kyste epidermoide congénitale de la fontanelle antérieure. J Neurochir. 2017; 25: 5.
- [11] Sinclair RD, Darley C, Dawber RPR. Congenital inclusion dermoid cysts of the scalp. Australas J Dermatol. 1992; 33: 135–40.
- [12] Yoon SH, Park S. A study of 77 cases of surgically excised scalp and skull masses in pediatric patients. Childs Nerv Syst. 2008; 24: 459–65.
- [13] Barnett RR, Elton SW. Masses of the Scalp and Skull in Children. Pediatr Clin N Am. 2021; 68 (4): 743–57.
- [14] Tanwir A, Malik N, Javed G, Idrees R. Dermoid cyst with no intracranial extension : A case report and literature review. Surg Neurol Int. 2019; 10: 25.
- [15] Takeshi K, Masato S, Hiroyuki N, Shunsuke Y. Cranial dermoid cyst with long-term development treated by ethanol sclerotherapy : a case report. Case Rep Plast Surg. 2020; 7 (1): 130–3.