

Lumber Disc Herniation - An Unusual Aetiology of Acute Painless Synchronous Foot Drop

Mohamed Awad Mohamed Hassan^{1,*}, Majed Saleh Alanazi², Amjad Abdulkader Ahmad Darwish³, Abdulhafeez Osman Eltoum Mohamed⁴, Salah Hani Sharif⁵, Saggaf Alawi Assaggaf⁶

¹Department of Neurosurgery, King Khalid Hospital, Hail, Kingdom of Saudi Arabia

²Rheumatology Unit, King Khalid Hospital, Hail, Kingdom of Saudi Arabia

³Neurosurgery Unit, King Fahad Military Medical Complex, Dhahran, Kingdom of Saudi Arabia

⁴Internal Medicine Department, King Khalid Hospital, Hail, Kingdom of Saudi Arabia

⁵Radiology Department, King Khalid Hospital, Hail, Kingdom of Saudi Arabia

⁶Neurosurgery Unit, King Khalid Hospital, Hail, Kingdom of Saudi Arabia

Email address:

mohawad25@yahoo.com (Mohamed Awad Mohamed Hassan), mhassan43@moh.gov.sa (Mohamed Awad Mohamed Hassan), dr.Maged2006@gmail.com (Maged Saleh Alanazi), dramjaddarwish@gmail.com (Amjad Abdulkader Ahmad Darwish), hafeezom@gmail.com (Abdulhafeez Osman Eltoum Mohamed), Drsalah_sherif84@yahoo.com (Salah Hani Sharif), s_assaggaf@hotmail.com (Saggaf Alawi Assaggaf)

*Corresponding author

To cite this article:

Mohamed Awad Mohamed Hassan, Majed Saleh Alanazi, Amjad Abdulkader Ahmad Darwish, Abdulhafeez Osman Eltoum Mohamed, Salah Hani Sharif, Saggaf Alawi Assaggaf. Lumber Disc Herniation - An Unusual Aetiology of Acute Painless Synchronous Foot Drop. *International Journal of Neurosurgery*. Vol. 6, No. 2, 2022, pp. 52-55. doi: 10.11648/j.ijjn.20220602.15

Received: September 11, 2022; **Accepted:** September 22, 2022; **Published:** September 29, 2022

Abstract: Background and importance: Acute bilateral painless foot drop is a common symptom of various diagnoses and consider a red flag sign for a serious pathology in the central or peripheral nervous system including cerebral, spinal, and peripheral causes. Therefore, medical history and careful clinical examination are often used in the neurotopographic classification. Acute painless bilateral Foot drop (FD) is an uncommon initial manifestation of nerve root compression secondary to acute lumbar disc herniation not associated with low back pain and radiculopathy. In most patients with lumbar disc herniation, FD is unilateral and is associated with low back pain and leg pain. Few cases have been described as bilateral FD, occurring simultaneously. Chronic bilateral foot drop as a sequela of systemic illnesses has been well-studied; however, acute painless bilateral foot drops not associated with radiculopathy or back pain in a healthy person should be immediately investigated, cauda equina syndrome is not necessarily to be associated with acute bilateral foot drop as shown in our case here. This study highlights the unusual presentation of lumbar disc prolapse and illustrates the importance of palsy duration, early diagnosis, and time to surgery as predicting factors for improvement. The author presents bilateral acute foot drop case associated with lumbar discopathy without back pain, radiculopathy, or cauda equina symptoms as an unusual initial manifestation of lumbar discopathy. The current study aimed to provide insight on the lumbar acute painless etiology of bilateral FD in a patient without radiculopathy and back pain to prevent functional loss. Moreover, it emphasized the rare initial manifestations of lumbar disc prolapse and the importance of predictive factors of improvement such as palsy duration, early diagnosis, and time to surgery. To illustrate work-up for bilateral foot drop in acute setting presentation. A systematic review was conducted using PubMed and google scholar. Demographic and radiological data were obtained from a painless acute bilateral foot drop presented to our neurosurgery unit. We reviewed the patient demographics, clinical presentation, radiological parameters, surgical parameters, and time from presentation to surgery. In addition, preoperative, early postoperative, and most recent follow-up neurological examinations were compared. Our patient improved gradually after the surgery, on the first postoperative day, we obtained an MMT (Manual Muscle Test) Scoring < 3 on admission, and third day postoperative MMT Scoring of 3. After six weeks, the last follow-up had an MMT Score of 5 for both ankles.

Keywords: Acute, Manual Muscle Test, Disc Prolapse, Bilateral Foot Drop, Neurotopographic Classification

1. Introduction

Bilateral foot drop (FD) is a manifestation of pathological conditions with various aetiologies ranging from systemic to local. It is defined as partial or complete foot and ankle dorsiflexion weakness. FD is caused by weakness of the tibialis anterior muscle, which is the primary dorsiflexor of the ankle joint that is controlled by the fibular nerve [1]. Previous studies have shown FD lesions occurring at the L4/5 level [2]. However, several electromyography studies have revealed that few nerve fibres from the L2, L3, S1 and S2 nerve roots supply the anterior tibialis muscle [3]. FD is caused by motor neuron pathologies in the lumbar spine or common peroneal nerve injury [4]. L5, L4, and S1 nerve root compression is commonly implicated in degenerative lumbar spine diseases causing FD [5]. Pain is the most significant symptom in patients with lumbar nerve root compression caused by degenerative diseases. Therefore, the cause of acute painless bilateral FD should be explained to the patient. In such a case, conservative treatment can lead to adhesion of the extruded nucleus pulposus to the dura and further development of arachnoiditis [6]. Hence, the whole disc material extrudes, percutaneous endoscopic disc removal or microdiscectomy, which is a less invasive procedure with few complications and has a short duration is preferred.

2. Case Presentation

A 49-year-old male vehicle driver without a history of chronic medical conditions or alcohol consumption presented to our hospital due to symptoms such as sudden bilateral FD and walking difficulties after sleep awakening. The patient denied any history of trauma, back pain or electricity-like pain in both lower limbs. He presented with mild numbness along the medial and lateral lower limbs below the knees along the

L4 and L5 root distribution, but not with sphincter disturbance. Three days prior to admission, he experienced mild numbness affecting both lower limbs below the knees. He then visited the medical health centre, and he was diagnosed with hyperlipidaemia. Next, 20 mg atorvastatin twice daily was prescribed. Lower limb examinations using MMT scoring revealed a power grade of 5/5 at both hips during flexion, extension, adduction, abduction, and internal and external rotation, without loss of sensations. The reflexes of both ankles were absent, and the Babinski sign was bilaterally equivocal with a power grade of 0/5 in dorsiflexion, 1/5 in inversion and 0/5 in eversion. However, both knees had normal reflexes. Table 1 show relevant laboratory data. Lumbosacral magnetic resonance imaging (Figure 1) revealed a broad-base posterior disc extrusion slightly to the left at the L4/5 level, with an upward migration of the disc material compressing both the lateral recess and nerve root more on the left side. Oedematous changes in the adjacent areas and decreased T2 signal intensity at the L4/5 levels were observed. The spinal lumbar canal, thecal sac and conus medullaris region were normal. The patient immediately underwent L4 laminectomy and disc removal, and the extruded disc material did not adhere to the dura or nerve root.

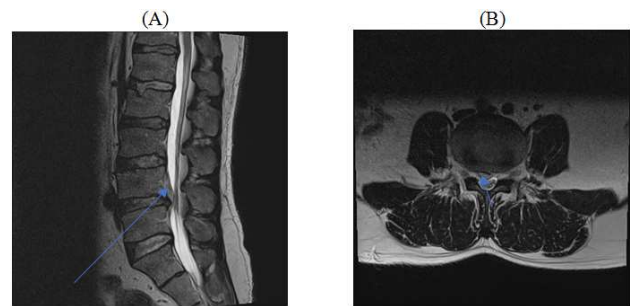


Figure 1. Lumbar spine MRI T2 sagittal (A) and axial (B) sequences.

Table 1. Laboratory data.

Blood test	Result	Reference range
Haemoglobin (Hb)	13.5 mg/dl	(13-18) mg/dl
Main corpuscular volume (MCV)	85 fl	(80-94) femtoliter
Main corpuscular haemoglobin (MCH)	29 Picogram	(27-31) picogram
Main corpuscular haemoglobin concentration (MCHC)	35%	(33-37)%
Urea	4.8 mmol/L	(2,7-8,07) mmol/L
Creatinine	90 Umol/L	(40-115) Umol/L
Uric acid	380 Umol/L	(202-416) Umol/L
Fasting blood glucose (FBG)	4,8 mmol/L	(4,2-6,1) mmol/L
Erythrocyte sedimentation rate (ESR)	7 MH/HR	(4-10) MH/HR
C-Reactive protein	2,0 mg/L	<8.0 mg/L
Vitamin B12	450 picogram/mL	Up to 1000 picogram/L
Serum Total Protein	73,5 gram/L	(66-87) gram/L
Serum albumin	39,4 gram/L	(35-55) gram/L
Serum cholesterol	6 mmol/L	(0-5,2) mmol/L
Serum triglyceride	1,9 mmol/L	(0-1,7) mmol/L
High density lipoprotein (HDL)	0,36 mmol/L	(0-1,68) mmol/L
Thyroid stimulating hormone (TSH)	1,18 IU/ml	(0,27-4,2) IU/ml

Pre-operative lumbar T2 MR sequences. LDH is seen at L4-L5 (A- blue arrow); a fragment is cranially migrated. On

the axial planes (B- blue arrow); an L4-L5 centrally located and slightly paracentral to left side LDH with foraminal

extension is seen with evidence of compression of the L5 lateral recesses bilaterally. The AP diameter of the spinal canal is 6mm (reduced) with Dural sac invagination, without evident signs of ligamentum flavum hypertrophy. Depth of the right lateral recess is 1,2mm, while depth of the left lateral recess is 1,0mm (both signifying stenosis).

3. Discussion

Acute painless bilateral FD without bowel/bladder involvement, radiculopathy or back pain is an extremely rare presentation of lumbar degenerative disorders. It can indicate different acute or progressive neurological and neurosurgical pathologies. Various systemic diseases, such as hypothyroidism [7] and diabetic peripheral neuropathy X [8], cause the gradual onset of bilateral FD. Furthermore, some studies have reported diseases affecting the neuromuscular junction, such as myasthenia gravis [9], or the muscles, including muscular dystrophy [10]. However, central nervous system aetiologies, such as anterior communicating artery aneurysm [11] and traumatic brain injury [12], have been occasionally identified. Majority of FD from lower motor neuron affection and can be due to radiculopathy or peripheral neuropathy which is more common [13]. Bilateral acute FD secondary to degenerative spinal disease is rare, with only six cases reported in the literature, all of which are associated with radiculopathy and back pain [14-17].

Previous studies have revealed that FD related to lumbar disc degeneration is often accompanied by low back pain or radicular pain [18]. Further, there is a high incidence of back pain and radicular pain associated with FD. However, a previous study showed that only 1 of 66 patients with lumbar degenerative disc disease experienced acute painless bilateral FD [19]. The same study analyzed 20 patients with painless FD related to lumbar disc degeneration.

Results showed that duration of palsy is a key prognostic factor of a successful surgery. However, in our case, the duration of palsy and time to surgery (within the first 24 h after admission) were short, and these factors might be associated with good surgical outcome, as represented by a Manual Muscle Test (MMT) score of >3 on the fifth postoperative day. Therefore, putting our current study in the context of previous relevant studies, rapid-onset spinal nerve root compression can lead to rapid deterioration of function rather than progressive compression. However, recovery is also rapid after early decompression surgery, as in our case here. As observed in our case, time to surgery in acute bilateral painless FD and duration of palsy are the main predicting factors of excellent recovery with an MMT Score 5 or >4, irrespective of the weakness degree on presentation. A flow chart illustrating a suggested critical neurological approach for bilateral acute painless synchronous foot drop presentation is shown in Figure [2]. According to our case study, we believe that, early surgical intervention as soon as possible is a key factor to prevent deterioration and enhance excellent recovery in patients without co-morbid chronic medical illnesses, and also it can minimize degree of damage

to nerve root in patients with concomitant co-morbidities, as nerve recovery can be influence by morbid diseases like diabetes mellitus and peripheral vascular diseases.

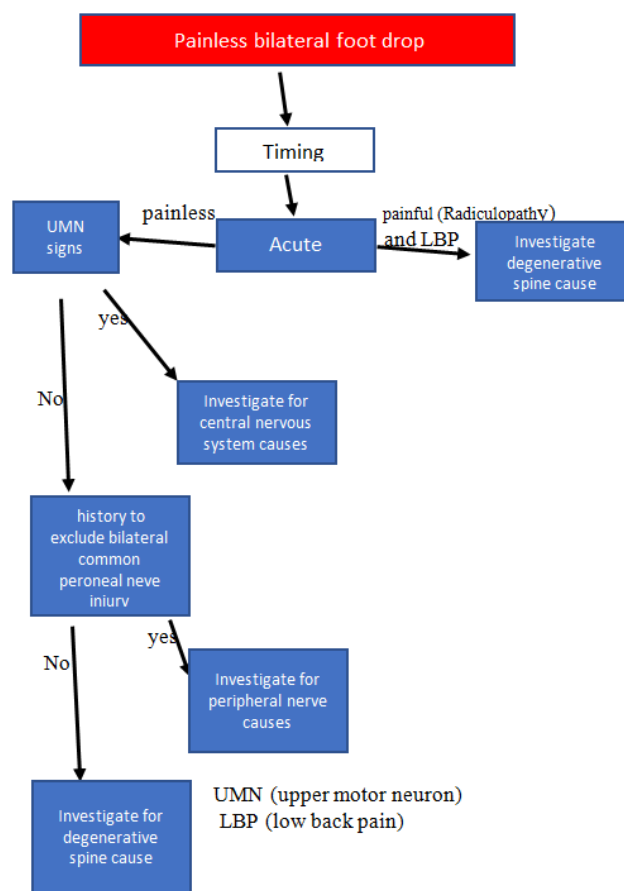


Figure 2. A flow chart illustrating a suggested critical neurological approach for bilateral acute painless synchronous foot drop without cauda equina presentation.

4. Conclusion and Next Step

Acute bilateral painless FD alone is a red flag sign for both intracranial and spinal pathology need prompt diagnoses and acute treatment. In the setting of lumbar discopathy, conservative management and delayed surgery can lead to decreased probability of improvement and poor prognosis. Therefore, early decompressive surgery in the first 24 h is crucial to excellent recovery. In next step, further studies are needed to investigate the absence of pain, radiculopathy, and cauda equina symptoms in such condition for further classification of lumbar discopathy.

Consent for Publication

A written informed consent was obtained for the publication of this study.

Conflict of Interest Statement

The authors declare that they have no competing interests.

Acknowledgements

On every out set of this report, I would like to extend my sincere and heart felt obligation toward the (EDC) educational development center at king Khalid hospital.

References

- [1] Liu, K., et al., 2013. Foot drop caused by lumbar degenerative disease: Clinical features, prognostic factors of surgical outcome and clinical stage. *PLoS One*, 8, e80375.
- [2] Aono, H., et al., 2007. Surgical outcome of drop foot caused by degenerative lumbar diseases. *Spine*, 13 (8), E262–E266.
- [3] Voermans, N. C., Koetsveld, A. C., and Zwarts, M. J., (2006). Segmental overlap: Foot drop in S1 radiculopathy. *Acta Neurochirurgica*, 148 (7), 809–813.
- [4] Baima, J. and Krivickas, L., 2008. Evaluation and treatment of peroneal neuropathy. *Current Reviews in Musculoskeletal Medicine*, 1 (2), 147–153.
- [5] McCulloch, J., and Waddell, G., 1980. Variation of the lumbosacral myotome with bony segmental anomalies. *Journal of Bone and Joint Surgery. (British Volume)*, 62 (7), 475–480.
- [6] French, Y. D., 1946. Clinical manifestation of lumbar spinal arachnoiditis: a report of 13 cases. *Surgery*, 20, 718–729.
- [7] Gately, R. P., Rashid, M. B., 2018. Hypothyroid myositis causing bilateral foot drop. *Radiology*, 289 (1), 28–28.
- [8] Shahani, B. and Spalding, J. M., 1969. Diabetes mellitus presenting with bilateral foot-drop. *The Lancet*, 294 (7627), 930–931.
- [9] Gilad, R. and Sadeh, M., 2000. Bilateral foot drop as a manifestation of myasthenia gravis. *Journal of Clinical Neuromuscular Disease*, 2 (1), 23.
- [10] Partanen, J., 1996. Anterior tibial dystrophy (late onset foot drop muscular dystrophy with rimmed vacuoles). *Neurologia i Neurochirurgia Polska*, 30, 77–80.
- [11] Sweid, A., et al., 2019. Case report of a partially thrombosed ACoA aneurysm presenting with bilateral foot drop. *Clinical Neurology and Neurosurgery*, 185, 105490.
- [12] Rispoli, R., et al., 2009. Bilateral acute foot drop in a case of axonal injury. A case report. *The Neuroradiology Journal*, 22 (2), 191–193.
- [13] Wang, Y. and Nataraj, A., 2014. Foot drop resulting from degenerative lumbar spinal diseases: clinical characteristics and prognosis. *Clinical Neurology and Neurosurgery*, 117, 33–39.
- [14] Adsul, N., et al., 2018. Acute bilateral isolated foot drop: changing the paradigm in management of degenerative spine surgery with percutaneous endoscopy. *World Neurosurgery*, 110, 319–322.
- [15] Gürer, B., et al., 2015. Acute bilateral isolated foot drop: report of two cases. *Asian Journal of Neurosurgery*, 10 (2), 123–125.
- [16] Mahapatra, A. K., et al., 2003. Sudden bilateral foot drop: an unusual presentation of lumbar disc prolapse. *Neurology India*, 51 (1), 71–72.
- [17] Marchesini, N., et al., 2020. Acute bilateral foot drop due to lumbar disc herniation treated by bilateral interlaminar approach: case report and literature review. *British Journal of Neurosurgery*, 1–3.
- [18] Giradi, F. P., et al., 2002. Improvement of preoperative foot drop after lumbar surgery. *Clinical Spine Surgery*, 15 (6), 490–494.
- [19] Aono, H., et al., 2014. Surgical outcomes for painless drop foot due to degenerative lumbar disorders. *Clinical Spine Surgery*, 27 (7), E258–E261.