

Preoperative Head CT Assisted Prediction of Acute Encephalocele During Isolated Acute Subdural Hematoma Surgery

Jiandong Wu[†], Gang Wu[†], Xiao-Yu Tang, Peng Deng, Jin-hong Qian, Zhi-Qi Cheng, Mian Ma^{*}

Department of Neurosurgery, Affiliated Suzhou Hospital of Nanjing Medical University (Suzhou Municipal Hospital), Suzhou, China

Email address:

343739595@qq.com (Mian Ma)

^{*}Corresponding author

[†] Jiandong Wu and Gang Wu are co-first authors.

To cite this article:

Jiandong Wu, Gang Wu, Xiao-Yu Tang, Peng Deng, Jin-hong Qian, Zhi-Qi Cheng, Mian Ma. Preoperative Head CT Assisted Prediction of Acute Encephalocele During Isolated Acute Subdural Hematoma Surgery. *International Journal of Neurosurgery*.

Vol. 5, No. 2, 2021, pp. 84-89. doi: 10.11648/j.ijjn.20210502.16

Received: October 8, 2021; **Accepted:** November 2, 2021; **Published:** November 17, 2021

Abstract: To investigate more predictors for acute encephalocele in patients during isolated acute subdural hematoma (ASDH) surgery by using clinical data combined with preoperative cranial computed tomography (CT) scan, so as to provide a basis for the development of a more scientific and reasonable treatment strategy. CT images and medical records of 46 patients who underwent neurosurgery for isolated traumatic acute subdural hematoma were collected. The patients with intra-operative acute encephalocele were grouped as the observation group (n=23), and the patients with no intra-operative acute encephalocele, whose age difference was within 5 years were included in the control group (n=23). The t-test and multivariate logistic regression analyses were carried out to evaluate the influence of clinical variables on acute encephalocele. Meanwhile, whether differences among Thickness of hematoma (TH), Midline shift (MLS), Hounsfield units of white matter (HU-WM), Hounsfield units of hematoma (HU-HT) and basal cistern effaced score (CES) measured by cranial CT could be used as predictors of outcomes in patients with acute encephalocele during subdural hematoma surgery was evaluated. There were no significant differences in age, sex, mechanism of injury, the time from trauma to decompression, and the MLS during surgery between the two groups. However, significant differences in preoperative Glasgow Coma Score (GCS), TH, HU-WM and HU-HT between the two groups were observed. The multivariate logistic regression analysis of radiographic data showed that HU-WM and CES were independent risk factors and strong predictors for intra-operative acute encephalocele. The areas under curve of CES and HU-WM were 0.8459 and 0.8336, respectively. The risk factors for acute encephalocele during ASDH operation are identified in this study. An increased risk of intra-operative acute encephalocele is found in patients with lower preoperative GCS, HU-WM, HU-HT and higher preoperative TH and CES, which should help clinicians to develop a more scientific treatment strategy and improve the survival of such kind of patients.

Keywords: Acute Subdural Hematoma, Intra-operative Acute Encephalocele, Hounsfield Units, White Matter

1. Introduction

Acute subdural hematoma (ASDH) is a serious traumatic disease, which develops after rupture of one or more bridging veins in most cases [1], and hematoma often enlarges via a positive feedback mechanism [2]. Many ASDH patients require emergent operation. Though trauma management systems and surgical techniques have improved, the overall mortality rate of ASDH is still around 22% to 41% [3], and it

may even increase to nearly 80% if the intra-operative acute encephalocele occurs to the patients. However, the etiology of intra-operative acute encephalocele after traumatic brain injury is multifactorial and poorly understood. There are few reports that correlate with the prediction effect of HU-WM and HU-HT combined with CES on intra-operative acute encephalocele in patients with head trauma. In this paper,

these risk factors for acute encephalocele occurring during surgery for ASDH were examined, in order to evaluate whether differences among HU-WM, HU-HT and CES measured by cranial CT can be used as predictors of acute encephalocele in patients with subdural hematoma. To predict the outcomes in patients with acute encephalocele is important because it can influence treatment strategy.

2. Materials and Method

2.1. Study Design

In this study, we retrospectively reviewed the medical records of 46 patients with isolated ASDH who underwent unilateral or bilateral decompressive craniectomy (DC) with standard large bone flap resection at the Affiliated Suzhou Hospital of Nanjing Medical University (Suzhou Municipal Hospital) between January 2014 and December 2019, and the intracranial pressure was released step by step with controlled

strategy. Twenty-three patients with intra-operative acute encephalocele were enrolled in the observation group, and patients 23 cases with no intra-operative acute encephalocele and the age difference within 5 years were assigned to the control group. The age difference was taken into consideration in this study because it influenced the density of WM. All patients surgeries were performed by the same surgeon team, followed up for 3 months and Glasgow Outcome Scale (GOS) was used to determine the outcomes. The risk factors including age, sex, mechanism of trauma, interval from trauma to decompression (h), GCS, TH, MLS, HU-WM, HU-HT, CES, and Glasgow Outcome Scale (GOS) were retrospectively analyzed and investigated (Table 1).

Inclusion criteria: aged 18-80; acute intracranial subdural hematoma; interval from trauma to decompression <24h.

Exclusion criteria: GCS=3; Contusion and laceration of brain; Preoperative obvious coagulopathy and blood diseases; hypotension; other organ injuries/fracture; poly-trauma.

Table 1. Clinical features and radiographic findings of patients undergoing surgery for ASDH.

Characteristic	Control group (N=23)	Observation group (N=23)	P value
Age, mean (SD), years	50.91±17.40)	49.22±19.17	0.75
Sex			
Female	8(34.78%)	10(43.48)	0.55
Male	15(65.22%)	13(56.52%)	
Mechanism of injury			
Motor accident			
Fall	12(52.17%)	11(47.23%)	
Assaults	7(30.43%)	8(34.78%)	
GCS	4(17.39%)	4(17.39%)	
≤6	8.26±2.05	5.26±1.10	
>6	5(21.74%)	19(82.61%)	<.0001
TH (mm)	18(78.26%)	4(17.39%)	<.0001
MLS(mm)	12.92±3.02	15.84±2.68	0.0012
HU-WM	9.48±3.51	11.73±5.35	0.0985
HU-HT	34.43±2.09	30.39±3.39	<0.0001
CES	57.26±9.49	48.00±10.35	0.0028
Interval from trauma to decompression (h)	7.74±3.12	11.09±1.50	<0.0001
≤3h			
>3h	11(47.83%)	17(73.91%)	0.0699
GOS	12(52.17%)	6(26.09%)	
1			
2-3	3(13.04%)	17(73.91%)	<.0001
4-5	6(26.09%)	6(26.09%)	
	14(56.00%)	0(8.70%)	

there were no significant differences in age, sex, mechanism of injury, the time from trauma to decompression and MLS during surgery between the two groups (all $P > 0.05$); significant differences in GCS, TH, HU-WM, HU-HT and CES were observed between the two groups (all $P < 0.05$)

2.2. Radiographic Data

CT images were obtained from Philips Brilliance and processed with SYNGO. PLAZA. CT system software (Siemens, Germany). The hematomas of all cases were located in the fronto-parietal and fronto-temporal regions. TH, MLS, HU-WM, HU-HT and CES were obtained from preoperative CT images.

According to Artru' standard [4], the evaluation of cisterns by the basal cistern effaced score (CES) focused on two scanning slices lying parallel to the cantho-meatal line, with one running through the perimesencephalic cistern at the level of the dorsum sellae, and the other running 10 mm above and showing the quadrigeminal cistern. We drew a centerline from

the frontal pole to the occipital pole and placed hallmarks at the quarter and halfway points separately to divide the centerline into three parts on each scanning slice. The radiologist then drew lines perpendicular to the centerline to the right and left of these two hallmarks and placed regions of interest (ROIs) (10 mm²) along these lines at 12mm inside the cranial bone or hematoma on either side. For each slice, we chose the double frontal lobes and the temporal lobe as four measurement points of the HU-WM, and avoided the area with increased white matter density caused by subarachnoid hemorrhage or hematoma. Meanwhile, we randomly selected six points to measure HU-HT (Figure 1).

We chose the hematoma slice with the maximum thickness,

and then recorded the thickness of hematoma (TH) and the distance of the midline shift (MLS). The MLS was defined as the displacement of the septum pellucidum in relation to the midline in millimeters [5].

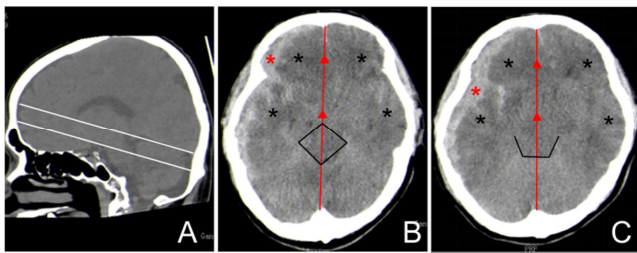


Figure 1. A-C basal cistern effaced score (CES): two scanning slices lying parallel to the cantho-meatal line, with one running through the perimesencephalic cistern at the level of the dorsum sellae, and the other running 10 mm above and showing the quadrigeminal cistern (white lines). Black line: Each segment was assigned a score: 0 = normal, 1 = compressed, 2 = absent. The total cistern effaced score ranged therefore from 0 (no effacement) to 14 (absent cistern). Black star: Points for the measurement for Hounsfield units of bilateral frontal and temporal lobe white matter; the area with increased white matter density caused by subarachnoid hemorrhage was avoided. Red star: Randomly selected points for the measurement of HU-HT. Red line: midline. Red triangle: the quarter and middle points.

2.3. Statistical Analysis

Two separate statistical analyses were performed with SAS software (version 9.3; SAS Institute). First, the risk factors for acute encephalocoele during subdural hematoma surgery were determined. The effects of individual variables including sex, age, decompressive time, and preoperative CT findings were analyzed by t-test. Subsequently, the univariate and multivariate logistic regression analysis was carried out to evaluate the influence of preoperative CT factors on the observation group patients who had acute brain bulge during craniotomy surgery. A P value of <0.05 was considered to be statistically significant.

3. Results

The characteristics of the two groups of patients (46) are shown in Table 1, from which it can be seen that there were no significant differences in age, sex, mechanism of injury, the time from trauma to decompression and MLS during surgery between the two groups (all $P > 0.05$); significant differences in GCS, TH, HU-WM, CES HU-HT and were observed between the two groups (all $P < 0.05$). The influences of HU-WM, HU-HT, and CES on patients in the observation group were evaluated using the multivariate logistic regression analysis (Table 2). The multivariate logistic regression analysis of radiographic data showed that HU-WM and CES were independent risk factors and strong predictors for intra-operative acute encephalocoele, and the areas under curve of CES and HU-WM were 0.85 and 0.83, respectively (Figure 2). In the control group the mortality was 13.04% (3/23), in the observation group the mortality was 73.91% (17/23).

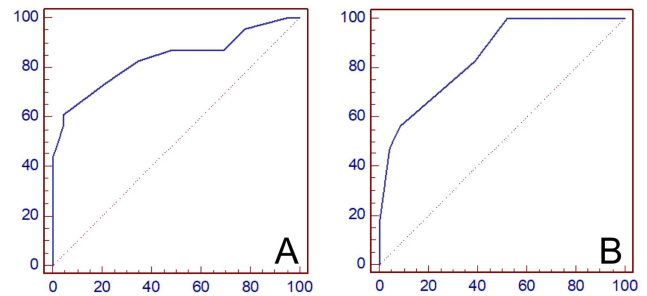


Figure 2. HU-WM and CES are independent risk factors for intra-operative acute encephalocoele. A: Area under curve of HU-WM (0.83) for predicting intra-operative acute encephalocoele. B: Area under curve of CES (0.85) for predicting intra-operative acute encephalocoele.

4. Discussion

Decompressive craniectomy (DC) is the main method for rapidly reducing intracranial pressure (ICP) in patients with ASDH [6], but acute encephalocoele often occurs suddenly during DC surgery, leading to higher mortality and morbidity, in this study, we can find the mortality rate of observation group 73.91% was higher than the control group 13.04%. Previous studies have suggested that delayed traumatic intracranial hematoma (DTIH), post-traumatic acute diffuse brain swelling (PADBS) and intracranial venous reflux disorder are the main factors affecting the acute encephalocoele during surgery [7]. In this paper, related preoperative clinical data and CT image information were used to assess the occurrence of intra-operative acute encephalocoele, so as to provide a basis for the development of a more scientific and reasonable treatment strategy for ASDH patients.

Previous reports [8-10] demonstrated that several predictors including midline shift, cistern effacement, subdural hematoma volume, and GCS are interrelated to patients' outcomes, and similar results were reached by our study. A series of pathophysiological changes occur during the period of the early brain injury, such as raised intracerebral pressure, reduced cerebral blood flow (CBF), blood-brain barrier (BBB) disruption, brain edema, acute vasospasm and dysfunction of autoregulation, and metabolic disturbances [11-13], which may be associated with intra-operative acute encephalocoele. The etiology of intra-operative acute encephalocoele is multifactorial and researches on the associated factors within a multiple-variable framework are urgently needed. This study is the first to assess acute encephalocoele caused by head trauma with subdural hematoma using HU-WM, HU-HT and CES measured by cranial CT.

In this study, it was found that there is no significant differences between the control and observation groups with MLS ($P > 0.05$), but significant differences between the control and observation groups with TH ($P < 0.05$). The TH and MLS were postulated as key determining factors governing the surgical decision. Most published data recommend immediate surgery for patients with a maximal TH exceeding 1 cm or 5 mm, or MLS over 0.5 cm, and those who have any signs of neurological deterioration [14]. However, when diffuse brain swelling and brain compliance reduced, only thickness of

hematoma or midline shift may not really reflect the intracranial pressure [15].

This study is the first to assess encephalocele caused by head trauma with subdural hematoma using HU-WM, HU-HT and CES measured by cranial CT. Both vasogenic and cytotoxic components contribute to ASDH-related brain edema [16]. The new research showed that cerebrospinal fluid influx drove acute ischemic tissue swelling in of middle cerebral artery occlusion model in mice [17], but whether it also aggravates the brain edema in TBI remains unknown. The HU value was closely related to the severity of brain edema in the immediate period after acute subdural hematoma. HU decrease appeared in low-density areas on CT images due to excess water accumulated [18], and there was difference in the HU-WM level between the injured side and non-injured side [19]. The more severe edema is associated with a lower HU-WM. Reduced preoperative HU-WM in some areas obviously suggests potential brain contusion, and a rapidly decreasing intracranial pressure after DC can lead to the delayed intracranial hemorrhage of the areas, resulting in intra-operative acute encephalocele. In this study, HU values measured at the initial CT were used to assess whether they were strong predictors of intra-operative acute encephalocele.

In the study, There were significant differences between the control and observation groups with respect to the HU-WM, HU-HT, and CES were found ($P < 0.05$), meant that the decreased HU-WM, mixed density hematoma combined with high CES could be used predictors for intra-operative acute encephalocele.

Table 2. Multivariate Logistic regression analysis of the association between risk factors.

factors	Rude OR 95%CI	P value	Adjusted OR 95%CI	P value
CES	0.397(0.219-0.720)	0.0023	0.100(0.011-0.918)	0.0418
HU-WM	1.643(1.228-2.197)	0.0008	2.900(1.029-8.171)	0.0440
HU-HT	1.098(1.026-1.176)	0.0071	1.244(0.986-1.569)	0.0651
TH	0.664(0.497-0.888)	0.0058	0.439(0.147-1.309)	0.1399
MLS	0.893(0.779-1.023)	0.1029	0.790(0.470-1.326)	0.3721

HU-WM and CES were independent risk factors and strong predictors for intra-operative acute encephalocele, and the areas under curve of CES and HU-WM were 0.85 and 0.83, respectively.

The multivariate logistic regression analysis revealed that HU-WM and CES were independent risk factors for intra-operative acute encephalocele (Table 2). The mean HU-WM level was 34.43 ± 2.09 in the control group and 30.39 ± 3.39 in the observation group. The area under curve of HU-WM for predicting intra-operative acute encephalocele was 0.8336. When injury time was more than 3 hours, HU-WM was highly sensitive. The mean CES was 7.74 ± 3.12 in the control group and 11.09 ± 1.50 in the observation group. The area under curve of CES for predicting intra-operative acute encephalocele was 0.85. CES was correlated linearly with the maximal ICP, and the higher the scores, the more serious the brain stem injury was. The quick decrease of intracranial pressure led to vasodilation, but the cerebrovascular autoregulation dysregulation caused severe

secondary brain damage [20]. Basal cisterns compressed or absent prompted compression or absence of brain veins at the same time, which brought about venous reflux obstacle. Compared with insufficient cerebral arterial supply (arterial ischemia), cerebral venous drainage impairment with venous hypertension caused more severe vasogenic edema and brain-blood barrier damage. These factors led to acute encephalocele.

The HU-HT was found not to be a strong risk factor for intra-operative acute encephalocele by the multivariate logistic regression analysis in this study, and the reason we thought was related to the small sample size. However, the differences between the observation group (48.00 ± 10.35) and control group (57.26 ± 9.49) were significant ($P < 0.05$). Recently, the imaging marker for hematoma growth has been identified on computed tomographic angiography (CTA), CTA leakage sign may predict hematoma growth and is associated with poor functional outcomes [21], and the blend sign on Computed Tomography is highly specific for predicting hematoma growth in intracerebral hemorrhage patients [22]. Similarly, preoperative most of the observation patients had mixed density of hematoma, we found hematoma volume increased significantly during the operation compared with preoperative CT image. Therefore, we concluded that HU-HT decrease was a predictor for early hematoma growth in patients with ASDH, meaning that patients' conditions would get worse and surgery should be performed timely.

A standardized surgical approach that was modeled by using Rubiano AM et al.'s technique [23] was used. In our study, 12 case in the observation group received standard unilateral DC but all were dead, and 11 cases received bilateral DC, among whom 5 patients were dead, 3 patients had severe disability and 3 patients were vegetable survival. So we suggest when the lesion side has high intracranial pressure and brain swelling during an unilateral DC surgery, it is suggested that the contralateral bone flap should be removed and the bilateral dura mater should be opened immediately at the same time, and intracranial pressure should be released step by step with controlled strategy on the premise that the patient's vital signs are stable.

This study demonstrated the beneficial prognostic value of HU-WM and CES, which were independent risk factors and could be used as predictors of acute encephalocele in patients during subdural hematoma surgery. In addition to routine clinical data, we could also get information from the preoperative CT data. Patients with lower GCS, HU-WM, HU-HT and higher TH, CES were highly suspected of acute encephalocele. When malignant acute encephalocele occurring in unilateral DC surgery can result in axon tensile and further cause brain stem injury, so we suggested to take bilateral decompression treatment strategies and slowly release intracranial pressure simultaneously for highly suspected acute encephalocele patients. In some patients with severe traumatic brain injury, DC is controversial, because sometimes it reduces early mortality but increases survival in patients with severe disability [24]. In particular, it may bring about worse outcomes than conservative treatment if these patients are old [25] or combined with primary brain stem

injury and have unstable vital signs, so preoperative evaluation is very important.

Our study had some limitations. First, Intra-operative acute encephalocele is a common result of multiple factors, in our study, we only focus on finding out more auxiliary information in preoperative CT imaging. Second we chose 23 patients with no intra-operative acute encephalocele and the age difference within 5 years were assigned to the control group, The age difference was taken into consideration in this study because it influenced the density of WM, meanwhile the other factors maybe not a better match. Third, the clinical data is limited, we still need to further expand the sample size.

5. Conclusion

ASDH is a fatal condition despite all developments in neurosurgical interventions, and acute encephalocele is an unusual condition with extremely high mortality. The analysis of this paper suggests that different degrees of preoperative GCS, TH, HU-WM, HU-HT, and CES play important predictive roles in the intra-operative acute encephalocele. We provided a simple and practical method to assess the occurrence of intra-operative acute encephalocele by used related preoperative clinical data and CT image information and provide a basis for the development of a more scientific and reasonable treatment strategy.

Abbreviations

ASDH=Acute subdural hematoma
 ABS= acute brain swelling
 BBB= Blood-brain barrier
 CBF =Cerebral blood flow
 CES= cistern effaced score
 CT=computed tomographic
 DC= Decompressive Craniectomy
 DTIH=delayed traumatic intracranial hematoma
 HT= Hematoma
 HU= Hounsfield units
 HU-HT=Hounsfield units of Hematoma,
 HU-WM=Hounsfield units of white matter
 ICP =intracranial pressure
 GCS=Glasgow Coma Score
 GOS=Glasgow Outcome Scale
 MLS=Midline shift
 PADBS= post-traumatic acute diffuse brain swelling
 TH=Thickness of hematoma
 WM =White matter

Conflicts of Interest Disclosure

The authors have no personal financial or institutional interest in any of the drugs, materials, or devices in the article.

Funding

This work was supported by Suzhou Youth Science and

technology project (KJXW2017029); Nanjing Medical University Bonus (NMUB2019328).

References

- [1] Nagahiro S, Mizobuchi Y. Current topics in sports-related head injuries: a review. *Neurol Med Chir (Tokyo)* 54: 878-886, 2014.
- [2] Miller JD, Nader R. Acute subdural hematoma from bridging vein rupture: a potential mechanism for growth. *Journal of neurosurgery* 120:1378-1384, 2014.
- [3] Bartek J, Jr., Laugesen C, Mirza S, Forsse A, Petersen MA, Corell A, et al. Scandinavian Multicenter Acute Subdural Hematoma (SMASH) Study: Study Protocol for a Multinational Population-Based Consecutive Cohort. *Neurosurgery* 84: 799-803, 2019.
- [4] Artru F JC, Convert J, Duquesnel J, Deleuze R, et al. An Effacement Score for Basal Cisterns to Predict ICP Level and Outcome After Severe Closed Head Injury. *Intracranial Pressure VII Springer, Berlin, Heidelberg* 603-604, 1989.
- [5] Bartels RH, Meijer FJ, van der Hoeven H, Edwards M, Prokop M. Midline shift in relation to thickness of traumatic acute subdural hematoma predicts mortality. *BMC neurology* 15: 220, 2015.
- [6] Shen J, Fan Z, Ji T, Pan J, Zhou Y, Zhan R. Contralateral acute subdural hematoma following traumatic acute subdural hematoma evacuation. *Neurol Med Chir (Tokyo)* 53: 221-224, 2013.
- [7] Arslan E, Arslan S, Kalkisim S, Arslan A, Kuzeyli K. Long-Term Results of Orbital Roof Repair with Titanium Mesh in a Case of Traumatic Intraorbital Encephalocele: A Case Report and Review of Literature. *Craniomaxillofacial trauma & reconstruction* 9:255-259, 2016.
- [8] Leitgeb J, Mauritz W, Brazinova A, Janciak I, Majdan M, Wilbacher I, et al. Outcome after severe brain trauma due to acute subdural hematoma. *Journal of neurosurgery* 117: 324-333, 2012.
- [9] Zumkeller M, Behrmann R, Heissler HE, Dietz H. Computed tomographic criteria and survival rate for patients with acute subdural hematoma. *Neurosurgery* 39 (4): 708-12, 1996.
- [10] Yanaka K, Kamezaki T, Yamada T, Takano S, Meguro K, Nose T. Acute subdural hematoma--prediction of outcome with a linear discriminant function. *Neurol Med Chir (Tokyo)* 33: 552-558, 1993.
- [11] Wang Z, Guo S, Wang J, Shen Y, Zhang J, Wu Q. Nrf2/HO-1 mediates the neuroprotective effect of mangiferin on early brain injury after subarachnoid hemorrhage by attenuating mitochondria-related apoptosis and neuroinflammation. *Scientific reports* 7: 11883, 2017.
- [12] Diedler J, Sykora M, Hahn P, Heerlein K, Scholzke MN, Kellert L, et al. Low hemoglobin is associated with poor functional outcome after non-traumatic, supratentorial intracerebral hemorrhage. *Critical care* 14: 63, 2010.
- [13] Karibe H, Hayashi T, Hirano T, Kameyama M, Nakagawa A, Tominaga T. Surgical management of traumatic acute subdural hematoma in adults: a review. *Neurol Med Chir (Tokyo)* 54: 887-894, 2014.

- [14] Phan K, Moore JM, Griessenauer C, Dmytriw AA, Scherman DB, Sheik-Ali S, et al. Craniotomy Versus Decompressive Craniectomy for Acute Subdural Hematoma: Systematic Review and Meta-Analysis. *World neurosurgery* 101: 677-685, 2017.
- [15] Moussa WMM, Khedr WM, Elwany AH. Prognostic significance of hematoma thickness to midline shift ratio in patients with acute intracranial subdural hematoma: a retrospective study. *Neurosurgical review* 41: 483-488, 2018.
- [16] Jayakumar AR, Taherian M, Panickar KS, Shamaladevi N, Rodriguez ME, Price BG, et al. Differential Response of Neural Cells to Trauma-Induced Swelling In Vitro. *Neurochemical research* 43: 397-406, 2018.
- [17] Mestre H, Du T, Sweeney AM, Liu G, Samson AJ, Peng W, et al. Cerebrospinal fluid influx drives acute ischemic tissue swelling. *Science* 367: 6483, 2020.
- [18] von Holst H, Li X, Kleiven S. Increased strain levels and water content in brain tissue after decompressive craniotomy. *Acta neurochirurgica* 154: 1583-1593, 2012.
- [19] Yamamura H, Morioka T, Yamamoto T, Mizobata Y. Head computed tomographic measurement as a predictor of outcome in patients with subdural hematoma with cerebral edema. *Scandinavian journal of trauma, resuscitation and emergency medicine* 24: 83, 2016.
- [20] Saito T, Kushi H, Makino K, Hayashi N. The risk factors for the occurrence of acute brain swelling in acute subdural hematoma. *Acta neurochirurgica Supplement* 86: 351-354, 2003.
- [21] Yamamoto M, Orito K, Nakamura Y, Takeshige N, Yoshitomi M, Takeuchi Y, et al. Leakage sign for acute subdural hematoma in clinical treatment. *Acta neurochirurgica* 161: 233-238, 2019.
- [22] Li Q, Zhang G, Huang YJ, Dong MX, Lv FJ, Wei X, et al. Blend Sign on Computed Tomography: Novel and Reliable Predictor for Early Hematoma Growth in Patients With Intracerebral Hemorrhage. *Stroke* 46: 2119-2123, 2015.
- [23] Rubiano AM, Carney N, Khan AA, Ammirati M. The Role of Decompressive Craniectomy in the Context of Severe Traumatic Brain Injury: Summary of Results and Analysis of the Confidence Level of Conclusions From Systematic Reviews and Meta-Analyses. *Frontiers in neurology* 10: 1063, 2019.
- [24] Honeybul S. Decompressive craniectomy for severe traumatic brain injury reduces mortality but increases survival with severe disability. *Evidence-based medicine* 22: 61, 2017.
- [25] Akbik OS, Starling RV, Gahramanov S, Zhu Y, Lewis J. Mortality and Functional Outcome in Surgically Evacuated Acute Subdural Hematoma in Elderly Patients. *World neurosurgery* 126: 1235-1241, 2019.