

Bone and Intramuscular Hydatid Cysts: A Rare Association

Meriam Benzalim*, Meryem Ranib, Soumaya Alj

Radiology Department, Faculty of Medicine and Pharmacy, Ibn Tofail Hospital, Mohamed VIth University Hospital, Cadi Ayyad University, Marrakech, Morocco

Email address:

meriam.benzalim@gmail.com (M. Benzalim), meryem.ranib@gmail.com (M. Ranib), soumayaalj@hotmail.com (S. Alj)

*Corresponding author

To cite this article:

Meriam Benzalim, Meryem Ranib, Soumaya Alj. Bone and Intramuscular Hydatid Cysts: A Rare Association. *International Journal of Medical Imaging*. Vol. 10, No. 1, 2022, pp. 1-4. doi: 10.11648/j.ijmi.20221001.11

Received: December 31, 2021; **Accepted:** January 24, 2022; **Published:** February 9, 2022

Abstract: *Background:* Hydatidosis is a parasitic disease linked to the development of Echinococcus Granulosus larval form in humans. This anthroponosis is characterized by many topographical and evolutionary aspects. Musculoskeletal hydatidosis is rare, it represents only 0.9 to 2.5% of all locations. *Objective:* the aim of this manuscript is to report a rare case of bone and muscle location of hydatid cyst and show the imaging contribution in its positive diagnosis and pre-therapeutic assessment. *Method:* We report the observation of a 61-year-old man admitted to our training for a right thigh mass, revealing a muscular hydatid cyst with a concomitant iliac bone location. *Result:* Ultrasound examination shows an intra muscular cystic lesion, of the Sartorius and rectus femoris muscles, with hydatid membranes inside. A simultaneous bone location, at the ipsilateral iliac bone, was fortuitously discovered on CT scan and MRI exploration, which show a multicystic lytic lesion with cystic signal and round daughter cysts on MRI examination. A complementary X-ray of the pelvis shows the classic "honeycomb" appearance of the right iliac bone. A positive hydatid serology confirmed the diagnosis. No concomitant hepatic or pulmonary localization was demonstrated on abdominal ultrasound and chest CT scan. An anthelmintic therapy (Albendazole) was started, and the patient was a candidate for further surgical treatment. *Conclusion:* Musculoskeletal hydatid cyst location is rare. The Hydatid osteopathy is usually infiltrative, slow and progressive, which makes diagnosis late and compromises the quality of treatment. So, despite its rarity; musculoskeletal hydatid cyst should always be considered in the differential diagnosis of cystic lesions in endemic areas.

Keywords: Bone Cyst, Hydatid Disease, Muscle

1. Introduction

Hydatidosis is a zoonotic disease. It is an endemic in many countries of the world including the Mediterranean region. Human infection is accidental. It occurs either through direct ingestion of parasite eggs from contact with infected dogs or indirectly from the ingestion of contaminated water or food. Hepatic and pulmonary localizations are the most frequent, while the involvement of the musculoskeletal system is extremely rare [1, 2]. Bone hydatidosis represents 3% of locations [3]. The vertebrae are most commonly affected, in 40–50%. Involvement of the iliac bone represents only 15 % of all bony hydatid cases [4]. However, muscles are rarely infected, for approximately less than 1% of cases. Isolated intramuscular hydatid cyst, without any location in liver or lungs, are extremely scarce. Only few studies report about a higher number

of cases [5]. Patients with musculoskeletal hydatid disease often present with symptoms only once the disease process is advanced. The diagnosis is usually challenging. Management in bony hydatid disease is difficult, often limited to the use of anthelmintic therapy with surgical intervention [6]. We report a rare case associating a primitive bone and intramuscular hydatid cyst in a 61-year-old man, to illustrate imaging contribution to diagnosis and pre therapeutic assessment.

2. Observation

A 61-year-old man was admitted to Mohamed VI university hospital for a voluminous painful mass in the lateral region of the right thigh. The mass had started developing four years ago. The patient's clinical history was unremarkable. The clinical examination shows an anterolateral renitent mass of the thigh, measuring

approximately 30 cm length. No tenderness, overlying skin changes or fistulas were noted. General examination was without abnormality. The patient was afebrile with an estimated temperature of 36.8°C. The mass Ultrasound

exploration showed an intramuscular encapsulated hypoechoic cystic lesion, containing serpiginous hydatid membranes, with smooth regular wall (figure 1).

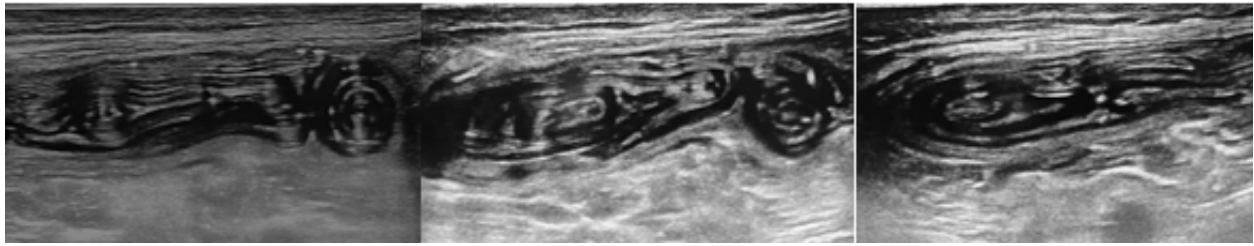


Figure 1. Ultrasound images with high frequency probe (11 - 16 MHz), showing intramuscular cysts, containing serpiginous hydatid membranes.

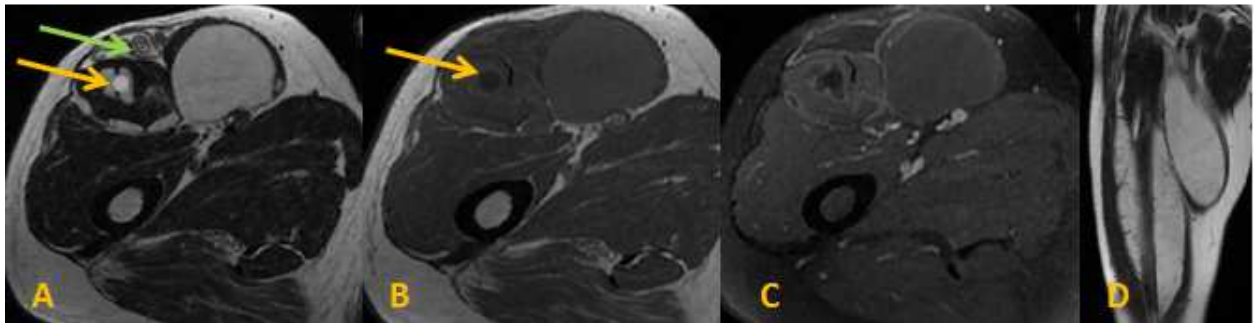


Figure 2. MRI imaging on T2 weighted ponderation (A, D), T1 weighted ponderation (B) and on injected T1 FAT SAT weighted ponderation (C), showing the intramuscular cystic lesion, no-enhanced after gadolinium administration, with daughter cyst (yellow arrow) and hydatid membrane (green arrow).

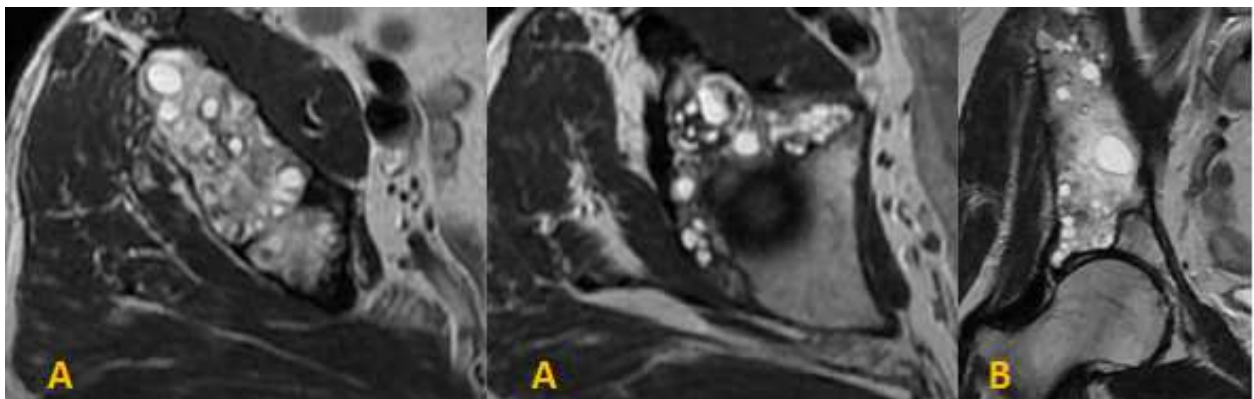


Figure 3. MRI imaging on T2 weighted ponderation (axial sections A and coronal section B), showing a multi locular cystic lesion of the right iliac bone.

An MRI of the thigh was requested, showing two intramuscular multicystic lesions, involving the Sartorius and rectus femoris muscles. These cystic masses contained round daughter cysts, and were characterized by a low signal intensity in T1-weighted scans, a high signal intensity in T2-weighted scans, and no enhanced after gadolinium administration. They contain a low signal intensity membranes in T1 and T2 weighted ponderation (figure 2). These cystic lesions were large, measuring 27 cm and 30 cm long. A third cystic lesion, separate from the first two cysts, was incidentally discovered in the right iliac wing. This lesion is multi-loculated, hypo intense on T1 weighted ponderation, hyper intense on T2 and STIR weighted ponderation, not enhanced after gadolinium intravenous administration, unambiguously suspicious of

echinococcosis (figure 3). It is responsible for a blister with rupture of the cortical bone, acetabulum involvement and infiltration of the gluteus minimus muscle.

A standard X-ray of the pelvis in frontal view was supplemented, showing poorly limited areolar lytic images, achieving the classic "honeycomb" appearance. There is no periosteal reaction or regional calcifications (figure 4).

Since the MRI results were suggestive of hydatid cyst, further imaging examinations; abdominal ultrasonography and chest computed tomography scan, were carried out and excluded other possible sites of involvement especially liver and lungs location. Blood tests show eosinophilia and serum echinococcosis serology techniques: ELISA against the arc 5 antigen and Western blot, were positive and confirm the diagnosis of *Echinococcus Granulosus* infection.

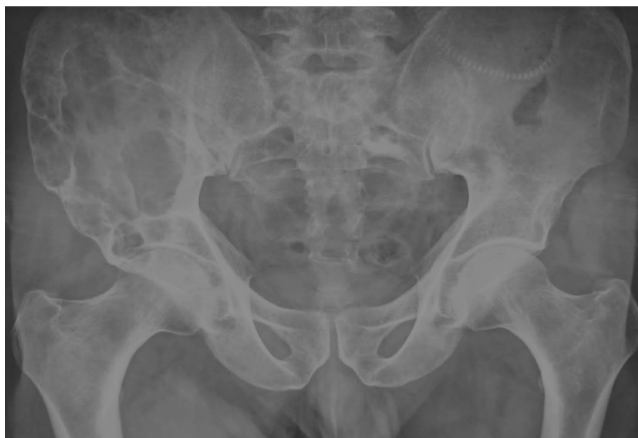

Figure 4. Standard X-ray of the pelvis in frontal view, showing poorly defined areolar lytic images, achieving the classic "honeycomb" appearance. There is no periosteal reaction or regional calcifications.

The diagnosis of right thigh muscles and ipsilateral iliac bone primary hydatidosis was made. An anthelmintic therapy based on Albendazole was instituted in order to reduce the lesion volume. A surgical resection can be then later planified.

3. Discussion

3.1. Epidemiology

Echinococcosis or hydatidosis is caused by the cestode *Echinococcus* in its larval stage [4]. The disease is particularly common in Asia, North and East Africa, South America, Australia and the Middle East [2]. It is more common in those who are engaged in agriculture and animal husbandry, and those in contact with dogs [7]. The larvae develop in cystic form, usually in the liver (60-70%) and lungs. Bone and striped muscle are particularly rare localizations, especially as the primary site. Bone contamination occurs mainly through hematogenous route, but secondary bone invasion from primary soft tissue involvement is possible [5].

3.2. The Clinic

The clinical signs revealing the condition are not specific and depend on the location. Usually, cysts remain clinically silent for a long time [7]. Pain and swelling are the most common in muscle hydatid cyst, as like as our case. The clinical examination is non-specific. A slight lameness is observed when lower limbs or pelvis are affected. Pressure in the affected area can trigger pain. No overlying skin changes are noticed in uncomplicated forms [8]. Bone hydatid disease symptoms may include localized pain and discomfort due to bony destruction. Other presenting complaints may include pressure symptoms, swelling, sinus formation and pathological fractures. Maintenance of general condition and apyrexia are usual in uncomplicated forms [6].

3.3. Imagery

For imaging diagnosis, ultrasound is the diagnostic tool of

choice for visceral and muscular cystic echinococcosis. X-rays, CT and magnetic resonance imaging are commonly used to diagnose hydatid bone disease. X-rays remain the first-line examination for symptomatic bone forms diagnosis. It most often shows poorly limited areolar lytic images, achieving the classic "honeycomb" appearance without periosteal reaction or surrounding soft parts calcifications [9]. In the pelvis, iliac bone involvement can have the characteristic "waffle-appearance", which pertains to a sizable area of osteolysis, as in our case [10]. However, this aspect is nonspecific and can be found in cases of bone tumors, tuberculosis or nonspecific infectious disease [11]. The interest of ultrasound is mainly to explore the soft parts to looking for ossifluent abscess or detecting other associated localizations; muscular as our case, or abdominal location. It contributes, as well as the chest x-ray, to the assessment of hydatid disease, to the search for associated visceral locations that may guide the diagnosis [9]. CT and essentially MRI imaging play a key role in hydatid disease diagnosis [2]. They determine the bone damage, assess the locoregional extent and constitute an excellent means of monitoring the disease progression [9]. The role of ultrasonography and MRI as gold standards to confirm the diagnosis before surgery has been proven [11, 12]. The most characteristic and specific features of hydatid disease in MRI imaging are: a double-layer wall, the presence of daughter cysts and the water-lily sign. MRI scans show the daughter cysts with high signal intensity or low signal intensity in T2-weighted images. The lower signal intensity of daughter cysts compared with the matrix of the mother cyst in T2-weighted images is a sign of the parasite death [2]. However the computed tomography still the best tool to characterize bone lytic lesion, cortical destruction and for detecting cystic wall calcification and revealing the internal cystic structure posterior to calcification in soft tissue locations.

The differential diagnosis varies with the types and location of hydatid cyst. For muscular location, differential diagnosis includes abscesses, chronic hematomas, lymphangiomas, synovial cysts, and necrotic malignant soft tissue tumors [7, 13]. Tuberculosis, chondrosarcoma, malignant fibrous histiocytoma, myeloma, metastatic disease, giant-cell tumor, aneurysmal bone cyst, plasmacytoma, a simple bone cyst, brown tumor of hyperparathyroidism, chondromyxoid fibroma are all differential diagnosis of bone hydatid cyst [10, 14].

3.4. Biology

Some serologic markers are useful for diagnosis, eosinophilia is an important finding in laboratory findings, but it may not always be seen [7]. Immunodiagnosics; Western blot and hemagglutination antibody test; can be helpful for a primary diagnosis, as well as in the follow-up of patients after surgical or pharmacological treatment. However, not all patients with echinococcosis are detected by serology. In extrahepatic disease, the sensitivity of these tests reduces to about 25–56%, limiting the use of serology tests to aid in the diagnosis of bone and muscular hydatid disease [10].

3.5. Prognosis

The prognosis of the disease depends on lesion volume and its location. Iliac bone involvement has a poor functional prognosis due to extension to the hip joint and more rarely to the sacrum [10]. Bone hydatid cyst has been called “white cancer” [15]. The surgery is often debilitating, with a high risk of recurrence [16].

3.6. Treatment

For Muscular echinococcosis, surgical treatment consisting of the cyst excision and pericystectomy are the treatment of choice [2]. While, the current treatment for bone location is medico-surgical [5]. The medical treatment is based on Albendazole [16, 17], its aims are to reduce the cysts size, sterilize their contents preoperatively and postoperatively to treat small cysts that have gone unnoticed [5]. Surgical treatment consists of a “carcinological” excision of the lesions which can be compared to a true malignant tumor. Rupture or spoilage of cysts should be avoided to prevent local or distant dissemination and immediate anaphylaxis: an excision with wide margins is therefore recommended [2, 10]. The percutaneous treatment can be an effective treatment choice and alternative to surgery according to Akhan *et al* [6]. Despite the different therapeutic methods the relapse rates are very high, especially after partial excision [2, 10].

4. Summary

Muscular and bone hydatid disease is uncommon. It presents a diagnostic and therapeutic challenge. Vague symptoms and low sensitivity of blood tests of muscular and bony involvement may delay presentation and diagnosis. Imaging, especially ultrasonography and MRI, plays a crucial role in making the diagnosis of hydatid cyst when typical imaging features are seen. It contributes also to the hydatid disease assessment, to the search for associated visceral locations. Management is often complex and onerous. It involves both medical and mutilating surgical treatment. Due to the high incidence of recurrence and the debilitating nature of surgery especially for hydatid disease of the pelvic bone, measures to debulk the enlarged cysts are often the treatment of choice.

5. Declaration of Interest

All the authors do not have any possible conflicts of interest.

References

- [1] Moretti B, Panella A, Moretti L, Garofalo R, Notarnicola A. Giant primary muscular hydatid cyst with a secondary bone localization. *International Journal of Infectious Diseases*. 2010; 14S: 192–195. Doi: 10.1016/j.ijid.2009.07.003.
- [2] Muratori F, De Gori M, D'Arienzo A, Bettini L, Roselli G, Campanacci DA, Capanna R. Hydatid cyst in the vastus lateralis muscle: a case report. *Clinical Cases in Mineral and Bone Metabolism*. 2017; 14 (2): 262-264.
- [3] Arti H, Darani HY. Fibular hydatid cyst. *IJO*. 2007; 41 (3).
- [4] Monge-Maillo B, Samperio MO, Pérez-Molina JA, *et al*. Osseous cystic echinococcosis: a case series study at a referral unit in Spain. *PLoS Negl Trop Dis* 2019; 13: e0007006.
- [5] Kurz, K., Schwabegger, A., Schreieck, S. *et al*. Cystic echinococcosis in the thigh: a case report. *Infection*. 2019; 47: 323–329. Doi.org/10.1007/s15010-018-1255-9.
- [6] Akhan O, Yildiz O, Unal E, Ciftci TT, Akinci D. Percutaneous Treatment of Bone Hydatid Cyst. *Cardiovasc Intervent Radiol*. 2021 Jul; 44 (7): 1131-1134. doi: 10.1007/s00270-021-02796-3. Epub 2021 Mar 15. PMID: 33723665.
- [7] Oğur HU, Kapukaya R, Külahçı Ö, Yılmaz C, Yüce K, Tuhanoğlu Ü. Evaluation of radiologic diagnostic criteria and treatment options in skeletal muscle hydatid cysts. *J Orthop Surg (Hong Kong)*. 2019; 27 (3): 1-6. doi: 10.1177/2309499019881219. PMID: 31684830.
- [8] Khasawneh R. A, Mohaidat Z. M, Khasawneh R. A. *et al*. Unusual intramuscular locations as a first presentation of hydatid cyst disease in children: a report of two cases. *BMC Pediatr*. 2021; 21: 371. Doi: 10.1186/s12887-021-02843-5.
- [9] Nhamoucha Y, Alaoui O, Doumbia A and *al*. Bone hydatid cyst: a rare localization at the level of the hip bone. *Pan African Medical Journal*. 2016; 24: 226. doi: 10.11604/pamj.2016.24.226.6322.
- [10] Govindasamy A, Bhattarai PR, John J. Lytic parasitic: a case of bone destructing echinococcosis. *Ther Adv Infectious Dis*. 2021; 8: 1–7. DOI: 10.1177/ 20499361211047664.
- [11] Garcia-Alvarez F, Torcal J, Salinas JC, Navarro A, Garcia-Alvarez I, Navarro-Zorraquino M. Musculoskeletal Hydatid disease: A report of 13 cases: *Acta Orthop Scand*. 2002; 73: 227-231.
- [12] Mseddi MB, Mseddi M, Siala A, Dahmene J, Ben Hamida R, Ben Ayeche M. Hydatid cysts in muscles: Eleven cases. *Rev Chir Orthop Reparatrice Appart Mot*. 2005; 91: 267-271.
- [13] Atalar M. H, Cankorkma L, Köylüoğlu G, Salk I. Imaging characteristics of three primary muscular hydatid cyst cases with various patterns. *Kafkas Journal of Medical Sciences*. 2012; 2: 74-76.
- [14] Reddy IV, Kumar HA, Samorekar B and *al*. Complicated Hydatid Cyst of Ulna- A Rare Case Report. *Journal of Clinical and Diagnostic Research*. 2017; 11 (5): RD01-RD03.
- [15] Boussaid S, Daldoul C, Hassayoun M, Rekik S, Jammali S, Sahli H, Elleuch M. Primitive pelvic bone hydatidosis: What an amazing extension. *Clin Case Rep*. 2021; 9 (12): e05054. doi: 10.1002/ccr3.5054. PMID: 34938540; PMCID: PMC8665691.
- [16] Neelapala V. S, Chandrasekar C. R & Grimer, R. J. Revision hip replacement for recurrent Hydatid disease of the pelvis: a case report and review of the literature. *J Orthop Surg Res*. 2010; 5: 17. Doi: 10.1186/1749-799X-5-17.
- [17] Cambier A, Hayette MP, Léonard P, Kurth W, Lovinfosse P, Giot JB. Isolated pelvic bone involvement as a presentation of alveolar echinococcosis. *Lancet Infect Dis*. 2021; 21 (8): 1192. doi: 10.1016/S1473-3099(21)00254-1. PMID: 34331888.