

# A multimedia package for patient understanding and rehabilitation of non-contact anterior cruciate ligament injuries

Gordon Buchanan<sup>1</sup>, Minhua Ma<sup>2</sup>, Paul M. Rea<sup>1,\*</sup>

<sup>1</sup>Laboratory of Human Anatomy, School of Life Sciences, University of Glasgow, Glasgow, UK

<sup>2</sup>Digital Design Studio, Glasgow School of Art, Glasgow, UK

## Email address:

Gordon.buchanan7@btinternet.com (G. Buchanan), M. Ma@gsa.ac.uk (M. Ma), Paul.Rea@glasgow.ac.uk (P. M. Rea)

## To cite this article:

Gordon Buchanan, Minhua Ma, Paul M. Rea. A Multimedia Package for Patient Understanding and Rehabilitation of Non-Contact Anterior Cruciate Ligament Injuries. *International Journal of Medical Imaging*. Vol. 2, No. 3, 2014, pp. 44-53.

doi: 10.11648/j.ijmi.20140203.11

---

**Abstract:** Non-contact anterior cruciate ligament (ACL) injury is one of the most common ligament injuries in the body. Many patients' receive graft surgery to repair the damage, but have to undertake an extensive period of rehabilitation. However, non-compliance and lack of understanding of the injury, healing process and rehabilitation means patient's return to activities before effective structural integrity of the graft has been reached. When clinicians educate the patient, to encourage compliance with treatment and rehabilitation, the only tools that are currently widely in use are static plastic models, line diagrams and pamphlets. As modern technology grows in use in anatomical education, we have developed a unique educational and training package for patient's to use in gaining a better understanding of their injury and treatment plan. We have combined cadaveric dissections of the knee (and captured with high resolution digital images) with reconstructed 3D modules from the Visible Human dataset, computer generated animations, and images to produce a multimedia package, which can be used to educate the patient in their knee anatomy, the injury, the healing process and their rehabilitation, and how this links into key stages of improving graft integrity. It is hoped that this will improve patient compliance with their rehabilitation programme, and better long-term prognosis in returning to normal or near-normal activities. Feedback from healthcare professionals about this package has been positive and encouraging for its long-term use.

**Keywords:** Digital Reconstruction, Knee Anatomy, Surgical Reconstruction

---

## 1. Introduction

The most common ligament in the body to be injured is the anterior cruciate ligament (ACL) [1-6]. It is the most common ligament to be damaged in non-contact sports like football, basketball, volleyball and gymnastics, especially in women due to a number of biomechanical, neuromuscular, biochemical and anatomical factors [1-5, 7]. Damage to this ligament varies in severity but can require surgical intervention. Most commonly, it involves repairing the ligament by using a graft taken from ligaments within close anatomical proximity like the patellar or hamstring tendons [7, 8]. Following surgery, the patient then has to undergo an extensive rehabilitation programme. However, many factors come into play when educating a patient about their injury, and necessary physical therapy that they

will have to engage with to enhance recovery (Shelbourne and Nitz, 1990; Fisher et al, 1993; Taylor and May, 1996; Brewer, 1998). To ensure success from rehabilitation, the patient must have a clear understanding of the injury, its mechanism, the necessary rehabilitation goals, the chance of re-injury and the factors which could cause this [8-12]. Consequently a desirable goal would be an effective method of educating patients to the nature and mechanisms of their injury and the necessary goals and restrictions of their rehabilitation programme. The patient would then have an understanding of why they were following these goals and restrictions, and would be less likely to be non-compliant as they would understand the negative consequences which could follow i.e. a rupture of their graft.

Despite the wide use by the public in digital technologies, patient education about their injury and treatment plan is

still undertaken by using a static knee model, simple line drawings and outdated leaflets [8]. This still echoes physiotherapists training where 2D visuals are used in educating them about anatomy and its clinical applications [13]. This is because physiotherapists training generally involves no or minimal access to cadaveric material to aid their 3D understanding of the human body in the UK.

However, there is an increased demand from anatomical educators for additional teaching resources, including those of a virtual environment and interactive multimedia across a number of platforms [14-16]. This has happened since the reduction in numbers of hours of direct contact teaching time in anatomy using cadavers, especially for undergraduate medical students [17,18]. There are now many anatomical training packages which are available for use in undergraduate anatomical education including the US Visible Human dataset [19], VisibleBody, Google Body Browser, Primal Pictures and Cyber Anatomy Med to name a few. More recent work has also shown a very unique and innovative way to use ultra-high definition real-time interactive 3D anatomy which can be used in a large scale 3D stereoscopic display in teaching laboratories with haptic procedures being able to be performed [20].

There is a therefore a gap between the tools physiotherapists, surgeons and other allied health professionals use in educating the patient about their condition and what actually happens from an educational and training perspective. As technology has developed and become widespread, the use of static models and drawings has become increasingly outdated. Despite the widespread distribution of both desktop and laptop computers and smartphones, they are not being utilized in patient education. With the increasing availability of digital technologies, coupled with the fact that 3D models are more engaging [21], and patient education and compliance to rehabilitation is key [10], it seems that the creation of a virtual knee model for patient's is long overdue.

The motivation for this project therefore is to bridge the gap between what is available to educators and what the patient is able to access from their healthcare professionals. Current modern technology is not being utilized to its full effect in the healthcare setting to help patients understand their injury, and aid the rehabilitation process, despite being used in all other aspects of day-to-day life. Therefore, the work presented here is to demonstrate a very unique way we have created a multimedia training package for the education and rehabilitation of the most common ligament injuries – that of non-contact anterior cruciate ligament injury. We hope that this can be used in the clinical setting by surgeons, physiotherapists and allied health professionals alike, to benefit patient care and engagement with their treatment and rehabilitation following an injury to the knee. We have uniquely combined anatomical dissection with modern technologies in creating an educational and training package of the anatomy of the knee joint, injuries and the healing process, to enhance patient understanding about their condition.

## 2. Experimental Procedures

### 2.1. Materials

One male cadaver was provided from the Laboratory of Human Anatomy, University of Glasgow. All cadaveric dissection and related health and safety issues were covered under the Anatomy Act 1984 and the Human Tissue (Scotland) Act 2006, Part 5. The cadaver was 80 years old and was preserved using the standard university protocol for formaldehyde embalming. The person died of bronchopneumonia and had no obvious lower limb deformity.

#### 2.1.1. Tools

Scalpel handle size 3, with scalpel blade size 11  
 Scalpel handle size 4, with scalpel blade size 25  
 Blunt and toothed forceps  
 Scissors  
 Surgical clippers  
 Bone saw  
 Digital camera – Sony 12.1 Megapixels, Cyber Shot, Optical Zoom 5x  
 Prosection specimens for reference

#### 2.1.2. Data

Visible Human (VH) dataset: male, 38-year old, who died from lethal injection (Spitzer et al., 1996). From this dataset, computed tomography (CT) and high-resolution images were used of the anatomical detail.  
 Human Zygote model

#### 2.1.3. Computer Software

Amira 5.4.3, Visualisation Sciences Group  
 Autodesk Maya 2013  
 Adobe After Effects CC Version 12.0  
 Adobe Photoshop Elements 11  
 Unity 3D Engine 4.0

### 2.2. Methods

#### 2.2.1. Cadaveric Dissection

In the supine position a vertical superficial incision was made extending from the mid-point of the left thigh to the tibial tuberosity. Perpendicular incisions were made at the proximal and distal ends to ensure wide exposure of the anterior thigh, knee joint and upper leg. The underlying fascia and subcutaneous fat of the anterior thigh was removed. To allow access to the posterior aspect of the thigh, the lower limb was amputated at the mid-thigh level. Reflection of skin and removal of fascia and subcutaneous fat was continued on the posterior aspect by piecemeal dissection. The foot was amputated at the mid-tibial level to allow ease of access to the knee joint and minimise the weight of the dissected specimen.

The muscles of the anterior, medial and posterior thigh were identified by blunt dissection. Following identification of these muscles, the knee joint was exposed. On the posterior aspect, the popliteal fossa was opened and

the fat removed. The common peroneal (fibular) and tibial nerves were identified along with the popliteal artery and vein. Following this, the popliteal vessels and fat were removed to allow exposure of the medial and lateral heads of gastrocnemius. The superior attachments of gastrocnemius were cut and reflected inferiorly thus exposing the deeper muscles.

The collaterals (medial and lateral) were then identified and defined. The posterior joint capsule deep in the popliteal fossa was then exposed and the posterior cruciate ligament within the knee joint identified. The collateral ligaments were then sectioned to allow disarticulation of the knee joint and clearer identification of both the anterior and posterior cruciate ligaments and their femoral and tibial attachments. The medial and lateral menisci were then identified and cleaned to expose them fully.

The same dissection protocol was repeated on the right lower limb as described. Photography was undertaken at all key stages mentioned to capture each of the anatomical structures in digital format.

### 2.3. 3D Reconstruction from the VH Dataset

To reconstruct the 3D model from 2D data we used the VH dataset images a\_vm2000 to a\_vm2500. These images encompassed a region from upper thigh to feet. By combining with MRI data of the normal knee we maintained the accuracy of the knee ligaments, especially the ACL. This allowed for muscle fibres to be traced from attachments to insertion and eased the identification and segmentation process.

The images were loaded into Amira with a pixel resolution of 2048: 1216: 5001 and a voxel resolution of 0.33: 0.33: 1. Amira requires the images to be converted to black and white to allow for 3D reconstruction, undertaken by selecting the Maximum channel. An identical selection of images were also loaded into Amira, however these images were kept as full color images to aid in the segmentation to identify structures. The normal male knee MRI images were also loaded into Amira.

Both the black and white, full color and MRI images were arranged in image stacks to be viewed in an orthoslice format. This allowed the user to scroll through the stack of images in multiple planes (sagittal, coronal, and transverse).

### 2.4. Segmentation

Slices 170 to 420 were used for the segmentation, as this selection of images shows the area of the leg that was explored in the earlier dissection. As segmentation is a particularly time consuming process, it was decided to only segment one leg of the VHP dataset. Sections of a number of images, which show the right leg, had a number of defects, likely caused in the freezing process; therefore the left leg was chosen. Segmentation was primarily performed in the axial view, however both the sagittal and coronal views were frequently checked to ensure accuracy was maintained.

#### Bones

Due to the nature of the high resolution images, fat appeared as the same pixel value as bone, therefore most forms of automatic segmentation such as thresholding algorithms were not useful or appropriate. The most effective method of segmentation used was manual paintbrush segmentation supplemented by region growing. For the main portion of each bone defined (Table 1), an interpolation algorithm was applied every 5 slices. At the proximal and distal ends of each bone, along with any irregular sections each slice was segmented manually to avoid any mistakes. Each bone was checked and any defects corrected manually.

**Table 1.** Bones segmented from CT and cryosection images from the VH dataset.

Femur	Patella
Tibia	Fibula

#### Muscles

Segmentation of the muscles (Table 2) was primarily done by means of region growing; however in certain areas the muscles were in intimate proximity to each other, which reduced the efficiency of this method. In these cases manual segmentation using the paintbrush tool was necessary. Similarly to the bones, an interpolation algorithm was applied every 5 slices for the majority of the muscles excluding the proximal and distal ends and any irregular sections. In these sections each slice was segmented manually. The high-resolution color images were consulted to aid in identifying the muscles and their divisions, primarily to trace the muscles to their proximal and distal attachment sites. The knowledge gained from the earlier dissection aided orientation and identification of the muscles.

**Table 2.** Muscles segmented from CT and cryosection images from the VH dataset.

Rectus Femoris	Vastus Lateralis	Vastus Medialis	Vastus Intermedius
Sartorius	Gracilis	Adductor Magnus	Long Head of Biceps Femoris
Short Head of Biceps Femoris	Semimembranosus	Semitendinosus	Tibialis Anterior
Extensor Digitorum Longus	Fibularis Longus	Fibularis Brevis	Lateral Head of Gastrocnemius
Medial Head of Gastrocnemius	Soleus	Plantaris	Tibialis Posterior
Popliteus			

#### Ligaments

The various ligaments (Table 3) were segmented exclusively by means of manual paintbrush segmentation and no interpolation was performed. This was done for a number of reasons: a desire for a high degree of accuracy, the intimate relations the ligaments have with the various structures of the knee joint and the relatively small number of images in which they appear. Each image was matched

with an equivalent full color image to aid in the accuracy of segmentation and in addition the medical MRI images were consulted. The knowledge gained from dissection was also extremely useful as a reference point. The medial collateral ligament and the oblique popliteal ligament were found to be virtually inseparable from the joint capsule; therefore it was impossible to accurately segment these structures. The medial and lateral menisci were also extremely difficult to accurately segment due to their intimate proximity to the tibial plateau. Therefore it was decided to manually model these structures at a later stage in the project. The patellar tendon was also segmented in this group.

**Table 3.** Ligaments segmented from CT and cryosection images from the VH dataset.

Anterior Cruciate Ligament	Posterior Cruciate Ligament
Lateral Collateral Ligament	Patellar Ligament
Patellar Tendon	

## 2.5. Modification of Zygote Human Model

The complete Human Zygote Model was imported into Autodesk Maya. The skeletal, muscular and connective tissue layers from and around the knee joint were used to reduce complexity with too many polygons. The model was then moved and manipulated to a cruciform position, to prevent any later difficulties, as the cruciform position is the standard in animation. The cruciform allows for the efficient construction of joints and control rigs and prevents any defects occurring during the binding of meshes to joints.

Maya includes a Human IK Skeleton option which constructs a default joint skeleton in the cruciform position which can be modified by the user for a range of requirements. For this study, the default skeleton was modified to have no finger joints, as no finger movements were planned. A default control rig, also included in the Human IK option, was attached to the skeleton and allowed the user to control the movement of the joints in a realistic manner. The rig included controls for the head, neck, clavicles, shoulders, elbows, wrists, various points in the spine, pelvis, hips, knees, ankles, balls of the feet and the toes. Both the joint skeleton and the control rig were placed in a separate layer to the skeletal, muscular and connective tissues to improve workflow efficiency. The joint skeleton was scaled and moved to match the model, with individual joints positioned to match their anatomical equivalents. This resulted in a model consisting of skeletal, muscular and connective tissues overlaid on a joint skeleton with an attached control rig, with the joints of the model and the joint skeleton matched as closely as possible.

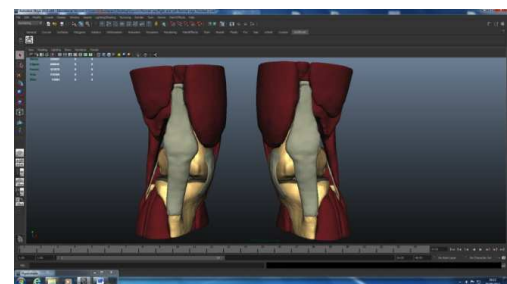
The entire skeletal mesh layer was bound to the control rig using a rigid bind, a method which only allows a polygon to be influenced by one joint, this method closely mimicking the nature of a human skeleton. The control rig was then used to move the bound skeleton through a variety of motions to check for any defects or inappropriate binding. Defects were corrected by the Paint Skin Weights

tool, an intuitive method where the user “paints” the influence of a joint onto a polygonal mesh, allowing for a more natural looking binding.

## 2.6. Creation of Custom Models

### 2.6.1. Normal Custom Model

The extracted data files of each individual structure were loaded into Autodesk Maya, in the obj format. Maya converted these files into 3D polygonal meshes. Due to the segmentation process followed in Amira, each mesh was loaded into its correct anatomical position without any user input. The polygonal meshes were separated into layers based on whether the mesh represented a bone, a muscle or a ligament. The polygonal mesh representing the patellar tendon was placed in the Muscle layer. These selectable layers allow the user to independently view and modify the various tissue types. As the number of polygons in each mesh was extremely high, and interacting with multiple meshes at once can cause performance issues, using these layers allowed Maya and the user to work more efficiently. Each polygonal mesh was cleaned up individually to remove any non-manifold geometry i.e. shapes which cannot exist in reality. By removing the non-manifold geometry it was now possible to reduce the number of polygons in each mesh. A second clean-up was applied to each mesh to remove any non-manifold geometry the reduction may have caused. The Sculpt Geometry Tool then manually smoothed each polygonal mesh. At this stage the medial collateral ligament (MCL) and the medial and lateral menisci were not present in the model. These structures were impossible to segment in Amira therefore it was decided to manually create them in Maya. Firstly the MCL mesh from the Zygote Human Model was imported into the Maya scene containing the model. As this imported polygonal mesh was independent from the structures obtained from Amira, resizing and repositioning was required. Next a Zygote Human model medial mesh and lateral menisci mesh were imported into the scene. Each meniscal mesh was scaled and repositioned to the correct anatomical position. A final smooth was then applied to each of the meshes imported from the Zygote model. All meshes were then organized into a group titled Left Leg. This resulted in a complete model of the Normal Left Leg. This group was then mirrored, creating a symmetrical duplicate of the model which represented the Right Leg, as shown in Figure 1.



**Figure 1.** Normal custom model of left and right legs.

### 2.7. Ruptured Custom Model

To allow the patient to understand their injury, a model was created of a ruptured ACL. A representative set of MRI images were used from a ruptured ACL injury and loaded into Amira for reference. The previously created Normal Model was then imported into Maya with only the bones and ligaments of the Left Leg shown. The mesh representing the ACL was selected and viewed as a number of faces. The faces of the ACL at the femoral attachment were selected and extracted, and the lower edge of its femoral portion was then closed. The femoral portion was manually sculpted to depict the appearance of a remnant of a tear. The open upper border of the bulk of the ACL was closed. To obtain the correct shape of the ruptured ACL, a bend deformer was applied to the bulk of the ligament. This allowed for a natural curved appearance on the upper portion of the ACL while leaving the tibial attachment unaffected. Minor manual sculpting was then applied to the bulk of the ACL. All other anatomical structures of the left Leg were then revealed demonstrating the Ruptured Left Leg model (Figure 2).

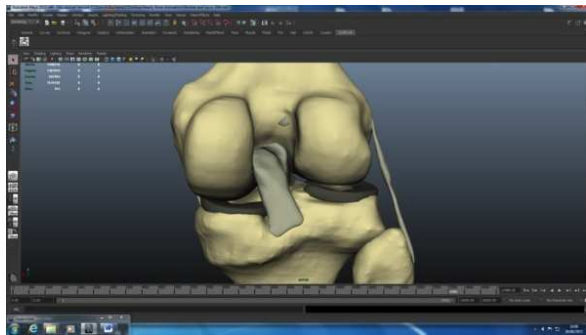


Figure 2. Ruptured left leg model.

### 2.8. Graft Custom Model

To enable patient understanding of the healing process following a graft procedure (and the limitations they have to work within their rehabilitation programme, and the reasoning for it), an animated model was created. Again in Maya, all other structures apart from bone and ligaments were hidden from the Ruptured Custom Model. The mesh representing the bulk of the ACL was selected and a bend deformer applied to the tibial attachment. This provided a representation of the ACL, which was naturally curved around the posterior cruciate ligament (PCL). Minor manual sculpting was performed on the bulk of the ACL and the PCL, to achieve an appearance of fusing. This meant there was a cleared tibial portion for graft insertion. It was decided to create a representation of a Patellar Tendon (PT) graft due to its reported widespread use.

A polygonal cylinder was created, which was then modified by the addition of a large number of divisions. A bend deformer was applied, resulting in a slightly bent cylinder. The faces of the top and the bottom of the cylinder were individually selected and separated from the

middle portion of the mesh. This resulted in identical top and bottom portions which represented the bone fragments of a PT graft, while the middle section represented the tendon portion. These sections were grouped to allow synchronised movement. Minor manual sculpting was performed on all three sections to achieve a more stylized appearance of the graft. The group was moved into position in the internal knee joint, and a second bend deformer applied and manipulated until the mesh's representing the bone fragments was anatomically correct. A final smooth was applied to the graft meshes, resulting in a stylized representation of the graft, as shown in Figure 3. The hidden structures of the left leg were then restored. This resulted in a model of the Graft Left Leg.

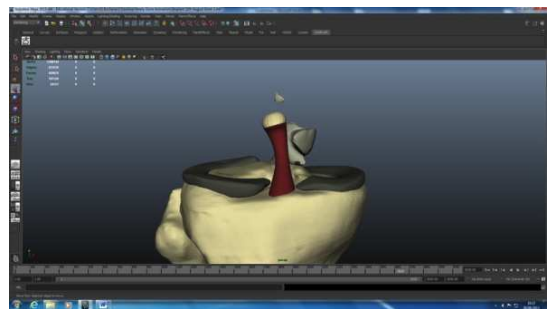


Figure 3. The graft model.

### 2.9. Creation of Anatomical Helpers

For later use in the interactive application, two small anatomical helpers were created in Maya, with one helper assigned to each leg. Each helper consisted of six polygonal cylinders with six polygonal pyramids positioned at the end of each cylinder. Each helper was grouped to allow for synchronized manipulation i.e. scaling, rotation. These paired cylinders and pyramids formed arrows, positioned to face the anterior, posterior, superior, inferior, medial and lateral directions. Each arrow was named to match its direction. Both helpers were smoothed to achieve a more aesthetically pleasing appearance.

### 2.10. Texturing

For the Zygote Model, the default textures of that model were used generally with only slight modifications to colour, based on what was observed in dissection. Maya lambert textures were then individually applied to each structure in the Normal Model, the Ruptured Custom Model, and the Graft Custom Model with the exception of the graft structure. This allowed for precision control over the colour and transparency of each structure, making it possible to highlight or hide individual structures. A simple colour scheme was followed, with bony structures grey-white, ligamentous structures grey, menisci and the patellar tendon dark grey, and muscles red. The three meshes which make up the graft structure were given individual textures, with the two meshes representing the bony fragments colored grey-white representing bone and the mesh representing the tendon colored red.



### 2.10.1. Animations

Following on from the creation of the models, they were then animated to create a visually appealing educational package. In Maya two “rooms” were created from polygonal planes with Maya lambert textures colored white. These rooms were placed in separate layers. A NURBS circle surfaces was created and centered in room one and a camera parented to this circle. This parenting caused the camera to translate and rotate with the circle, allowing for smooth camera movement. A directional light was attached to the camera, ensuring that the camera’s target would always be well lit. This group of circle, camera and light was duplicated and centered in room two. Both of these groups were placed in individual layers named Camera 1 and Camera 2. Using this template, with each “room” containing a separate model if required, four animations were created to explain various processes involved in non-contact ACL injuries. These were as follows:

1. Normal function of the ACL (utilizing the Mobile Zygote Model and the Normal Custom Model)
2. Mechanism of a non-contact ACL injury, including female differences (utilizing the Mobile Zygote Model, the Normal Custom Model and the Ruptured Custom Model)
3. Surgical procedure of ACL reconstruction (utilizing the Ruptured Custom Model and Graft Custom Model)
4. Four stages to graft healing after surgical reconstruction, and the early goal of rehabilitation (utilizing the Graft Custom Model with some minor modifications)

The four animations were exported separately to Aftereffects. Once in Aftereffects a variety of additional information was added, including titles, structure tags, movement arrows and text explaining the processes depicted in the animations.

### 2.11. Creating an Interactive Application

An interactive learning application consisting of a number of scenes and levels was created in Unity 3D Engine. Each scene is a viewable and interactive level which the developer can modify as they require. These levels include a Main Menu, a level where the user can interact with the Normal Custom Model of the knee, and a number of levels which show images taken from dissection.

The images taken during the dissection stage were exported to the Unity project, assigned to matching structures and placed in the various levels. A user interface was constructed to allow the user to navigate between levels, along with allowing the user to perform a variety of different interactions in each level.

### 2.12. Evaluation of the Animations and Interactive Learning Application

Semi-structured interviews were undertaken with two individuals who work within the NHS, one an orthopedic

consultant and trauma surgeon and the second a Senior Physiotherapist. These interviews focused on the individual’s experience of ACL non-contact injuries, their typical methods of communicating and educating patients to the nature of their injury, their views on patient education in relation to compliance with rehabilitation programmes and their experience of utilizing 3D models or animations in the National Health Service (NHS). The animations and learning application were also presented at these interviews, enabling a discussion on the overall quality of the project, its potential uses, any possible improvements, any potential future work and their opinion with regards to providing patient access to the project.

## 3. Results

### 3.1. Dissection

Dissection of the distal thigh and proximal lower leg regions exposed the internal and surrounding anatomy of the knee joint. This allowed for a detailed examination of the various skeletal, ligamentous and muscular structures of the region, in most cases revealing their morphology, including texture and color, origin and insertions, and spatial relationships with other structures. All muscles (Table 4), ligaments and skeletal structures were meticulously dissected and imaged.

**Table 4.** Muscles identified during cadaveric dissection.

Quadriceps			
Rectus Femoris	Vastus Lateralis	Vastus Medialis	Vastus Intermedius
Medial Thigh Muscles			
Sartorius	Gracillis		Adductor Magnus
Hamstrings			
Long Head of Biceps Femoris	Short Head of Biceps Femoris	Semimembranosus	Semitendinosus
Muscles of the Anterior Compartment of the Lower Leg			
Tibialis Anterior		Extensor Digitorum Longus	
Muscles of the Lateral Compartment of the Lower Leg			
Fibularis Longus		Fibularis Brevis	
Muscles of the Superficial Posterior Compartment of the Lower Leg			
Lateral and Medial Head of Gastrocnemius	Soleus		Plantaris
Muscles of the Deep Posterior Compartment of the Lower Leg			
Tibialis Posterior		Popliteus	

### 3.2. Construction of an Anatomically Accurate 3D Model

Using Amira’s processes of surface segmentation and extraction, a root model of the 3D anatomy of the knee joint was created. This model includes muscular, ligamentous and skeletal structures. Due to the nature of the segmentation, this model accurately shows the morphology and spatial positioning of the structures included.

The use of high resolution anatomical images from the Visible Human Dataset provided an anatomically accurate baseline from which the model could be formed. The images were primarily segmented in the axial plane; however a 4-plane view was frequently consulted to ensure accuracy. Full colour anatomical images and medical MRI data were also used to aid the user when they were uncertain over a structure. Due to the nature of the high-resolution anatomical images, no automated segmentation

processes could be used. While this made the process significantly more time consuming, it provided an increased level of anatomical accuracy. Table 5 shows the anatomical structures which were segmented. Note the absence of the MCL and both menisci. These structures were omitted as they were practically impossible to accurately segment. The final surfaces of the model created by Amira had a triangulated appearance and were exported to allow for further modification.

**Table 5.** Structures modeled in Amira.

Muscular Structures			
Rectus Femoris	Vastus Lateralis	Vastus Medialis	Vastus Intermedius
Sartorius	Gracilis	Adductor Magnus	Long Head of Biceps Femoris
Short Head of Biceps Femoris	Semimembranosus	Semitendinosus	Tibialis Anterior
Extensor Digitorum Longus	Fibularis Longus	Fibularis Brevis	Lateral Head of Gastrocnemius
Medial Head of Gastrocnemius	Soleus	Plantaris	Tibialis Posterior
Popliteus			
Ligamentous Structures			
ACL	PCL	LCL	Patellar Tendon
Skeletal Structures			
Femur	Patella	Tibia	Fibula

### 3.3. Creation of the Normal Custom Model, Ruptured Model and Graft Model

Importation of the extracted surfaces to Maya (from Amira) resulted in a number of polygon meshes which represent anatomical structures. These polygon counts of these meshes were reduced to improve workflow and each mesh was individually smoothed to improve its appearance. The three missing structures, the MCL and both menisci, were created in Maya and modified towards an accurate anatomical appearance. This model was further modified to display a number of different states including the normal appearance, the ruptured appearance, and the graft appearance. These models retain a high level of anatomical accuracy, but in some cases include stylized elements. The Zygote Human Model was also imported into Maya, and a joint skeleton and control rig added. This resulted in a model of the entire body which could be easily manipulated and animated. Both the created models and the Human Zygote Model were textured to appear as realistic as possible, while still allowing a high level of user control over transparency and color.

### 3.4. Animations

Utilizing these models four animations were created in Maya, summarizing various processes involved in the normal function of the ACL, a non-contact ACL injury, its surgical treatment and factors important in its rehabilitation. Once rendered various additional elements such as text and

movement arrows were added to these animations using Aftereffects.

### 3.5. Interactive Learning Application

An interactive learning application was created using Unity. This application is intended to allow a user to interact with a 3D model of anatomy, with assigned functions and images taken from dissection and to allow for learning at the user's own pace and in an environment of their own choosing. This also allows the user to experience some of the educational benefits of dissection and reinforce knowledge gained from the animations. For use in this application the Normal Custom model was used, along with Anatomical Helpers and labeled images obtained from the original dissection.

The seven levels of the interactive application consist of;

#### 1) Main Menu

This is the initial level of the application and acts as a gateway to the other levels, through the use of GUI buttons. It is also possible to quit the application from this level.

#### 2) Custom Model of Normal Knee Anatomy

This level shows the Normal Custom Model as an example of normal knee anatomy. All muscular, ligamentous and skeletal structures in the model are displayed. This model utilises highly interactive structures allowing a user to highlight, click and drag change position, display important information on a display screen, display a labelled dissection image of the relevant structure in a frame. The camera is user controlled with the mouse and

can zoom, pan and rotate. GUI Buttons and Sliders give the user a great deal of control over the appearance of the model and allow for the re-set of the model and camera position. A GUI label explains all the functions of the level. A number of buttons allow the user to navigate to the Main Menu or quit the application.

### 3) Images of Bones, Ligaments and Muscles

These levels display the various images taken from dissection; divided into bones, ligament and muscles. Images are displayed at a small size in rows. When clicked these images switch to full screen. An exit button allows the user to quit the full screen image view. Once again a number of buttons allow the user to navigate to the Main Menu, all image levels or quit the application (Figure 4).

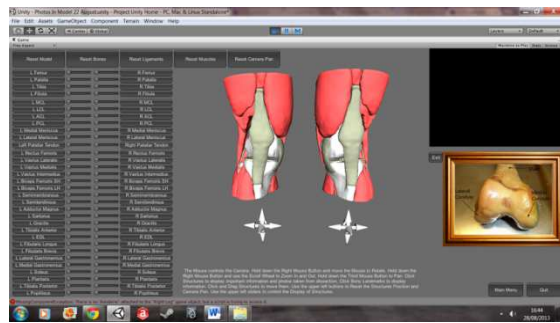


Figure 4. Normal knee anatomy in an interactive learning application.

### 3.6. Evaluation

To gain an initial insight into the potential for this type of package, we then interviewed, in a semi-structured format, two staff members involved in the care of patient's with ACL injuries—a Consultant in Orthopedic and Trauma Surgery and a Senior physiotherapist. Both staff members worked within the NHS and had considerable clinical experience. When communicating with the patient about the nature of their injury and treatment, they use static plastic models, with the consultant supplementing this with quick sketches. Both felt patient education was extremely important. The consultant felt they spent a great deal of time explaining to patient's the limitations of their graft but they stated that this effort caused a better rehabilitation compliance and outcome. The physiotherapist felt that provided patient education was related to the patient's desires, typically a return to work or sporting activity is effective in increasing compliance. Both participants did not currently use 3D models or animations and believed that none were currently being used in the NHS in general.

Reaction to the animations and learning application were extremely positive. They felt that the general appearance of the animation was good and the information was conveyed effectively. The physiotherapist highlighted a potential use of the animation to act as a baseline from which the physiotherapist or surgeon can build on. Both participants were happy for patients to view the animations. The consultant expressed an interest in using the animations for patient education. The physiotherapist also expressed an interest in placing the animations in a "useful websites"

link in the NHS ACL information pamphlets, provided the animations were placed online. With regards to the interactive application, both individuals felt it was suited for motivated, interested patients, typically those who were highly interested in sports. Both participants felt the application to be particularly useful for the user to "play" with over a longer time frame. The consultant noted the potential of the application for both students and doctors, while the physiotherapist felt that the application was useful for reinforcing the knowledge gained from the animations.

## 4. Discussion

We have shown that using the unique approach of combining cadaveric dissection with volumetric 3D visualization technology we have produced an educational tool which can be used to aid patient-clinician understanding for the most common ligamentous injury encountered in clinical practice—non-contact ACL injury. It is anticipated that this will now result in increased engagement with a patient's physiotherapy regime, and improve the outcome post-operatively.

One key element in this study, which will benefit the patient, is that the work was carried out on the cadaver in demonstrating the key anatomical components that are involved in ACL injury. This ensures complete accuracy of the dataset, and allows the patient to have access to as much information on their injury (including the anatomy and treatment plan) and will improve the long-term outcome. Indeed, it has been shown that patient education about their condition and treatment plan improves the success post-operatively [10]. Athletes in particular need to have a basic understanding of the anatomy and biomechanics of their injury to help them recover and return to exercise, but at the same time preventing injury [22].

In addition to this, and the absence of cadaveric dissection in most undergraduate physiotherapy courses in the UK, there is a huge market for this tool to be adopted for both patient education and student training. The unique combination of dissected material and novel digital technologies certainly advances considerably what is currently on offer across the NHS (pamphlets, line drawing by clinicians and fixed models).

During this study, a firm understanding of anatomy of the knee joint and surrounding structures was established. However, the manual segmentation of the structures — bones, ligaments and muscles, was certainly a very time consuming process. That said, it does clearly demonstrate that there is the highest degree of anatomical accuracy in the material created, rather than many unrealistic, cartoon-like packages currently available as mentioned earlier. One thing, which has been clear in this study, is that we have managed to combine traditional techniques, like cadaveric dissection, with modern technologies to create a highly feasible educational package to aid patient understanding of



their injury and treatment, thus ensuring engagement with the rehabilitation process. Again, this provides an ideal platform to develop healthcare driven applications, like what we have previously described in relation to education and rehabilitation for another sport related injury – that of the iliotibial band [23].

This study has also created an educational package to allow a better understanding of the healing process post-operatively. This will allow the patient to appreciate from a visual perspective exactly what they can and cannot do at key stages after, for example graft surgery. This coupled with the ability to manipulate the anatomical dataset will provide an excellent tool for both the patient and clinician.

Reconstruction from both anatomical and the VH datasets formed the ideal foundation in developing this interactive application. We have also assessed in a semi-structured format with the potential users of this package – healthcare professionals. It was widely felt, through both the semi-structured interviews and informal consultation with healthcare professionals in this field, that there is an overwhelming desire to improve the access to educational material for patients. It was found that the use of technology in this way was not being exploited enough in the NHS, despite the obvious benefits described by staff, and the wide body of research showing that engagement with the patient, their injury and treatment plan will show resounding success for the long term post-operatively.

There is clearly a pressing need for unique and innovative tools to supplement the very basic plastic models and line diagrams which are being currently used in educating patient's about ACL injury and rehabilitation from it. There is clearly a very large market in the sports industry where a lot of monetary value is invested into the athletes and they, alongside those presenting in other areas to the healthcare system, truly deserve more advanced, and engaging products than what is currently on offer.

This study clearly demonstrates the unique educational and training package to aid both patient and clinician understanding of their injury. Using a number of key tools, namely cadaveric dissection, normal and pathologic MRI images, the Zygote Human model, and the VH dataset, has validated the material presented here. It has also been developed alongside anatomical, digital, surgical and physiotherapy expertise and input to benefit the patient. It also could be rolled out in undergraduate training programmes, especially in physiotherapy, where, in the UK, there is minimal access to cadavers for these trainees.

#### 4.1. Limitations

Although only one cadaver was dissected (both left and right sides) at the knee joint, we did use a wide reference range of professionally dissected and plastinated (prosected) specimens from the anatomical collections within the Laboratory of Human Anatomy, University of Glasgow. This coupled with meticulous dissection ensured complete anatomical accuracy of the material imaged.

The segmentation process is a very arduous process and means that the model is not easily reproducible but with the advancement in technology, software and algorithms, this will hopefully improve the situation in the future. That said, we do now have the knee joint fully reconstructed in this format to be used as a training and educational platform.

We also used a widely accessible resource in anatomical education – the VH dataset. This however, does have some shortcomings due to the nature of how the material was collated. The cryosections were obtained after the cadaver had been segmented into four blocks resulting in a loss of data, though it was not felt to significantly impact this work [24].

The other limitation is that formal consultation with healthcare professionals consisted of only two health professionals in this field. However, it revealed encouraging interest in adopting this in a wider context, although this is out with the scope of this study at the moment. It serves as a future study into the wider applications both for health professionals, and perhaps more important, the patients themselves.

#### 4.2. Further Work

The methods used with this project to create the animations and interactive learning applications could theoretically be used across a wide range of medical conditions in educating the patient. Remaining with the ACL, future animations could show conservative treatment options, a variety of graft types, and a variety of surgical techniques. Contact ACL injuries and their effects could be shown along with injuries to other structures such as the PCL. It would likely be beneficial for researchers in the field of medical visualisation to encourage close contact with the staff of the NHS. A close working relationship between these two groups would allow for an efficient identification of problems and deficiencies of current patient education programmes, and the production of effective, useful and patient friendly animations. From this relationship a targeted database of animation could be created which covers the most frequent, debilitating and difficult to understand injuries. This database would include animations of the injury events, surgical treatments, normal and abnormal functions of damaged structures and rehabilitation exercises. Therefore the development of animations such as the ones created in this project is of particular interest to orthopaedic and physiotherapy departments. However as animations have been used in this study to show abstract processes (graft healing), it would be possible to create animations of similarly complex scenarios, such as the growth and treatment of cancer and the process of a heart attack. The further development of the interactive learning application is also an interesting avenue to explore, as one senior NHS staff member felt that it could also be a useful tool for doctors and medical students. This shows the potential applications such as these have in education. The interactive learning application could further be developed with a larger region

of anatomy covered and a greater number of tissue types included, such as skin, fascia, and vascular and nervous networks. Interactive applications could therefore be developed to suit a variety of groups, a differing anatomical region targeted and features added or removed as required. These applications could eventually be introduced into medical schools, universities, colleges, and, with a simplified version, schools and the wider public.

## Acknowledgements

The authors would like to thank the Accident and Emergency and Physiotherapy Departments of the Southern General Hospital, Glasgow, for providing clinical MRI images of ruptured ACL injuries and extensive assistance.

## References

- [1] DeMorat G, Weinhold P, Blackburn T, Chudik S, Garrett W. 2004. Aggressive quadriceps loading can induce noncontact anterior cruciate ligament injury. *The American Journal of Sports Medicine* 32:477-483.
- [2] Olsen OE, Myklebust G, Engebretsen L, Bahr R. 2004. Injury mechanisms for anterior cruciate ligament injuries in team handball a systematic video analysis. *The American Journal of Sports Medicine* 32:1002-1012.
- [3] Krosshaug T, Nakamae A, Boden BP, Engebretsen L, Smith G, Slauterbeck JR, Hewett TE, Bahr R. 2007. Mechanisms of anterior cruciate ligament injury in basketball video analysis of 39 cases. *The American Journal of Sports Medicine* 35: 359-367.
- [4] Yu, B., Garrett, W. E. 2007. Mechanisms of non-contact ACL injuries. *British Journal of Sports Medicine*, 41(suppl 1), i47-i51.
- [5] Spindler KP, Wright RW. 2008. Anterior cruciate ligament tear. *New England Journal of Medicine*, 359:2135-2142.
- [6] Levine JW, Kiapour AM, Quatman CE, Wordeman SC, Goel VK, Hewett TE, Demetropoulos CK. 2013. Clinically relevant injury patterns after an anterior cruciate ligament injury provide insight into injury mechanisms. *The American Journal of Sports Medicine* 41:385-395.
- [7] Siegel L, Vandenakker-Albanese C, Siegel D. 2012. Anterior cruciate ligament injuries: anatomy, physiology, biomechanics, and management. *Clinical Journal of Sport Medicine* 22:349-355.
- [8] Shelbourne KD, Rowdon GA. 1994. Anterior cruciate ligament injury. *Sports Medicine* 17:132-140.
- [9] Shelbourne KD, Nitz P. 1990. Accelerated rehabilitation after anterior cruciate ligament reconstruction. *The American Journal of Sports Medicine* 18:292-299.
- [10] Fisher AC, Mullins SA, Frye, P.A. 1993. Athletic trainers' attitudes and judgments of injured athletes' rehabilitation adherence. *Journal of Athletic Training* 28:43.
- [11] Taylor AH, May S. 1996. Threat and coping appraisal as determinants of compliance with sports injury rehabilitation: An application of protection motivation theory. *Journal of Sports Sciences* 14:471-482.
- [12] Brewer B W. 1998. Adherence to sport injury rehabilitation programs. *Journal of Applied Sport Psychology* 10:70-82.
- [13] Ganguly P. 2010. Teaching and Learning of Anatomy in the 21st Century: Direction and the Strategies. *The Open Medical Education Journal* 3:5-10.
- [14] Kluchova D, Bridger J, Parkin IG. 2000. Anatomy into the future. *Bratisl Lek Listy*. 101: 626-629
- [15] Turney BW. 2007. Anatomy in a modern medical curriculum. *Ann R Coll Surg Engl*. 89:104-107
- [16] Sugand K, Abrahams P, Khurana A. 2010. The anatomy of anatomy: A review for its modernization. *Anatomical Sciences Educatio*, 3:83-93.
- [17] Utting M, Willan P. 1995.. What future for dissection in courses of human topographical anatomy in universities in the UK. *Clinical Anatomy* 8:414-417.
- [18] Dangerfield P, Bradley P, Gibbs T. 2000. Learning gross anatomy in a clinical skills course. *Clinical Anatomy* 13:444-447.
- [19] Spitzer V, Ackerman A, Scherzinger A, Whitlock D. 1996. The Visible Human Male: A Technical Report. *Journal of American Medical Informatics Association* 3:118-130.
- [20] Anderson P, Chapman P, Ma M, Rea P. 2013. Real-time Medical Visualization of Human Head and Neck Anatomy and its Applications for Dental Training and Simulation. *Current Medical Imaging Reviews*. ISSN 1573-4056 (In Press).
- [21] Ackerman M. 1998. The Visible Human Project. *Proceedings of the IEEE*, 86:504-511.
- [22] Khaund R, Flynn S. 2005. Iliotibial Band Syndrome: A Common Source of Knee Pain. *American Family Physician* 71:1545-1550.
- [23] Beveridge E, Ma M, Rea, P., Bale K, and Anderson P. 2013. *3D visualisation for education, diagnosis and treatment of Iliotibial band syndrome*. In: 2013 International Conference on Computer Medical Applications (ICCMA), Sousse, Tunisia, 20-22 Jan 2013. IEEE, Sousse, Tunisia, pp. 1-6. ISBN 9781467352130
- [24] Treleaven P, Wells J. 2007. 3D Body Scanning and Healthcare Applications. IEEE Computer Society.