

Case Report

Endoscopic Management of Colonic Perforation Due to Biliary Stent Migration

Emin Bodakçi

Department of Gastroenterology, Ankara University, Ankara, Türkiye

Email address:

doctor.emin.0903@hotmail.com

To cite this article:

Emin Bodakçi. Endoscopic Management of Colonic Perforation Due to Biliary Stent Migration. *International Journal of Gastroenterology*. Vol. 7, No. 2, 2023, pp. 54-56. doi: 10.11648/j.ijg.20230702.13

Received: July 31, 2023; **Accepted:** August 21, 2023; **Published:** August 31, 2023

Abstract: Biliary stenting is an indispensable procedure in malignant and benign obstructions. Stent migration is seen in approximately 5-10% of patients with biliary stent placement. Duodenal, ileal, jejunal and colon perforation due to biliary stent migration has been reported in less than 1% of cases. In this case, a 70-year-old female patient who had a biliary stent implanted 7 months ago due to choledocholithiasis was admitted with the complaint of abdominal pain. Computed tomography showed a plastic biliary stent with one end perforating the lumen of the sigmoid colon and the other end perforating the colon wall and peritoneal cavity. The patient was successfully removed endoscopically due to the absence of abscess and peritonitis clinic. Biliary stenting is an indispensable procedure in malignant and benign obstructions. Stent migration is seen in approximately 5-10% of biliary stent patients. Duodenal, ileal, jejunal and colonic perforation due to biliary stent migration tubules in less than 1% of cases. In this case, a 70-year-old female patient who had a biliary stent inserted 7 months ago due to choledocholithiasis applied with the complaint of abdominal pain. Computed tomography showed a plastic biliary stent with one end in the lumen of the sigmoid colon and the other end perforating the colon wall and peritoneal wall. Due to the absence of abscess and peritonitis clinic on computed tomography, it was decided to plan an endoscopic procedure for the patient. In rectosigmoidoscopy, a plastic stent perforating the sigmoid colon wall and one end in the peritoneum was observed. The stent was removed with foreign body forceps. The perforation area formed by the stent was closed with a hemoclip. It should not be forgotten that stent migration and related perforation may occur in abdominal pain in patients with a history of biliary stent. Perforation cases without abscess and peritonitis clinic should be evaluated in terms of endoscopic treatments, as in our case.

Keywords: Biliary Stent, Colonic Perforation, Endoscopic Management

1. Introduction

Stenting with endoscopic retrograde cholangiopancreatography (ERCP) is one of the main treatment options in benign and malignant obstructive jaundice. Complications due to biliary stenting are 8-10%, mortality is below 1%. [1-2] Stent migration is seen between 5-10%, most of the stents are expelled from the rectum with peristaltic movements after migration. [2-4] Intestinal perforation may occur as a result of stent migration, and this rate is below 1%. [5] In this article, a case of sigmoid colon perforation that developed after biliary stent migration is presented.

2. Case Presentation

A 70-year-old female patient presented with complaints of pain localized in the lower abdominal quadrants and increasing during defecation for 15 days. It was learned that ERCP was performed due to choledocholithiasis 7 months ago and a 10 french, 10 cm plastic stent was placed in the patient who had no additional disease in his history. No abnormality was observed in laboratory parameters except for C-reactive protein (CRP) 5.7 mg/dl (0-5), White blood cell (WBC) 12x10⁹/l. Computed tomography (CT) was performed for the etiological evaluation of the patient. In the CT images, a foreign body was observed in the sigmoid colon, with one end

in the lumen and one end perforating the wall and reaching the peritoneal cavity (Figure 1). It was thought that the patient may have a perforation due to stent migration in the foreground. Since free air and abscess appearance were not observed in the abdomen, rectosigmoidoscopy was performed under fluoroscopy to remove the stent. In colonoscopy, a plastic biliary stent with one end penetrating the wall and one end in the lumen was observed (Figure 2). The stent was caught and removed with foreign body forceps. Two 16 mm hemoclips were placed on the defective mucosal area. The colon segment from which the stent was removed was filled with contrast material and evaluated for possible perforation. Contrast extralumination was not observed in the examination performed with scopy. No additional pathology was observed in the patient during the follow-ups. He was discharged from the service 2 days later.

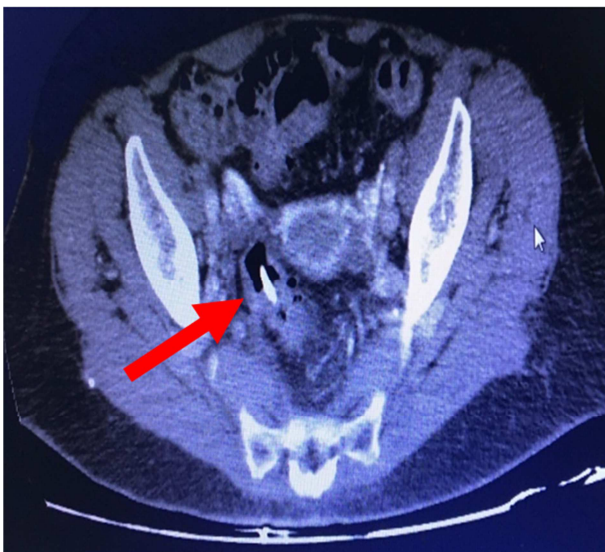


Figure 1. Foreign body in the colon wall.

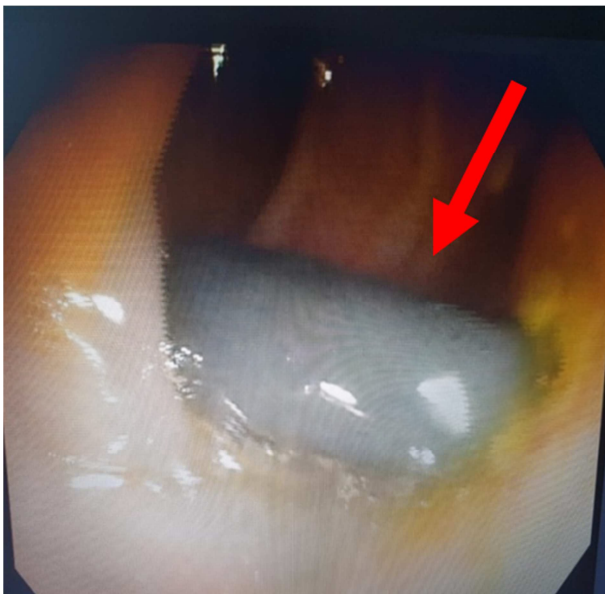


Figure 2. Plastic stent seen in colonoscopy.

3. Discussion

Biliary stent placement continues to be an effective method in benign biliary problems because its efficiency is quite high (90%) and complications are relatively low. It is also accepted as an alternative treatment option in malignant biliary strictures. Despite its high efficiency, it has side effects such as 26% cholangitis, 7% pancreatitis, 2% perforation, 2% bleeding. [6-8]

The frequency of stent migration is 5-10%. Most of the migrated stents are expelled by passage or remain asymptotically in the intestinal lumen. [2-4] Post migration perforation may occur, most commonly in the duodenum (90%), then in the small intestine, and least in the colon. [9] Stent-related perforations can be intraperitoneal or retroperitoneal. While the clinic may be subtle in retroperitoneal perforations, the clinical manifestation of peritonitis is more prominent in intraperitoneal perforations. [10-11]

Computed tomography is the best imaging method in stent perforation. [12]

In patients with good general condition, closure of the perforation with an endoscopic clip and, if present, percutaneous evacuation of the collection may be a treatment option. [13-14] In our patient, there was no collection in the abdomen and the perforation line was closed with a clip.

It should be kept in mind that stent migration and perforation may occur in stented cases presenting with abdominal pain. For the detection of migration, perforation status and localization, it is necessary to evaluate with computed tomography and to evaluate the option of clip closure in appropriate patients or surgery according to the patient's condition.

4. Conclusion

Biliary stenting, which is used in the treatment of many biliary obstructions, has some complications. One of them is perforations that develop after stent migration. It should be kept in mind that there may be colon perforation in abdominal pain developing after biliary stents. Complications can be minimized when these perforations are detected early and managed with appropriate treatment. Perforation cases that do not develop peritonitis and intra-abdominal abscess can be treated with endoscopic methods.

References

- [1] Johanson JF, Schmalz MJ, Geenen JE. Incidence and risk for biliary and pancreatic stent migration. *Gastrointest Endosc* 1992; 38: 314-6.
- [2] Odemiş B, Parlak E, et al. Migration of biliary plastic stents: experience of a tertiary center. *Surg Endosc* 2009; 23: 769-75.
- [3] Wurbs D. The development of biliary drainage and stenting. *Endoscopy* 1998; 30: A202-6. 5.
- [4] Chaurasia OP, Rauws EA, Fockens P, Huibregtse K. Endoscopic techniques for retrieval of proximally migrated biliary stents: the Amsterdam experience. *Gastrointest Endosc* 1999; 50: 780-5.

- [5] Saranga Bharathi R, Rao P, Ghosh K. Iatrogenic duodenal perforations caused by endoscopic biliary stenting and stent migration: an update. *Endoscopy* 2006; 38: 1271-4.
- [6] P. R. Mueller, J. T. Ferrucci, S. K. Teplick, et al. Biliary stent endoprosthesis: analysis of complications in 113 patients. *Radiology* 1985; 156: 637-639.
- [7] N. A. Van der Gaag, E. A. Rauws, C. H. van Eijck, et al. Preoperative biliary drainage for cancer of the head of the pancreas *NEJM* 2010; 362: 129-137.
- [8] D. J. Gouma Stent versus surgery HPB (Oxford). 2007; 9: 408-413.
- [9] E. M. Anderson, J. Phillips-Hughes, R. Chapman. Sigmoid colonic perforation and pelvic abscess complicating biliary stent migration. *Abdom Imaging*. 2007; 32: 317-319.
- [10] Storkson RH, Edwin B, Reiertsen O, et al. Gut perforation caused by biliary endoprosthesis. *Endoscopy* 2000; 32: 87-9.
- [11] Miller G, Yim D, Macari M, et al. Retroperitoneal perforation of the duodenum from biliary stent erosion. *Curr Surg* 2005; 62: 512-5.
- [12] Novacek G, Hormann M, Puig S, et al. Duodenal perforation secondary to placement of a biliary endoprosthesis diagnosed by multislice computed tomography. *Endoscopy* 2002; 34: 351.
- [13] Katsinelos P, Paroutoglou G, Papaziogas B, et al. Treatment of a duodenal perforation secondary to endoscopic sphincterotomy with clips. *World J Gastroenterol* 2005; 11: 6232-4.
- [14] Seibert DG. Use of an endoscopic clipping device to repair a duodenal perforation. *Endoscopy* 2003; 35: 189.