



Review Article

# Ruptured Hepatocellular Carcinoma-Experience in a Tertiary Centre in Western Australia

Sarah Ng<sup>1,\*</sup>, Justin Chin<sup>1</sup>, Sudhakar Rao<sup>2</sup>, Nick Kontorinis<sup>1</sup>, James Anderson<sup>3</sup>, Suresh Navadgi<sup>2</sup>, Jee Kong<sup>1</sup>, Adam Doyle<sup>1</sup>, Wendy Cheng<sup>1,4,5</sup>

<sup>1</sup>Department of Gastroenterology & Hepatology, Royal Perth Hospital, Perth, Australia

<sup>2</sup>Department of General Surgery, Royal Perth Hospital, Perth, Australia

<sup>3</sup>Department of Radiology, Royal Perth Hospital, Perth, Australia

<sup>4</sup>School of Medicine and Health Services, Edith Cowan University, Perth, Australia

<sup>5</sup>Department of Medicine, University of Western Australia, Perth, Australia

## Email address:

[Sarah.ng@health.wa.gov.au](mailto:Sarah.ng@health.wa.gov.au) (S. Ng)

\*Corresponding author

## To cite this article:

Sarah Ng, Justin Chin, Sudhakar Rao, Nick Kontorinis, James Anderson, Suresh Navadgi, Jee Kong, Adam Doyle, Wendy Cheng. Ruptured Hepatocellular Carcinoma-Experience in a Tertiary Centre in Western Australia. *International Journal of Gastroenterology*.

Vol. 2, No. 1, 2018, pp. 18-23. doi: 10.11648/j.ijg.20180201.14

**Received:** September 15, 2018; **Accepted:** October 8, 2018; **Published:** November 7, 2018

**Abstract:** Hepatocellular carcinoma (HCC) is a leading cause of cancer-related deaths worldwide. Spontaneous tumour rupture (STR) is uncommon, with incidence rates around 10-15% in Asia, but below 3% in Western countries. Nonetheless, serious complications lead to high mortality rates. To our knowledge, experience of HCC rupture has not been published in Australia. We identified 9 retrospective cases of ruptured HCC from 2008 to 2017 through patient case notes, electronic laboratory system, and imaging reports. Our case series presents 8 male and 1 female patient with a mean age of 56 years, and a median 11 month follow-up period. Sixty-six percent of patients were non-cirrhotic, and 33% cirrhotic, with a median post-tumour rupture survival rate of 10 months and 12 months, respectively. Seventy-eight percent of patients presented with abdominal pain and a mean tumour size of 8cm at time of rupture. Initial management involved: trans-arterial chemoembolisation (TACE)/ trans-arterial embolisation (TAE) in 4 patients, emergency hepatic resection in 3 patients, sorafenib in 1 patient and conservative/ supportive treatment in 1 patient. Reasons for our low HCC rupture incidence at 0.3% could be due to: none of our patients experiencing rebleeding (one of the common causes of mortality); strict surveillance programmes in Australia identifying early tumours; and majority of our patients being younger and non-cirrhotic with a better underlying liver reserve at time of rupture, and therefore improved outcomes.

**Keywords:** Ruptured Hepatocellular Carcinoma, Trans-Arterial Chemoembolisation, Trans-Arterial Embolisation

## 1. Introduction

Hepatocellular carcinoma (HCC) is third leading cause of cancer-related deaths worldwide, with 700,000 deaths each year [1]. HCC typically develops on a background of liver cirrhosis in 85-95% of cases [2] and is particularly common in countries with endemic hepatitis B virus (HBV) and hepatitis C virus (HCV).

Spontaneous tumour rupture (STR) is uncommon but a potentially serious complication associated with a high risk of

mortality. STR commonly presents as abdominal pain in 66-100% of patients [3]. In Asia, incidence of STR is 10-15%[4] with a global mortality rate in cirrhotic patients up to 38%[5, 6]. In Western countries, the reported incidence of rupture is much lower at below 3%[7]. The American Joint Committee on Cancer/Union for International Cancer Control (AJCC/UICC) define ruptured HCC as a T4 lesion and is staged similar to tumours with vascular or bile duct invasion [8].

In the management of ruptured HCC, the primary concern is

haemostasis followed by tumour treatment. Treatment options include: conservative management, trans-arterial chemoembolisation (TACE)/ trans-arterial embolisation (TAE), emergency hepatectomy or staged hepatectomy.

To our knowledge, experience in ruptured HCC from Australia has not been published previously. This report is aimed to compare experience to current literature.

## 2. Method

This retrospective review included all patients with spontaneous HCC rupture from 2008-2017 from Royal Perth Hospital, Western Australia. Data were extracted from case notes, electronic laboratory system, and imaging reports. HCC was initially diagnosed in accordance with AASLD guidelines [9] – either from compatible CT or MR imaging (arterial phase enhancement with venous phase washout), or histological assessment of radiologically indeterminate lesions. Rupture was defined radiologically, with cross-sectional imaging suggesting haemoperitoneum, liver capsule breach, and/or contrast extravasation from a HCC lesion.

Details of patient demographics, co-morbidities, pre-existing liver disease, cirrhosis status, alpha-fetoprotein, size and location of liver tumour, treatment strategies and outcomes were recorded.

## 3. Results

### 3.1. Patient Characteristics

During the 10 year study period, 312 patients with HCC were identified. A total of 9 cases (8 male and 1 female) of ruptured HCC were identified, giving an incidence of 0.3% per year. The median follow-up period was 11 months (range 7 days to 10 years).

Table 1. highlights the characteristics of the patients. Median age was 56 years (IQR 21). Only 3 (33%) patients had histological evidence of liver cirrhosis, and all 3 were male. Of the patients with cirrhosis, median Child-Pugh (CP) score was

8 (range 6 to 13).

### 3.2. Tumour Characteristics and Prior Imaging

Tumour size ranged from 3.9cm to 10.9cm (mean 8cm) at point of rupture, and 5 out of 9 cases had further satellite lesions localised to the same side as the primary tumour. Four patients had prior cross sectional imaging for HCC surveillance for either known liver cirrhosis or chronic HBV infection. One HBV patient was noted to have a 2.8cm segment V HCC 6 months beforehand but he opted to explore herbal medications. Another HBV patient of African descent was a new referral noted to have a 10.9cm ruptured HCC on CT imaging 2 weeks prior and booked for resection. However was noted to have a ruptured tumour intra-operatively. One cirrhotic patient was noted to have a 10mm lesion 15 months prior but unfortunately lost to follow-up and only represented to hospital at time of rupture where tumour had grown to 5.5cm. The fourth patient had known HCV related cirrhosis and referred with multifocal HCC (largest at 8cm). He was planned for TACE but due to mental health issues did not attend numerous appointments. He unfortunately presented 3 months later with tumour rupture and died within 7 days from acute liver failure.

### 3.3. Presentation of Patients

Of the patients, 78% (7/9) presented with some extent of abdominal pain localised to right upper quadrant, and of the 7 patients, 3 presented with shock. One patient who did not report pain was asymptomatic and only found to have tumour rupture laparoscopically in theatre for elective HCC resection. The median  $\alpha$ -fetoprotein (AFP) was 58 $\mu$ g/l (range 6 to 35,000 $\mu$ g/l). It is noteworthy that AFP mean was considerably higher in non-cirrhotic rupture patients, with the two highest AFP values at 10,000 $\mu$ g/l and 35,000 $\mu$ g/l. Seven of 8 patients had cross-sectional imaging showing tumour rupture defined as “liver capsular breach” or showing evidence of “haemoperitoneum”. The remaining patient was diagnosed with tumour rupture intra-operatively.

Table 1. Patient characteristics.

	All patients (N=9) (n%)	Cirrhotic (N=3) (n%)	Non-cirrhotic (N=6) (n%)
Age (years), median	56	59	49
sex			
male	8 (89)	3 (100)	5 (83)
female	1 (11)	0	1 (17)
Race			
Caucasian	3 (33)	1 (33)	2 (33)
Other	6 (67)	2 (67)	4 (67)
Underlying liver disease			
HBV	3 (33)	0	3 (50)
HCV	1 (11)	1 (33)	0
ETOH	1 (11)	0	1 (17)
HBV+ETOH	2 (22)	2 (67)	0
Nil	2 (22)	0	2 (33)
Child-Pugh score			
Class A		1 (33)	
Class B		1 (33)	
Class B		1 (33)	
Haemoglobin <80g/l	2 (22)	1 (33)	1 (17)
Bilirubin >50 $\mu$ mol/l	1 (11)	1 (33)	0

	All patients (N=9) (n%)	Cirrhotic (N=3) (n%)	Non-cirrhotic (N=6) (n%)
$\alpha$ -fetoprotein $\mu\text{g/l}$			
<100	6 (67)	2 (67)	4 (67)
100-1000	1 (11)	1 (33)	0
>1000	2 (22)	0	2 (33)
Tumour size (cm), mean	8.0	7.7	8.1
Tumour location			
left	3 (33)	1 (33)	2 (33)
right	6 (67)	2 (67)	4 (67)
bilateral	0	0	0
multifocal	5 (55)	2 (67)	3 (50)
First-line treatment			
TACE/TAE	4 (44)	2 (67)	2 (33)
Resection	3 (33)	0	3 (50)
Sorafenib	1 (11)	1 (33)	0
No treatment	1 (11)	0	1 (17)
Development of intraperitoneal metastasis			
Yes	2 (22)	0	2 (22)
No	7 (78)	3 (100)	4 (44)
Progression or recurrence			
Yes	6 (67)	2 (67)	4 (67)
No	3 (33)	1 (33)	2 (33)
Outcome			
Death			
<1 month	1 (11)	1 (33)	0
1-12 months	2 (22)	1 (33)	1 (17)
12-24 months	2 (22)	1 (33)	2 (33)
>24 months	2 (22)	0	1 (17)
Alive presently	2 (22)	0	2 (33)

HBV= hepatitis B virus, HCV= hepatitis C virus, ETOH= alcohol, TACE= trans-arterial chemoembolisation, TAE= trans-arterial embolisation

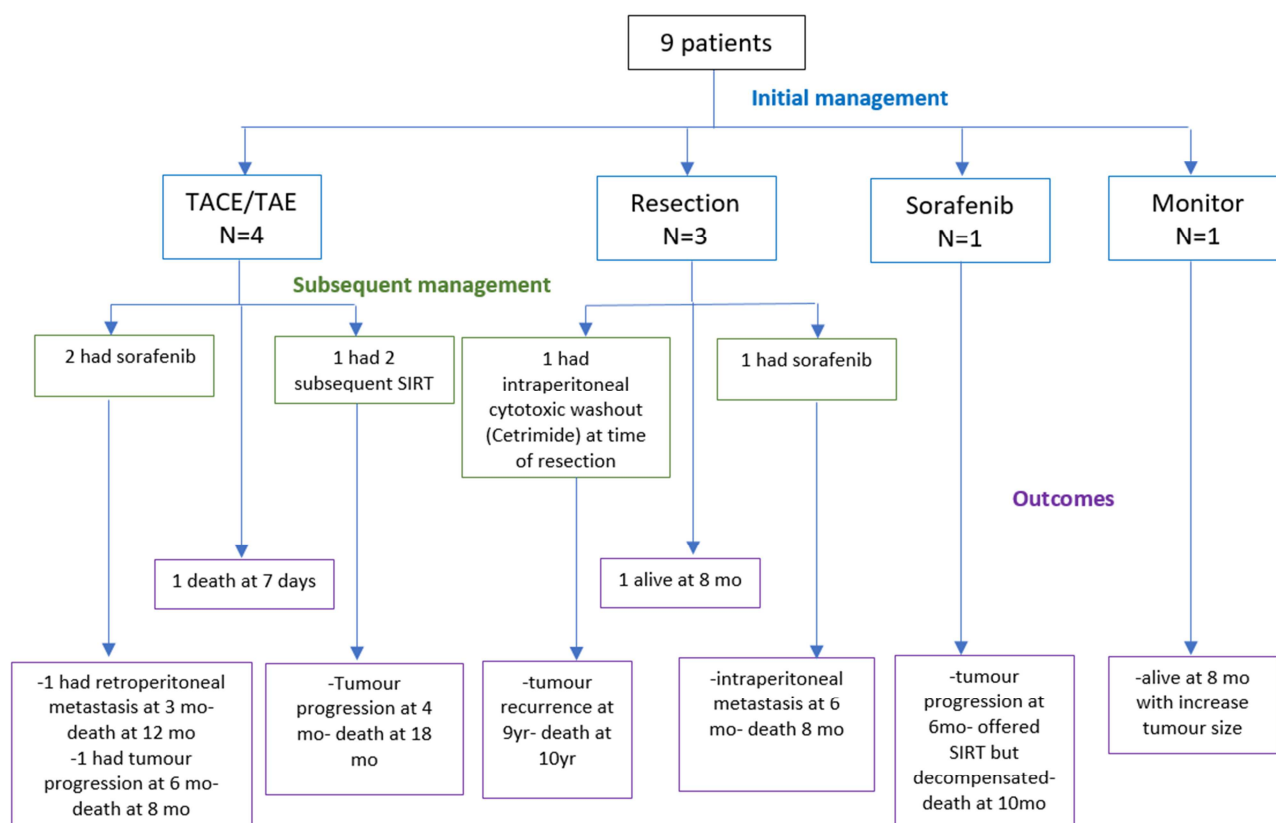


Figure 1. Patient treatment and outcomes.

### **3.4. Initial Management, Subsequent Treatment and Outcomes**

Management and patient outcomes are summarised in figure 1.

#### **3.4.1. TACE/TAE**

Four patients were treated with TACE/TAE (2/4 were cirrhotic). One cirrhotic patient developed acute liver failure and died within 7 days of presentation. The remaining 3 patients all developed tumour recurrence or metastatic disease within 6 months. Mean survival for these was 9.6 months.

#### **3.4.2. Resection**

Three patients had emergency liver resections at time of rupture, none of which were cirrhotic. Of these, one subsequently treated with sorafenib but died at 8 months. One had intraperitoneal washout with cetrimide and survived 10 years. This patient was 65 years old at time of diagnosis with underlying HBV, hypertension and type 2 diabetes mellitus. He continued to have 3 monthly cross-sectional image surveillance initially and then 6 monthly surveillance. One patient is currently alive and well with no evidence of recurrence on recent cross-sectional imaging at 8 months.

#### **3.4.3. Sorafenib**

One cirrhotic patient was treated with sorafenib at time of rupture but had disease progression at 6 months on CT. He was considered for selective internal radiation therapy (SIRT) but decompensated and died at 10 months.

#### **3.4.4. Conservative/Monitoring**

One patient with no underlying liver disease presented with abdominal pain. CT abdomen showed a 9cm x 6.8cm x 6.5cm lesion suggestive of HCC with capsular breach. Given he was haemodynamically stable, the patient opted for monitoring and declined surgery. 3 month follow-up showed no interval progression of lesion but 7 month follow-up scan shows lesion progression to 8.5 cm x 8.0cm x 8.4cm. This 58 year old gentleman continues to be clinically well at 8 months.

## **4. Discussion and Review of the Literature**

### **4.1. Clinical Presentation**

Most commonly patients present with acute abdominal pain (66-100%)[3], which correlates with 6/9 (67%) of our patients presenting with right upper quadrant pain. A large Chinese case series of 4209 patients by Zhu et al showed several risk factors for HCC rupture, including liver cirrhosis, hypertension, tumour size  $\geq 5$ cm, vascular thrombosis, tumour protrusion outside the liver and extrahepatic invasion of HCC [10]. Eight of our 9 patients had tumour sizes over 5cm (one

tumour 3.9cm), and 4/9 (44%) had underlying hypertension with or without cirrhosis, which highlights whether more stringent blood pressure control is required in HCC patients.

### **4.2. Mechanism of Rupture**

The mechanism of spontaneous rupture is still unclear. Zhu et al [11] proposed a theory of vascular dysfunction caused by breakdown of elastin and degradation of type IV collagen. As a result, blood vessels stiffen and weaken and are prone to rupture, especially when vascular load increases with hypertension or minor trauma. 5 of our 9 patients had underlying hypertension, again highlighting better blood pressure control. Other theories of rupture include rapid growth of tumour and necrosis [11, 12], increased intratumour pressure with occlusion of hepatic veins by tumour thrombus or invasion [13], and coagulopathy as a result of chronic liver disease [14].

### **4.3. Clinical Diagnosis**

Clinical diagnosis has improved owing to imaging modalities such as ultrasonography (US) and computed tomography (CT), which pick up 75% of ruptured HCC [3]. Seven of our 9 cases were diagnosed on CT at time of presentation but one patient was found to have a ruptured HCC intraoperatively during laparotomy for an elective HCC resection. Surprisingly, CT performed 3 weeks prior revealed an 10.9cm segment IV HCC with no evidence of tumour rupture. It remains unclear whether the tumour rupture occurred in the interim, intraoperatively or just was not identified on CT. Literature shows that a minority of cases are discovered on emergency exploratory laparotomy for abdominal pain [5, 15], and although CT is able to assess tumour size, location and capsular breach, the site of haemorrhage is rarely identified [16].

Our incidence of HCC rupture was 0.3%, which is markedly lower than previously published case series. This may be due to stringent imaging surveillance programmes in Australia picking up small tumours and treatment offered prior to them reaching sizes at risk of rupture. In HBV patients (cirrhotic or non-cirrhotic), all males undergo 6-monthly US and AFP surveillance for HCC at 40 years and females at 50 years. In Afro-Caribbean patients, surveillance starts at age 20. Cirrhotic patients of all aetiologies undergo 6-monthly surveillance at time of diagnosis. Two of 9 patients had radiological evidence of HCC on cross-sectional imaging 4-6 months prior to rupture, however one opted to seek conservative management with herbal medicines, and the other patient declined to attend clinic due to mental health problems. One patient had radiological evidence of HCC (10mm lesion) 15 months prior but was lost to follow-up and re-presented with a 5.5cm rupture. The other 5 patients had never undergone prior abdominal imaging.

**Table 2.** *Studies from Western countries.*

Author	Year	Country	No. patients	No. cirrhotic patients (%)	Median survival (months)
Our case series	2018	Australia	9	3 (37)	Cirrhotic: 10; non-cirrhotic: 12
Schwarz et al [6]	2018	France/Italy	138	58 (42)	NA
Rijckborst et al [17]	2016	Netherlands	11	6 (55)	TACE: >12 Conservative treatment: 2.5
Tarantino et al [18]	2011	Italy	24	24 (100)	Resection: 14; TACE: 4; conservative: 0.3
Battula et al [7]	2009	UK	21	14 (67)	Cirrhotic: <1 Non-cirrhotic: 20
Buczowski et al [19]	2006	North America	30	17 (57)	Emergency resection: 12; delayed resection: 9
Recordare et al [20]	2002	Italy	11	10 (91)	6 overall
Castells et al [21]	2001	Spain	7	7 (100)	9 overall
Vergara et al [15]	2000	Italy	6	5 (83)	32 overall
Vivarelli et al [22]	1995	Italy	8	5 (63)	9 overall
Cherqui et al [23]	1993	France	5	5 (100)	6 overall

#### 4.4. Mortality

Despite improvements in management of tumour rupture, the quoted mortality still ranges from 16-38% [7, 15, 24, 25, 26]. Death is most commonly due to bleeding or re-bleeding in 34%[27] during the acute phase. Risk factors for rebleeding include severity of bleeding on admission (haemorrhagic shock, ICU admission), as well as general condition of the patient (age, renal insufficiency) [6]. None of our patients (0%) had rebleeding events, which could be due to our younger patient group (median age 55 year) compared to other studies, and only 2 patients presenting with shock. The majority of our patients were non-cirrhotic (67%) with a better functional baseline, but comparisons with other Western studies was difficult as survival of cirrhotic and non-cirrhotic patients were grouped together, as summarised in Table 2.

Our only patient (11%) who died during initial presentation despite successful cessation of haemorrhage, developed acute liver failure on a background of cirrhosis and had a bilirubin of 120µmol/L. Literature suggests that liver failure, occurs in 12% to 42% of patients during the initial phase [28], and bilirubin 50µmol/L is seen as a poor prognostic factor [4].

The majority of case series currently published (Western and Asian populations) found that HCC rupture was more common in cirrhotic patients (Table. 3) but interestingly our data showed a majority of non-cirrhotic patients at 63%. Only 1 other case series with a minority of 42% cirrhotic patients was the European case series published by Schwarz et al [6] in early 2018. This may again reflect that better imaging modalities and regular surveillance in cirrhotic patients may be picking up small HCCs, and the ones that do present with rupture are non-cirrhotic patients with large tumours who had no indication for surveillance in the first place.

## 5. Conclusion

Spontaneous rupture of HCC is an uncommon but life threatening complication of HCC, especially in Western countries. Strict surveillance programmes in Australia, picking up early tumours, may have a major role in a reduced incidence of HCC rupture down to 0.3%. Management of acute bleeding

has improved with new advances in treatment but despite best efforts, a small number of patients have intra-peritoneal spread and majority will have tumour progression. Rupture in non-cirrhotic patients appears to have a much better outcome.

## References

- [1] Ferlay J, Soerjomataram I, Dikshit R, et al. Cancer incidence and mortality worldwide: sources, methods and major patterns in GLOBOCAN 2012. *Int J Cancer*. 2015 Mar 1; 136 (5):E359-86. doi: 10.1002/ijc.29210. PubMed PMID: 25220842.
- [2] Fattovich G, Stroffolini T, Zagni I, et al. Hepatocellular carcinoma in cirrhosis: incidence and risk factors. *Gastroenterology*. 2004 Nov; 127 (5 Suppl 1):S35-50. PubMed PMID: 15508101.
- [3] Yoshida H, Mamada Y, Taniai N, et al. Spontaneous ruptured hepatocellular carcinoma. *Hepatol Res*. 2016 Jan; 46 (1):13-21. doi: 10.1111/hepr.12498. PubMed PMID: 25631290.
- [4] Lai EC, Lau WY. Spontaneous rupture of hepatocellular carcinoma: a systematic review. *Arch Surg*. 2006 Feb; 141 (2):191-8. doi: 10.1001/archsurg.141.2.191. PubMed PMID: 16490898.
- [5] Liu CL, Fan ST, Lo CM, et al. Management of spontaneous rupture of hepatocellular carcinoma: single-center experience. *J Clin Oncol*. 2001 Sep 1; 19 (17):3725-32. doi: 10.1200/JCO.2001.19.17.3725. PubMed PMID: 11533094.
- [6] Schwarz L, Bubenheim M, Zemour J, et al. Bleeding Recurrence and Mortality Following Interventional Management of Spontaneous HCC Rupture: Results of a Multicenter European Study. *World J Surg*. 2018 Jan; 42 (1):225-232. doi: 10.1007/s00268-017-4163-8. PubMed PMID: 28799103.
- [7] Battula N, Madanur M, Priest O, et al. Spontaneous rupture of hepatocellular carcinoma: a Western experience. *Am J Surg*. 2009 Feb; 197 (2):164-7. doi: 10.1016/j.amjsurg.2007.10.016. PubMed PMID: 18926518.
- [8] Hari DM, Leung AM, Lee JH, et al. AJCC Cancer Staging Manual 7th edition criteria for colon cancer: do the complex modifications improve prognostic assessment? *J Am Coll Surg*. 2013 Aug; 217 (2):181-90. doi: 10.1016/j.jamcollsurg.2013.04.018. PubMed PMID: 23768788; PubMed Central PMCID: PMC4657944.

- [9] Heimbach JK, Kulik LM, Finn RS, et al. AASLD guidelines for the treatment of hepatocellular carcinoma. *Hepatology*. 2018 Jan; 67 (1):358-380. doi: 10.1002/hep.29086. PubMed PMID: 28130846.
- [10] Zhu Q, Li J, Yan JJ, et al. Predictors and clinical outcomes for spontaneous rupture of hepatocellular carcinoma. *World J Gastroenterol*. 2012 Dec 28; 18 (48):7302-7. doi: 10.3748/wjg.v18.i48.7302. PubMed PMID: 23326137; PubMed Central PMCID: PMC3544034.
- [11] Zhu LX, Geng XP, Fan ST. Spontaneous rupture of hepatocellular carcinoma and vascular injury. *Arch Surg*. 2001 Jun; 136 (6):682-7. PubMed PMID: 11387009.
- [12] Zhu LX, Wang GS, Fan ST. Spontaneous rupture of hepatocellular carcinoma. *Br J Surg*. 1996 May; 83 (5):602-7. PubMed PMID: 8689200.
- [13] Ong GB, Taw JL. Spontaneous rupture of hepatocellular carcinoma. *Br Med J*. 1972 Oct 21; 4 (5833):146-9. PubMed PMID: 4342761; PubMed Central PMCID: PMC3544034.
- [14] Chearanai O, Plengvanit U, Asavanich C, et al. Spontaneous rupture of primary hepatoma: report of 63 cases with particular reference to the pathogenesis and rationale treatment by hepatic artery ligation. *Cancer*. 1983 Apr 15; 51 (8):1532-6. PubMed PMID: 6297703.
- [15] Vergara V, Muratore A, Bouzari H, et al. Spontaneous rupture of hepatocellular carcinoma: surgical resection and long-term survival. *Eur J Surg Oncol*. 2000 Dec; 26 (8):770-2. doi: 10.1053/ejso.2000.1001. PubMed PMID: 11087643.
- [16] Choi BG, Park SH, Byun JY, et al. The findings of ruptured hepatocellular carcinoma on helical CT. *Br J Radiol*. 2001 Feb; 74 (878):142-6. doi: 10.1259/bjr.74.878.740142. PubMed PMID: 11718385.
- [17] Rijckborst V, Ter Borg MJ, Tjwa ET, et al. Short article: Management of ruptured hepatocellular carcinoma in a European tertiary care center. *Eur J Gastroenterol Hepatol*. 2016 Aug; 28 (8):963-6. doi: 10.1097/MEG.0000000000000652. PubMed PMID: 27116657.
- [18] Tarantino L, Sordelli I, Calise F, et al. Prognosis of patients with spontaneous rupture of hepatocellular carcinoma in cirrhosis. *Updates Surg*. 2011 Mar; 63 (1):25-30. doi: 10.1007/s13304-010-0041-8. PubMed PMID: 21258886.
- [19] Buczkowski AK, Kim PT, Ho SG, et al. Multidisciplinary management of ruptured hepatocellular carcinoma. *J Gastrointest Surg*. 2006 Mar; 10 (3):379-86. doi: 10.1016/j.gassur.2005.10.012. PubMed PMID: 16504883.
- [20] Recordare A, Bonariol L, Caratozzolo E, et al. Management of spontaneous bleeding due to hepatocellular carcinoma. *Minerva Chir*. 2002 Jun; 57 (3):347-56. PubMed PMID: 12029230.
- [21] Castells L, Moreiras M, Quiroga S, et al. Hemoperitoneum as a first manifestation of hepatocellular carcinoma in western patients with liver cirrhosis: effectiveness of emergency treatment with transcatheter arterial embolization. *Dig Dis Sci*. 2001 Mar; 46 (3):555-62. PubMed PMID: 11318532.
- [22] Vivarelli M, Cavallari A, Bellusci R, et al. Ruptured hepatocellular carcinoma: an important cause of spontaneous haemoperitoneum in Italy. *Eur J Surg*. 1995 Dec; 161 (12):881-6. PubMed PMID: 8775629.
- [23] Cherqui D, Panis Y, Rotman N, et al. Emergency liver resection for spontaneous rupture of hepatocellular carcinoma complicating cirrhosis. *Br J Surg*. 1993 Jun; 80 (6):747-9. PubMed PMID: 8392424.
- [24] Bassi N, Caratozzolo E, Bonariol L, et al. Management of ruptured hepatocellular carcinoma: implications for therapy. *World J Gastroenterol*. 2010 Mar 14; 16 (10):1221-5. PubMed PMID: 20222165; PubMed Central PMCID: PMC3544034.
- [25] Kung CT, Liu BM, Ng SH, et al. Transcatheter arterial embolization in the emergency department for hemodynamic instability due to ruptured hepatocellular carcinoma: analysis of 167 cases. *AJR Am J Roentgenol*. 2008 Dec; 191 (6):W231-9. doi: 10.2214/AJR.07.3983. PubMed PMID: 19020209.
- [26] Li WH, Cheuk EC, Kowk PC, et al. Survival after transarterial embolization for spontaneous ruptured hepatocellular carcinoma. *J Hepatobiliary Pancreat Surg*. 2009; 16 (4):508-12. doi: 10.1007/s00534-009-0094-6. PubMed PMID: 19381430.
- [27] Moris D, Chakedis J, Sun SH, et al. Management, outcomes, and prognostic factors of ruptured hepatocellular carcinoma: A systematic review. *J Surg Oncol*. 2017 Nov 8. doi: 10.1002/jso.24869. PubMed PMID: 29116644.
- [28] Llovet JM, Zucman-Rossi J, Pikarsky E, et al. Hepatocellular carcinoma. *Nat Rev Dis Primers*. 2016 Apr 14; 2:16018. doi: 10.1038/nrdp.2016.18. PubMed PMID: 27158749.