

Oral Squamous Cell Carcinoma Associated with Papillon-Lefevre Syndrome: Systematic Review and the First Reported Case

Manar A. Abdul Aziz^{1,*}, Mohamed A. Shawky², Mohammed Atef²

¹Oral and Maxillofacial Pathology Department, Faculty of Dentistry, Cairo University, Cairo, Egypt

²Oral and Maxillofacial Surgery Department, Faculty of Dentistry, Cairo University, Cairo, Egypt

Email address:

m.waniss@yahoo.com (M. A. Abdul Aziz), manar.waniss@dentistry.cu.edu.eg (M. A. Abdul Aziz),

m.shawky1993@gmail.com (M. A. Shawky), Zokasur@live.com (M. Atef)

*Corresponding author

To cite this article:

Manar A. Abdul Aziz, Mohamed A. Shawky, Mohammed Atef. Oral Squamous Cell Carcinoma Associated with Papillon-Lefevre Syndrome: Systematic Review and the First Reported Case. *International Journal of Dental Medicine*. Vol. 4, No. 2, 2018, pp. 31-35.

doi: 10.11648/j.ijdm.20180402.11

Received: August 28, 2018; **Accepted:** September 10, 2018; **Published:** October 10, 2018

Abstract: Papillon-Lefèvre syndrome (PLS) is a rare genodermatosis caused by mutation in CTSC gene which is expressed in epithelial cells as well as in various immune cells including PMNs, macrophages, and their precursors. Such mutation results in palmoplantar hyperkeratosis, early onset periodontitis, susceptibility to infection and rarely mucocutaneous carcinomas. In this study, we aim to perform a systematic review on the incidence of oral squamous cell carcinoma in the association with Papillon-Lefevre syndrome and to introduce the first case report. An electronic search without date and language restrictions in three data bases, Pubmed, Cochrane Library, and Google Scholar in addition to a hand-searching were performed in August 2018. The review of the current literature revealed that such association has not been previously reported. We concluded that patients with Papillon-Lefevre syndrome are susceptible to develop different mucocutaneous carcinomas including OSCC.

Keywords: Papillon-Lefevre Syndrome, Oral Squamous Cell Carcinoma, Palmoplantar Keratosis, Periodontitis

1. Introduction

Papillon-Lefèvre syndrome (PLS) is a rare genetic disease that was so-called as it was first described by French physicians, Papillon and Lefèvre. PLS is caused by a defect in CTSC gene located on chromosome 11q14.1-q14.3 expressed mainly by epithelial cells and some immune cells. It is an inherited as an autosomal recessive trait [1, 2] with the increased risk occurs in association with consanguineous marriage [1, 3].

The patho-etiology of PLS may not be clearly understood but it is well known that clinical features varies with the genetic defect and body responses to bacterial and viral infections [1].

Clinically, cutaneous or skin lesions and oral manifestations are observed simultaneously between the ages of 6 months and 4 years, coinciding with the eruption of deciduous teeth [1].

First, thickening of skin occurs followed by a well demarcated palmoplantar hyperkeratosis. The dorsal surface of hands and feet, elbows, knees, legs, and thighs are also affected but with less severity. The trunk is rarely affected. These lesions vary in their presentation ranging from scaly patches, crusted lesions, skin cracking and deep fissuring. Sometimes, the diseased skin may be superimposed infection leading to formation of abscesses. A color changes either depigmentation or hyperpigmentation may be also detected [1, 2].

Intraorally, The main feature of PLS is the severe and early-onset periodontitis. It starts as early as the eruption of deciduous teeth occurs. The gingiva becomes inflamed and swollen, followed by rapid destruction of periodontium leading to premature loss of deciduous teeth. This cycle occurs again with the eruption of permanent teeth causing looseness, hypermobility, drifting and teeth loss. Most of the permanent teeth are lost in the second decade [1-8].

However, Ikeshima (2006) previously reported a PLS case with intact alveolar bone around the permanent posterior teeth (no destruction was detected) [9].

On the other hand, different treatment modalities in the form of scaling and root planning, oral hygiene measures and regular follow-up can eliminate the reservoir of causative organisms, minimize the destruction of periodontium and delay teeth loss [1].

Despite rarity, the patients with PLS may develop different types of mucocutaneous cancers including skin squamous cell carcinoma [4], malignant melanoma [5-7] and eye lesions [10].

2. Methodology

2.1. Search Method for Identification of Studies

This systematic review was conducted depending on the Preferred Reporting Items for Systematic Reviews and Meta-Analysis Equity 2012 Extension checklist.

A comprehensive electronic search without date and language restrictions was performed in August 2018 using three electronic databases: PubMed, Google Scholar and Cochrane Database. One or a combination of the following search terms was used: (Oral squamous cell carcinoma), (OSCC), (Human oral squamous cell carcinoma), (Human OSCC), (Oral cancer), (Head and neck squamous cell carcinoma), (HNSCC), (Papillon Lefevre syndrome), (Papillon-Lefevre syndrome), (Papillon Lefvre) and (PLS) and the Studies detecting the occurrence of OSCC in patients suffering from this Papillon-Lefevre syndrome were considered. The hand-searching was also done.

The reference lists of any relevant study and the reviews on the subject were also evaluated for possible additional studies.

2.2. Study Selection and Data Extraction

Two authors (M. A), (M. S), independently performed the electronic search and evaluated the resultant data.

3. Results

The electronic search using all combinations, except one, showed no entries. The combination of (PLS) and oral cancer resulted in 17 studies. However, all of these studies were excluded after the initial screening of the titles and abstracts. This is because; some studies reported the association of this syndrome with skin and ocular carcinomas while others were totally unrelated to our subject. Such studies did not use PLS as a synonym or abbreviation for Papillon-Lefevre syndrome but for another issues such as plasma lipid.

4. Case Report

A thirty six years old male patient came to the Department of Oral and Maxillofacial Surgery, Faculty of Dental Medicine, Cairo University, complaining of a large painful

swelling in the left side of the palate interfering with deglutition and speech. The duration of this swelling was about 25 days as reported by patient.

Extraoral examination revealed presence of keratotic thickenings in both aspects of patient's hands and in his feet soles. Pitting of some fingernails was detected. Hyperpigmented spots and infectious blister-like foci in his feet were also seen (Fig. 1, 2). Peeling of these scales leaves slight erythema. Patient stated that these thickenings worsen in some months of the year but could not correlate this with certain season.

Regarding his lifestyle, the patient works as a driver and he is a heavy smoker for more than 20 years. Upon asking about his family history, he stated that his parents are relatives. He added that no one in his family, including his parents, has complained of similar symptoms before.

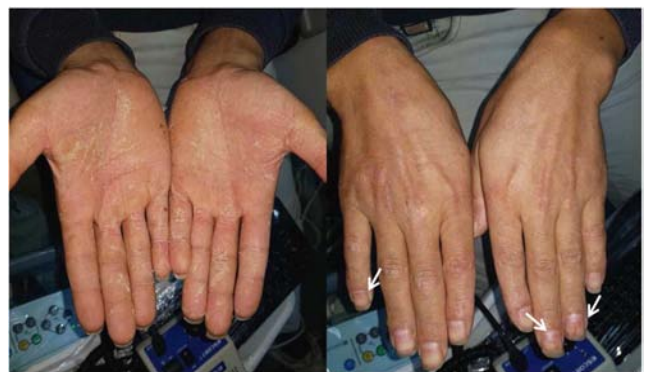

Figure 1. Clinical picture showing hyperkeratosis of dorsal and palmar aspects of patient's hands and nail abnormalities (arrows).

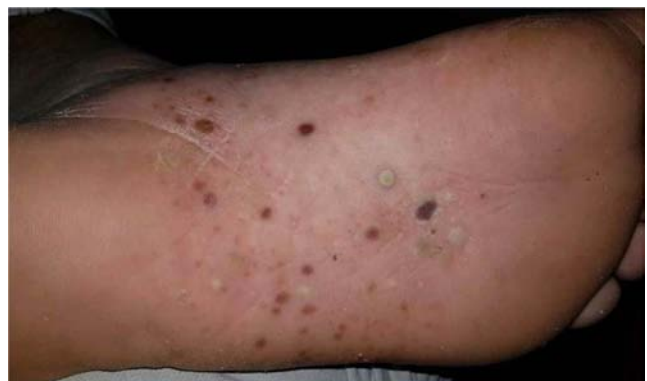

Figure 2. Clinical picture showing hyperkeratosis of plantar aspects of patient's feet. Note hyperpigmented spots and infectious foci.

On intraoral examination, a well circumscribed pink nodule, approximately 1.5 x 1.5 cm in size and round in shape was noted on the left side of the palate. Surface ulcer oozing white cheesy necrotic material was also observed. The lymph node was palpable, movable but not tender (Fig. 3). The underlying palatal bone appeared normal in the radiograph (occlusal radiograph and computed tomography).

In addition, some missing teeth, drifting in anterior teeth and periodontitis (deep pockets) were noticed. As a differential diagnosis, OSCC and salivary gland neoplasm were included.

Correlating the extra and intra oral features supported presence of paraneoplastic syndrome such as Papillon Lefevre syndrome, dyskeratotic congenita, pachyonychia congenita or Chediak Higashi syndrome.

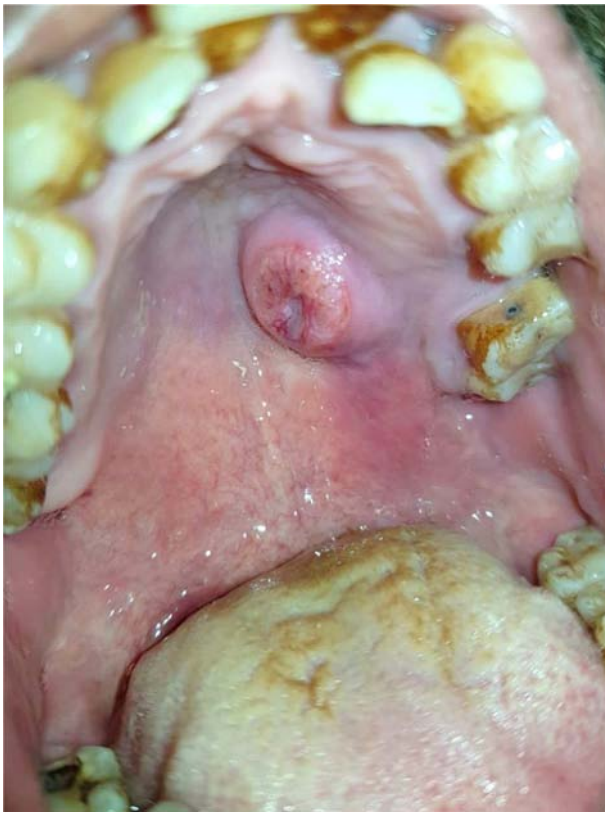


Figure 3. Intra-oral picture showing palatal swelling with central ulceration. Note drifting and crowding of his anterior teeth.

Lab investigations revealed normal blood picture. Magnetic resonance imaging (MRI) was done and revealed absence of any metastatic foci.

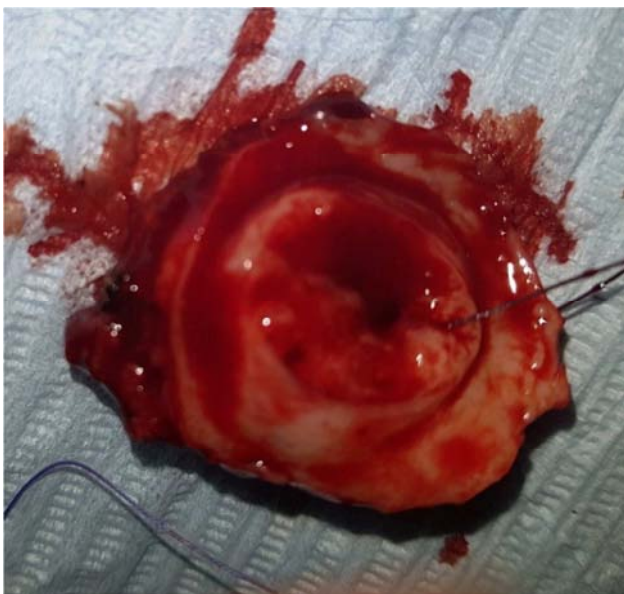

Figure 4. Immediate picture of the excised specimen.

The excisional biopsy with safety margins was performed at the Oral and Maxillofacial Surgery Department, Faculty of Dentistry, Cairo University and the surgical specimen was submitted for microscopic examination in the Department of Oral and Maxillofacial Pathology, Faculty of Dentistry, Cairo University (Fig. 4).

In macroscopic examination, the specimen was received in formalin as one mass. It was rounded in shape, about 2.2 x 2.7 cm in size. The specimen was brownish in color, firm in consistency and solid in cut section (Fig. 5).

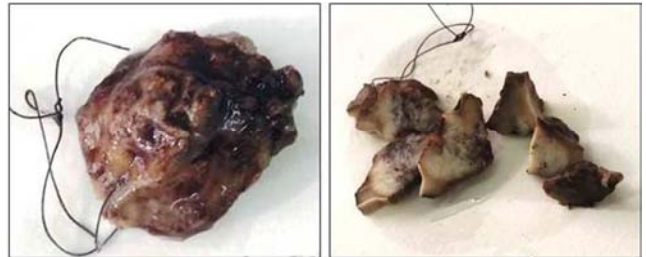

Figure 5. Macroscopic picture of the excised specimen.

Histopathological examination of H&E stained tumor sections revealed a surface stratified squamous epithelium showing signs of dysplasia. Malignant epithelial cell nests with keratin pearls were seen invading through the connective tissue. A chronic inflammatory cell infiltrate was also observed (Fig. 6). Safety margins showed normal stratification of surface epithelium with slight hyperplasia, hyperkeratosis and prominent granular cell layer. No dysplastic features were seen (Fig. 7).

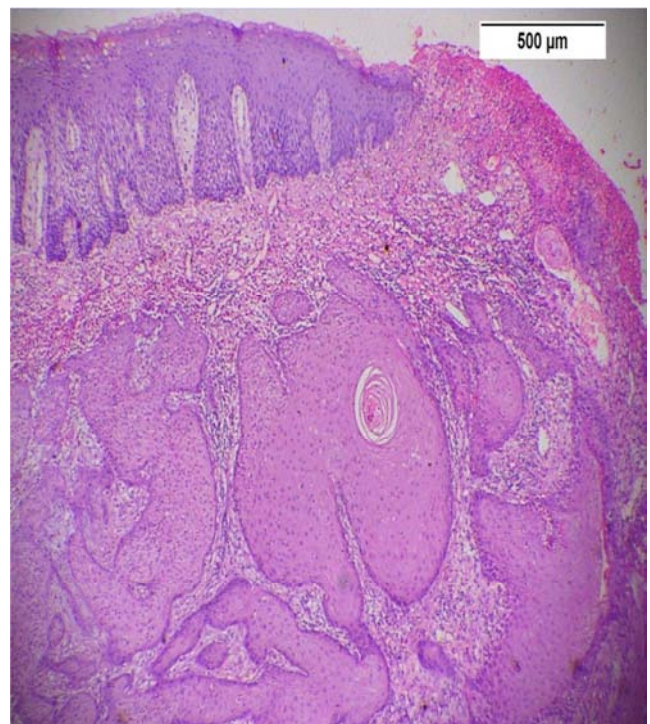


Figure 6. Photomicrograph of well differentiated OSCC showing epithelial cell nests with central keratin pearls invading through the C.T. Note chronic inflammatory cell infiltrate (H&E x40).

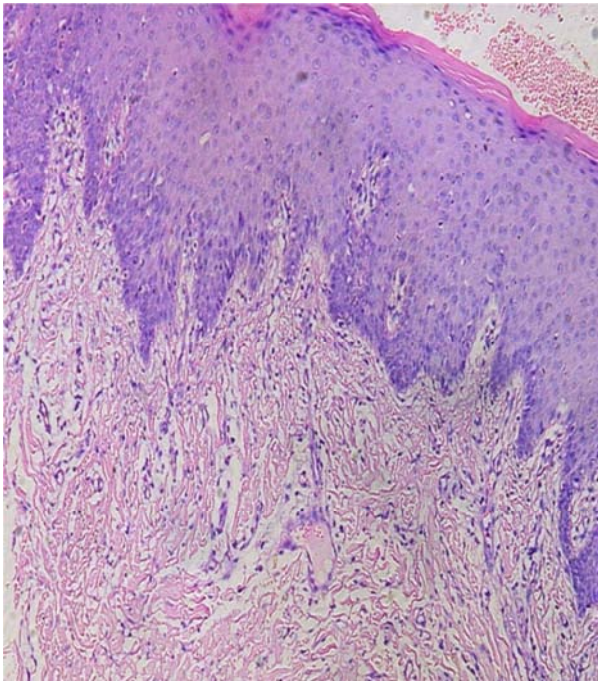


Figure 7. Photomicrograph of one safety margin showing hyperkeratotic hyperplastic stratified squamous epithelium with prominent granular cell layer (H&E x100).

5. Discussion

Papillon-Lefevre syndrome (PLS) is a rare genetic disorder characterized mainly by abnormal epithelial keratinization leading to palmoplantar hyperkeratosis and involvement of multiple ectodermal tissues. However, dyskeratosis is a common feature between many hereditary skin diseases [11].

For accurate diagnosis, careful clinical examination and precise assessment of all available data are mandatory.

In the present study, we reported a case complaining of classical clinical features of PLS but in a less aggressive pattern. Keratotic thickenings of the skin especially of that overlays the palms and soles were found in our patient similar to previously reported studies [1-9] and its seasonal worsening of the condition is consistent with a previous study done by Pavankumar (2010) [2].

In accordance with Sreeramulu (2015), numerous hyperpigmented spots were found in the plantar aspects of patient's feet [1]. In contrast, Chediak Higashi syndrome is characterized by reduced pigmentation (oculocutaneous albinism) [12].

He suffers also from frequent blister-like infectious eruptions. It may result from the expression of mutant gene in high levels in immune cells interfering with their normal function [1, 13]. However, patient's blood picture was normal which supports the exclusion of dyskeratotic congenital and Chediak Higashi syndrome [12, 14].

Furthermore, the presence of nail deformity also supports the diagnosis. Being limited to few fingernails helped us to exclude pachyonychia congenita and dyskeratosis congenita syndromes in which fingernails are extensively affected [10].

In addition, there was periodontal affection in the form of deep pockets, teeth mobility and drifting but the usual early loss of permanent teeth did not occur resembling a case reported by Ikeshima (2006) [8].

Histologically, the lesional tissue showed dysplastic surface epithelium and malignant epithelial cell nests with keratin pearls invading through the connective tissue. Such picture is clearly consistent with OSCC [15]. The normal oral mucosa excised as a safety margin with the cancerous lesion showed epithelial hyperplasia, hyperkeratosis and prominent granular cell layer is also consistent but not specific for PLS [1, 2].

By correlating the previous findings and consanguineous marriage of his parents, our patient is diagnosed with PLS-associated-OSCC.

Regarding the risk of developing malignancy, several studies reported the incidence of skin cancer such as melanoma and cutaneous squamous cell carcinoma in patients with PLS [4-7] and mucosal carcinoma such as ocular lesion reported by Murthy (2005) [9].

In this report, OSCC, the disease of old age [13], had developed early in our young patient who has a genetic susceptibility in addition to the presence of another predisposing factor which is a long time smoking.

6. Conclusion

Patients with Papillon-Lefevre syndrome have a genetic susceptibility to develop different malignancies. As the cutaneous and ocular cancers were previously reported, any mucosal dysplastic or cancerous lesions should be expected especially in the presence of another risk factor. Therefore, periodic examination is mandatory.

Competing Interests

The authors declare that they have no competing interests.

References

- [1] Sreeramulu B, Shyam N, Ajay P and Suman P. Papillon-Lefèvre syndrome: clinical presentation and management options. *Clin Cosmet Investig Dent*. 2015; 7: 75-81. doi: 10.2147/CCIDE.S76080.
- [2] Pavankumar K. Papillon-Lefevre syndrome: A case report. *The Saudi Dent J* 2010; 22: 95-8. doi: 10.1016/j.sdentj.2010.02.009. Epub 2010 Feb 6.
- [3] Ragupathy K, Priyadharsini I, Pasupathy S. Parental Consanguinity as a Risk Factor in Papillon-Lefevre Syndrome: A Case Report. *Int J Dent Med Res* 2015; 1: 68-71. www.ijohmr.com/.../Parental%20Consanguinity%20as%20a%20Risk.
- [4] Sammy Al-Benna,1 Raphael Hasler,1 Ingo Stricker,2 Hans-Ulrich Steinau,1 and Lars Steintraesser. Papillon-Lefèvre syndrome and squamous cell carcinoma: a case report. *Cases J*. 2009; 2: 7067. doi: 10.4076/1757-1626-2-7067.

- [5] Hacham-Zadeh S, Goldberg L. Malignant melanoma and Papillon-Lefèvre syndrome. *Arch Dermatol.* 1982; 118(1): 2. doi:10.1001/archderm.1982.01650130006003.
- [6] Nakajima K, Nakano H, Takiyoshi N, Rokunohe A, Ikenaga S, Aizu T, Kaneko T, Mitsuhashi Y, Sawamura D. Papillon Lefèvre syndrome and malignant melanoma. A high incidence of melanoma development in Japanese palmoplantar keratoderma patients. *Dermatology.* 2008; 217(1): 58-62. doi: 10.1159/000124340.
- [7] Cook GP. Papillon-Lefèvre syndrome and malignant melanoma. *Dermatology.* 2009; 219(2):187-8. doi: 10.1159/000224432.
- [8] T. Chaubal, R. Bapat and P. Wadkar. Papillon Lefevre syndrome. *QJM.* 2017; 110: 527, <https://doi.org/10.1093/qjmed/hcx090>.
- [9] Ikeshima A. Papillon-Lefevre syndrome: a highly-suspected case. *Journal of oral science* 2006; 48: 257-60. <https://www.slideshare.net/.../papillonlefevre-syndrome-a-case-report>.
- [10] Murthy R, Honavar SG, Vemuganti GK, Burman S, Naik M, Parathasaradhi A. Ocular surface squamous neoplasia in Papillon-Lefevre syndrome. *Am J Ophthalmol.* 2005 Jan; 139(1): 207-9. DOI:10.1016/j.ajo.2004.07.028.
- [11] Babu N A, Rajesh E, Krupaa J and Gnananandar G. Genodermatoses. *J Pharm Bioallied Sci.* 2015; 7: 203–6. DOI: 10.4103/0975-7406.155903.
- [12] Ghaffari J, Rezaee S, Gharagozlou M. Chédiak–Higashi syndrome. *J Pediatr Rev.* 2013; 1: 80-7. <http://jpr.mazums.ac.ir/article-1-49-en.html>
- [13] Bullón P, Castejón-Vega B, Román-Malo L, Jimenez-Guerrero MP, Cotán D, Forbes-Hernandez TY, Varela-López A, Pérez-Pulido AJ, Giampieri F, Quiles JL, Battino M, Sánchez-Alcázar JA, Cordero MD. Autophagic dysfunction in patients with Papillon-Lefèvre syndrome is restored by recombinant cathepsin C treatment. *J Allergy Clin Immunol.* 2018; S0091-6749(18)30144-1. doi: 10.1016/j.jaci.2018.01.018.
- [14] García MSF and Teruya-Feldstein J. The diagnosis and treatment of dyskeratosis congenita: a review. *J Blood Med.* 2014; 5: 157–67. DOI_1048_Kutbay.
- [15] Bouckaert M, Munzhelele TI , Feller L , Lemmer J and Khammissa RAG. The clinical characteristics of oral squamous cell carcinoma in patients attending the Medunsa Oral Health Centre, South Africa. *Integr Cancer Sci Therap,* 2016; 3: 575-8. DOI: 10.15761/ICST.1000207.