



Percutaneous Intramyocardial Septal Radiofrequency Ablation in Patients with Hypertrophic Cardiomyopathy – A Systematic Review and Meta-Analysis

Fatema Tashrifwala*, Manisha Purushotham, Sai Krishna Bhushan

Clinical Research Intern, Stamford Hospital, Connecticut, US

Email address:

ftashrifw@stamhealth.org (Fatema Tashrifwala)

*Corresponding author

To cite this article:

Fatema Tashrifwala, Manisha Purushotham, Sai Krishna Bhushan. Percutaneous Intramyocardial Septal Radiofrequency Ablation in Patients with Hypertrophic Cardiomyopathy – A Systematic Review and Meta-Analysis. *International Journal of Cardiovascular and Thoracic Surgery*. Vol. 9, No. 2, 2023, pp. 17-21. doi: 10.11648/j.ijcts.20230902.12

Received: February 8, 2023; Accepted: February 25, 2023; Published: May 29, 2023

Abstract: In this study, we aimed to meta-analyze all available data to provide a holistic, well-powered assessment of the effect of PIMSRA on LVOT gradient, LVEF, and anterior and posterior IVS thickness. PubMed, Cochrane Central, Embase, and Scopus were systematically searched from inception till October 2022 for published clinical trials assessing the efficacy of PIMSRA in patients with HCM using the keywords “PIMSRA” OR “Percutaneous Intramyocardial Septal Radiofrequency Ablation” OR “Liwen procedure. All five studies reported a change in LVOT gradient from the baseline. Integrated analysis showed no significant change from baseline (MD: -69.506; 95% CI: -77.047, -61.966; $P = 0.089$) ($I^2 = 50.4\%$). Subgroup analyses based on follow-up revealed that there was no significant difference noted at 6 months according to data from 2 studies (MD: -65.351; 95% CI: -85.253, -45.450; $P = 0.181$) ($I^2 = 44.1\%$) however data from 3 studies at one year follow up did reveal a significant difference from baseline (MD: -71.010; 95% CI: -80.262, -61.758; $P = 0.047$) ($I^2 = 67.2\%$). Only three studies reported changes in LVEF from the baseline. This single-arm meta-analysis of 284 patients gathered from 5 clinical trials suggested that overall, after PIMSRA, LVOT gradient was reduced, and LVEF was slightly decreased. Additionally, no significant changes were observed in the anterior and posterior IVS thicknesses.

Keywords: HCM, PIMSRA, LVOT, LVEF, Anterior IVS Thickness, Posterior IVS Thickness, Efficacy

1. Introduction

Hypertrophic cardiomyopathy (HCM) is an autosomal dominant intrinsic disease of the myocardium characterized by asymmetric hypertrophy and stiffness of the left ventricle along with the systolic anterior motion of the mitral valve, leading to a left ventricular outflow tract (LVOT) obstruction. It affects one in five hundred people worldwide and is the most common genetic heart disease in the US [1, 10]. The reduced volume of the heart chambers with a reduced capacity of the heart to pump blood results in a decreased stroke volume. LVOT obstruction is present at rest in about one-third of the patients. The symptoms include exertional dyspnea, exercise intolerance, orthopnea, peripheral edema, and syncope [2, 11]. Diagnostic modalities include echocardiography, electrocardiogram (ECG), and

cardiovascular magnetic resonance imaging (CMRI). Identification of the HCM phenotype can be made by family screening and genetic testing in affected individuals [3, 4, 12]. The treatment goals are to reduce the severity of symptoms and prevent sudden cardiac death, particularly in young adults. Pharmacological treatment revolves around β -blockers or non-dihydropyridine calcium-channel blockers with the newer generation of drugs, including Mavacamten, Perhexiline, and Trimetazidine. Evaluation and follow-up are done by LVOT gradient, left ventricular ejection fraction (LVEF), and myocyte hypertrophy measured by Interventricular septum (IVS) thickness [5]. In patients who are refractory to maximum dosage (about 40%) or have an intolerance to drugs, surgical options like septal myectomy and trans-catheter mitral valve repair may be considered. The downside to these is the need for a sternotomy. Minimally

invasive procedures which can instead be done are high-intensity focused ultrasonography and radiofrequency ablation, or Alcohol septal ablation (ASA), which come with their own risk of complications with chances of occurrence ranging from 0.5-5% [6]. The suitability of ASA is limited by septal coronary anatomy and the risk of alcohol being injected into the wrong site. Advancements in techniques have now led to the use of percutaneous intramyocardial septal radiofrequency ablation (PIMSRA) as a promising technique for such patients. This technique uses a radiofrequency electrode needle inserted under guidance into the hypertrophied IVS to achieve ablation [4, 7]. Trials have shown reductions in IVS thickness and LVOT gradients along with improvement in New York Heart Association (NYHA) functional classification following PIMSRA, but these studies have been limited by small sample sizes, thus being underpowered to reliably demonstrate any significant differences in outcomes. In this study, we aimed to meta-analyze all available data to provide a holistic, well-powered assessment of the effect of PIMSRA on LVOT gradient, LVEF, and anterior and posterior IVS thickness.

2. Methods

PubMed, Cochrane Central, Embase, and Scopus were systematically searched from inception till October 2022 for published clinical trials assessing the efficacy of PIMSRA in patients with HCM using the keywords “PIMSRA” OR “Percutaneous Intramyocardial Septal Radiofrequency Ablation” OR “Liwen procedure.” Studies that reported change in either LVOT gradient, IVS thickness, or LVEF were selected. No time or language restrictions were applied. All case reports were excluded, and only clinical trials were included. The search and data extraction were carried out independently by two reviewers (MP, FT). A third reviewer (IH) was consulted to resolve discrepancies. All statistical analyses were conducted on Open Meta-analyst. Trials were pooled using a continuous random effects model (DL: DerSimonian-Laird), and results were presented with 95% confidence intervals (CIs). P value <0.05 was considered significant. Subgroup analysis according to time at follow-up was done. Heterogeneity was evaluated using Higgins I^2 , with $I^2 > 75\%$ regarded as substantial heterogeneity.

3. Contents and Results

The initial search yielded 72 potential studies. After exclusions, 5 trials remained for analysis [1, 3, 4, 7, 8, 9]. The detailed literature search is highlighted in the PRISMA Flow Chart (Supplementary Material Figure 1). The characteristics of the included studies have been summarized in Table 1.

All five studies reported a change in LVOT gradient from the baseline (Figure 1A). Integrated analysis showed no significant change from baseline (MD: -69.506; 95% CI: -77.047, -61.966; $P = 0.089$) ($I^2 = 50.4\%$). Subgroup analyses based on follow-up revealed that there was no significant

difference noted at 6 months according to data from 2 studies (MD: -65.351; 95% CI: -85.253, -45.450; $P = 0.181$) ($I^2 = 44.1\%$) however data from 3 studies at one year follow up did reveal a significant difference from baseline (MD: -71.010; 95% CI: -80.262, -61.758; $P = 0.047$) ($I^2 = 67.2\%$).

Only three studies reported changes in LVEF from the baseline (Figure 1B). Integrated analysis Powered by Editorial Manager® and Prodxion Manager® from Aries Systems Corporation showed a significant change from baseline at one-year follow-up in patients who underwent PIMSRA (MD: -1.760; 95% CI: -3.239, -0.282; $P = 0.047$) ($I^2 = 67.22\%$).

The pooled analysis from four studies that reported anterior IVS thickness showed no significant change from baseline (MD: -9.707; 95% CI: -10.819, -8.595; $P = 0.095$) ($I^2 = 52.94\%$). Subgroup analyses based on follow-up revealed that there was no significant difference noted at 6 months (MD: -11.285; 95% CI: -12.825, -9.744; $P = 0.933$) ($I^2 = 0\%$) or at one-year follow-up (MD: -9.147; 95% CI: -9.837, -8.456; $P = 0.650$) ($I^2 = 0\%$) (Figure 1C).

The combined analysis of the four included studies reporting posterior IVS thickness showed no significant change from baseline (MD: -8.859; 95% CI: -10.073, -7.644; $P = 0.119$) ($I^2 = 48.73\%$). Additionally, there was no significant difference noted in the subgroup analysis at 6 months (MD: -10.278; 95% CI: -12.133, -8.423; $P = 0.934$) ($I^2 = 0\%$) and at one-year follow-up (MD: -8.335; 95% CI: -9.880, -6.789; $P = 0.072$) ($I^2 = 69.14\%$) (Figure 1D).

4. Discussion

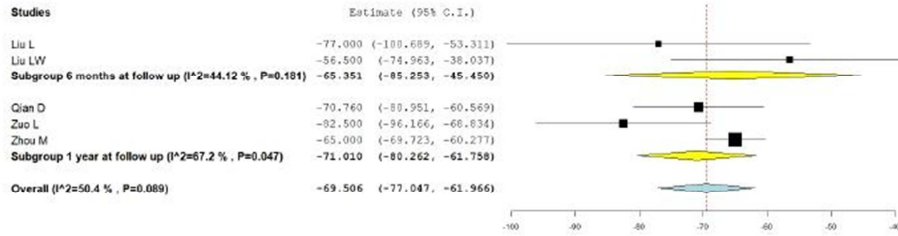
Our meta-analysis had some limitations. The number of studies and the sample size available for analysis were limited, and most patients were of Chinese origin. Furthermore, no studies have evaluated the long-term effects on cardiac conduction due to the scar tissue formed following ablation. Therefore, further studies with long-term follow-up having large sample sizes from different patient populations and ethnicities should be done to demonstrate the effectiveness of PIMSRA with more statistical power. Outcomes measuring procedure safety, such as intraoperative and postoperative complications, should also be recorded and compared with a control group.

5. Conclusion

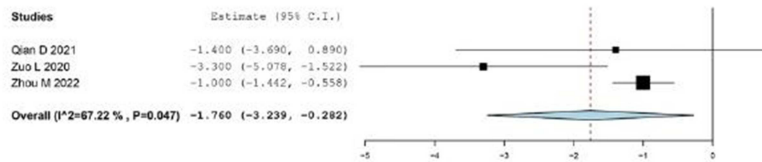
This single-arm meta-analysis of 284 patients gathered from 5 clinical trials suggested that overall, after PIMSRA, LVOT gradient was reduced, and LVEF was slightly decreased. Additionally, no significant changes were observed in the anterior and posterior IVS thicknesses. Our results had substantial heterogeneity, which could be explained due to differences in the follow-up periods and studies with small sample sizes. It is important to note that even though no significant difference in follow-up was seen from the baseline at 6 months, there was indeed a significant difference noted at one year when assessing the outcomes of the LVOT gradient.

This could suggest that longer follow-up periods are imperative to truly observe the procedure's efficacy.

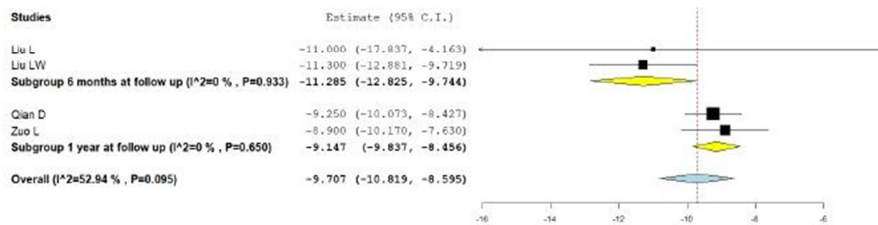
a) Change in LVOT Gradient



b) Change in LVEF



c) Change in Anterior IVS Thickness



d) Change in Posterior IVS Thickness

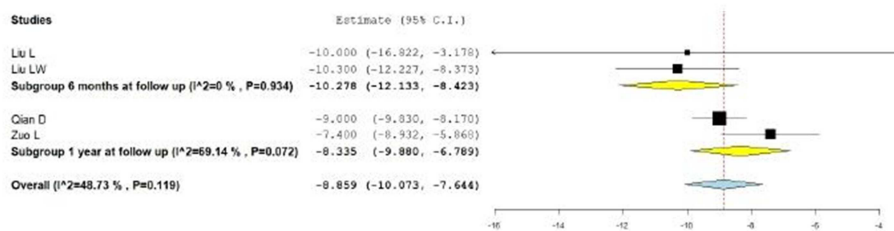


Figure 1. Forrest plots show the results of the analysis.

Table 1. Characteristics of included studies.

Included Studies	Year	Characteristics of Patients				Number of participants	Follow up	
		Age in years	Gender	NYHA Class	LVOT Gradient			IVS Thickness
Zhou M [1]	2022	33 - 61	M - 125 F - 75		>50 mmHg		200	1 year
Qian D [3]	2021				>50 mmHg	15-25 mm	30	1 year
Zuo L [7]	2020	15 - 79	M - 20 F - 10	Chest pain, syncope, NYHA Class III/IV	> 50 mmHg		30	1 year
Liu L [6]	2018	24 - 57	M - 13 F - 2	Chest pain, syncope, NYHA Class III/IV			15	6 months
Liu LW [8]	2019			Two NYHA class II & Seven NYHA class III cases			9	6 months

NYHA: New York Heart Association; LVOT: Left Ventricular Outflow Tract; IVS: Interventricular Septum

Abbreviations

HCM: Hypertrophic Cardiomyopathy
 LVOT: Left ventricular Outflow Tract
 US: United States
 CMRI: Cardiovascular Magnetic Resonance Imaging
 LVEF: Left Ventricular Ejection Fraction
 ASA: Alcohol Septal Ablation
 PIMSRA: Percutaneous Intramyocardial Septal Radiofrequency Ablation
 IVS: Interventricular Septum
 NYHA: New York Heart Association
 CI: Confidence Interval
 MD: Mean Deviation

Author Declarations

Funding

The authors declare that no funds, grants, or other support were received during the preparation of this manuscript.

Conflict of Interest

The authors have no relevant financial or non-financial interests to disclose.

Author Contribution

All authors had access to the data and a role in writing the manuscript. All authors have reviewed the manuscript and approved it in its current form.

Code Availability

Following PRISMA guidelines. Software used was Open Meta analyst.

Availability of Data and Material

Transparent.

Ethics Approval

This is a review article (metanalysis). According to PRISMA no ethical approval is required.

Consent to Participate

N/A

Consent to Publish

N/A

Declaration of Conflicting Interests

The author(s) declared no potential conflicts of interest with respect to the research, authorship and/or publication of this article.

References

- [1] Zhou M, Ta S, Hahn RT, Hsi DH, Leon MB, Hu R, Zhang J, Zuo L, Li J, Wang J, Wang B, Zhu X, Liu J, Han Y, Li X, Xu B, Zhang L, Hou L, Han C, Liu J, Liu L. Percutaneous Intramyocardial Septal Radiofrequency Ablation in Patients with Drug-Refractory Hypertrophic Obstructive Cardiomyopathy. *JAMA Cardiol.* 2022 May 1; 7 (5): 529-538. doi: 10.1001/jamacardio.2022.0259. PMID: 35353129; PMCID: PMC9096597.
- [2] Marian AJ, Braunwald E. Hypertrophic Cardiomyopathy: Genetics, Pathogenesis, Clinical Manifestations, Diagnosis, and Therapy. *Circ Res.* 2017 Sep 15; 121 (7): 749-770. doi: 10.1161/CIRCRESAHA.117.311059. PMID: 28912181; PMCID: PMC5654557.
- [3] Qian D, Zhou X, Liu H, Cao L. Clinical value of 2D speckle tracking imaging in evaluating the effect of percutaneous intramyocardial septal radiofrequency ablation in patients with hypertrophic obstructive cardiomyopathy. *J Clin Ultrasound.* 2021 Jul; 49 (6): 554-562. doi: 10.1002/jcu.22989. Epub 2021 Mar 6. PMID: 33675543.
- [4] Zhonghua Xin Xue Guan Bing Za Zhi. 2019 Apr 24; 47 (4): 284-290. Chinese. doi: 10.3760/cma.j.issn.0253-3758.2019.04.005. PMID: 31060187. Tuohy CV, Kaul S, Song HK, Nazer B, Heitner SB. Hypertrophic cardiomyopathy: the future of treatment. *Eur J Heart Fail.* 2020 Feb; 22 (2): 228-240. doi: 10.1002/ehf.1715. Epub 2020 Jan 9. PMID: 31919938.
- [5] Burstein Waldman C, Owens A. A plain language summary of the EXPLORER-HCM study: mavacamten for obstructive hypertrophic cardiomyopathy. *Future Cardiol.* 2021 Oct; 17 (7): 1269-1275. doi: 10.2217/fca-2021-0044. Epub 2021 May 21. PMID: 34018809.

- [6] Liu L, Li J, Zuo L, Zhang J, Zhou M, Xu B, Hahn RT, Leon MB, Hsi DH, Ge J, Zhou X, Zhang J, Ge S, Xiong L. Percutaneous Intramyocardial Septal Radiofrequency Ablation for Hypertrophic Obstructive Cardiomyopathy. *J Am Coll Cardiol*. 2018 Oct 16; 72 (16): 1898-1909. doi: 10.1016/j.jacc.2018.07.080. PMID: 30309466.
- [7] Zuo L, Hsi DH, Zhang L, Zhang Q, Shao H, Liu B, Lei C, Ye C, Meng X, Zhang G, Zhou M, Li J, He Y, Guo J, Liu L. Electrocardiographic QRS voltage amplitude improvement by intramyocardial radiofrequency ablation in patients with hypertrophic obstructive cardiomyopathy and one year follow up. *J Electrocardiol*. 2020 Jul-Aug; 61: 164-169. doi: 10.1016/j.jelectrocard.2020.06.013. Epub 2020 Jun 10. PMID: 32721657.
- [8] Liu LW, Zuo L, Zhou MY, Li J, Zhou XD, He GB, Zhang J, Zhang JZ, Liu B, Yang J, Xu B. [Efficacy and safety of transthoracic echocardiography-guided percutaneous intramyocardial septal radiofrequency ablation for the treatment of patients with obstructive hypertrophic cardiomyopathy]. *Zhonghua Xin Xue Guan Bing Za Zhi*. 2019 Apr 24; 47 (4): 284-290. Chinese. doi: 10.3760/cma.j.issn.0253-3758.2019.04.005. PMID: 31060187.
- [9] Mosterd A, Hoes AW. Clinical epidemiology of heart failure. *Heart*. 2007 Sep; 93 (9): 1137-46. doi: 10.1136/hrt.2003.025270. PMID: 17699180; PMCID: PMC1955040.
- [10] Tanai E, Frantz S. Pathophysiology of Heart Failure. *Compr Physiol*. 2015 Dec 15; 6 (1): 187-214. doi: 10.1002/cphy.c140055. PMID: 26756631.
- [11] Snipelisky D, Chaudhry SP, Stewart GC. The Many Faces of Heart Failure. *Card Electrophysiol Clin*. 2019 Mar; 11 (1): 11-20. doi: 10.1016/j.ccep.2018.11.001. Epub 2018 Dec 24. PMID: 30717842.
- [12] Yancy CW, Jessup M, Bozkurt B, Butler J, Casey DE Jr, Drazner MH, Fonarow GC, Geraci SA, Horwich T, Januzzi JL, Johnson MR, Kasper EK, Levy WC, Masoudi FA, McBride PE, McMurray JJ, Mitchell JE, Peterson PN, Riegel B, Sam F, Stevenson LW, Tang WH, Tsai EJ, Wilkoff BL; American College of Cardiology Foundation; American Heart Association Task Force on Practice Guidelines. 2013 ACCF/AHA guideline for the management of heart failure: a report of the American College of Cardiology Foundation/American Heart Association Task Force on Practice Guidelines. *J Am Coll Cardiol*. 2013 Oct 15; 62 (16): e147-239. doi: 10.1016/j.jacc.2013.05.019. Epub 2013 Jun 5. PMID: 23747642.