



Case Report

Therapeutic Attitude in the Malignification of Pilonidal Cyst: Radical Treatment Associating Intraoperative Radiotherapy

Natalia Noblejas Quiles¹, Virginia Morillo Macías¹, Araceli Mayol Oltra², Fernando Ibáñez Palacín³, Jorge Molina Saera⁴, Rafael Lozoya Albalar², Enrique Boldó Roda², Stephane Antonio De Francia Cachon⁵, María Eloísa Villaverde Domenech⁵, Isabel Busquier Hernández⁴, Carlos Ferrer Albiach¹

¹Department of Radiation Oncology, Consorcio Hospitalario Provincial de Castellon, Castellon, Spain

²Department of General Surgery, Consorcio Hospitalario Provincial de Castellon, Castellon, Spain

³Department of General Surgery, Hospital de Vinaroz, Castellon, Spain

⁴Department of Medical Oncology, Consorcio Hospitalario Provincial de Castellon, Castellon, Spain

⁵Department of Plastic Surgery, Consorcio Hospitalario Provincial de Castellon, Castellon, Spain

Email address:

nathalia_1357@hotmail.com (N. N. Quiles), vmorill@gmail.com (V. M. Macías), aracelimayol@gmail.com (A. M. Oltra), cirujito@gmail.com (F. I. Palacín), jorgemolinasuera@gmail.com (J. M. Saera), lozoyarafeel@gmail.com (R. L. Albalar), eboldo@aecirujanos.com (E. B. Roda), drdefrancia@gmail.com (S. A. De F. Cachon), eloisavillaverde@outlook.es (M. E. V. Domenech), isabel.busquier@telefonica.net (I. B. Hernández), ferreralbiach@gmail.com (C. F. Albiach)

*Corresponding author

To cite this article:

Natalia Noblejas Quiles, Virginia Morillo Macías, Araceli Mayol Oltra, Fernando Ibáñez Palacín, Jorge Molina Saera, Rafael Lozoya Albalar, Enrique Boldó Roda, Stephane Antonio De Francia Cachon, María Eloísa Villaverde Domenech, Isabel Busquier Hernández, Carlos Ferrer Albiach. Therapeutic Attitude in the Malignification of Pilonidal Cyst: Radical Treatment Associating Intraoperative Radiotherapy. *International Journal of Clinical Oncology and Cancer Research*. Vol. 5, No. 1, 2020, pp. 5-9. doi: 10.11648/j.ijccocr.20200501.12

Received: December 7, 2019; **Accepted:** December 26, 2019; **Published:** January 8, 2020

Abstract: Malignant degeneration on pilonidal cyst is an infrequent entity: less than 70 cases have been described in the literature. Predominantly in males around 50-60. Very slow evolution until its malignancy. Predilection for the sacrococcygeal area and epidermoid histology. Infrequent distant dissemination despite the important local extension of the primary tumor. Similar morphological and histological characteristics to anal carcinomas, using schemes of treatment based on radiotherapy and chemotherapy with radical intention according to locoregional and distance extension, associating subsequent surgery depending on the response. We describe a case of this pathology and its therapeutic management based on the literature review available. We present the case of a 70-year-old man with a pilonidal cyst malignancy in the sacrococcygeal region. Locally advanced and unresectable disease at diagnosis with skin, muscle, lymphatic and bone involvement. Pathological confirmation diagnosis established after thick needle biopsy, with a well-differentiated squamous cell carcinoma. It was decided to administer chemotherapy and radiotherapy treatment and, depending on the response evaluated by nuclear magnetic resonance, excision and/or intraoperative radiotherapy in the area of microscopic risk disease. In a second time, reconstruction using glute flaps. Early diagnosis and treatment are essential to improve the unfortunate prognosis. Surgery with curative intention is the standard of care according to locoregional extension in association with radiotherapy and chemotherapy if adverse factors or unresectable disease. In order to enhance local control, dose has been scaled allowing, besides, to minimize the acute toxicity derived from the treatment.

Keywords: Malignancy of Pilonidal Cyst, Radiotherapy, Intraoperative Radiotherapy, Neoadjuvant Treatment, Sacrococcygeal Area, Surgery

1. Introduction

The pilonidal cyst is a frequent entity that predominantly affects males between 15 and 40 years old [1] and it is usually complicated by local infectious processes [2]. It typically manifests clinically from adolescence with completely asymptomatic behavior or, on the contrary, fistulize and form abscesses. Two phases have been identified in its clinical evolution: the first is chronification, in which pain and discomfort generally appear, followed by an acute process in which an abscess forms [3].

It is habitually located in the sacrococcygeal area, as well as in other less common locations such as the armpit, the foot sole, the penis, the clitoris, the anal channel or the umbilical scar [2]. Its nature is controversial because it may be congenital or acquired [2, 4]; the first one was initially rejected when its association with repeated traumas in the area was demonstrated. Infrequent communication with the spinal canal or producing neurological symptoms [3]. In asymptomatic cases, conservative treatment is usually carried out; in symptomatics, surgical resection [2, 4].

Table 1. [7]. Distinctive characteristics between malignant degeneration on pilonidal cyst according to histology.

	Most frequent sex	Presentation age (years)	Prevalence	Time of evolution to malignancy (average, in years)	Local recurrence	Metastatic capacity	Surgical resection
Epidermoid carcinoma	Male (3:1)	50-60	75%	20,67	50% approximately	At the inguinal / osseous level	Must be more aggressive (extended exeresis)
Basal cell carcinoma	Female	60	25%	1	< 1%	Scarce, it tends to grow superficially	Less mutilating (simple exeresis)

Malignant degeneration is an uncommon complication that is mainly observed in recurrent chronic disease [5]; the average time is around 20 years [6]. Its incidence is 0.1% [1, 2, 4, 5, 7, 13, 14]. The average age of presentation is between the fifth and seventh decade of life, showing a higher prevalence in the male sex (3:1) [3] mainly if it is an epidermoid histology (in the 90% of cases) [3, 6] (Table 1) [7]. In the limited cases reported in the female gender, the most frequent histology is basal cell type [3]. It presents a high recurrence rate and, therefore, a fateful prognosis after surgical resection, regardless of the technique used for this purpose (around 5-20% in the first year) [2, 6].

Recently, it has performed the treatment of a patient with this unfrequently tumor. Given the atypical and aggressive behavior of this tumor with bone involvement, a literature review has been made and then we present it and our therapeutic attitude.

2. Clinical Case

We describe the case of a 70-year-old man without medical interest history, sent from the General Surgery Service at the Vinaroz Hospital (Castellón de la Plana) last October, 2018. He had a sacrococcygeal tumor that affected soft tissues in the intergluteal fold evolving since 4 months ago. The initial pilonidal cyst development began more than 25 years ago, with a history of recurrent drainage and broad antibiotic coverage, despite which he presented repeated cysts episodes.

Initial clinical examination showed an excretory and malodorous lesion in the intergluteal fold adhered to deep planes, approximately 14 x 9 cm in maximum diameter and increase in size in recent months, with seborrheic, fetid and necrotic borders. On physical examination, a mobile nodule about 2.3 cm in diameter was palpated at the right inguinal level. No other adjacent skin lesions were seen.

Discomfort with sitting without rectal bleeding. The MRI revealed a lesion with maximum diameter of 10 cm, heterogeneity in intravenous contrast uptake and contacted the

gluteal muscle planes, as well as the underlying bony structures of the sacrococcygeal skeleton.

An extension study was requested by thoracic-abdominal-pelvic computed tomography, showing the lesion in the subcutaneous fat tissue of the intergluteal region, right inguinal adenopathy of 14 × 20 mm and left of 12 × 17 mm with fatty hilum lost. Absence of distant tumor disease (Figure 1).

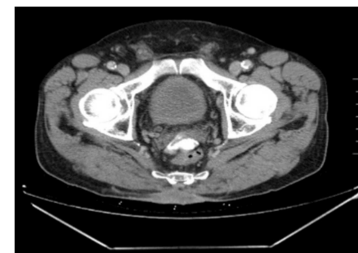


Figure 1. Contrast thoraco-abdominal-pelvic CT where it is appreciated the lesion previously described.

Given the recurrence history, it was decided to carry out a thick needle biopsy of the tumor and a fine needle puncture on right inguinal adenopathy. Macroscopically, a verrucous lesion and a cutaneous puncture were analyzed, both with anatomopathological result of well-differentiated squamous carcinoma (Figure 2). However, no evidence of malignancy was found in the inguinal lymph node sample submitted.

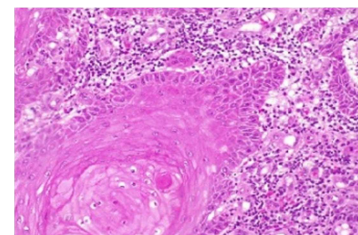


Figure 2. Microscopically tumor vision.

Tumor markers as well as quantitative analysis of human

papillomavirus (HPV) were determined, both being negative. Due to the large lesion size and its aggressive behavior it was considered a locally advanced and unresectable disease, rejecting surgery.

The patient was assessed by the Medical Oncology Service and fluoropyrimidines treatment was administered (orally Capecitabine, dose of 825 mg / m² / 12 h the same days as radiotherapy) [8, 9] concomitant with EBRT. With a safety margin, it was irradiated the macroscopic tumor using a bolus of 0.5 cm to ensure deposited superficially dose. Modulated Volumetric Arco-therapy (VMAT) was the used technique [10], with photons of 6 MV and daily verification by Kv-CBCT (kilovoltage-Cone Beam Computerized Tomography), using different fractionation: 150 cGy per session until reaching 45 Gy on pelvis; 168 cGy per session up to 50.4 Gy on affected adenopathies smaller than 3 cm and 198 cGy per session until reaching a total dose of 59.4 Gy on the tumor and adenopathies larger than 3 cm, the second and third phase with simultaneous overprinting (SIB), all in 30 treatment fractions, 5 days a week, following the RTOG 0529 study (Radiation Therapy Oncology Group) [11] (Figure 3). Adequate tolerance to treatment, presenting grade 2 cutaneous toxicity on the treated area according to the RTOG scale [12] (Figure 4).

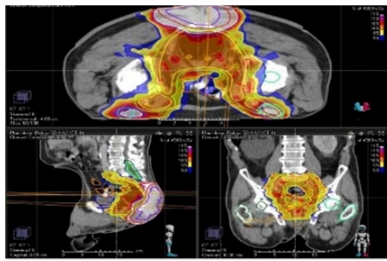


Figure 3. Planning TC for the radiotherapy treatment where the lesion and inguinal adenopathies contour is shown, as well as the risk organs surrounding it. Dosimetry performed once the treatment planning has been carried out.

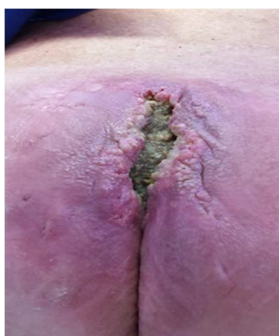

Figure 4. Image of the lesion when the EBRT treatment finished.

One month after finishing the treatment, MRI was performed for clinical response assessment; a significant size decrease was observed, with a deep ulcer and diffusion edges restriction, reaching the coccyx underlying and bilateral nonspecific inguinal lymph nodes, compatible with a partial response.

It was decided to carry out a surgical treatment with radical

intention, associating intraoperative radiotherapy (IORT) in the same procedure. En bloc resection procedure was performed with partial exeresis of the gluteus maximus, conserving the superior gluteal vessels. Absence of infiltration of the sacral bone so it was resected the presacral tissues and the coccyx until reaching the pelvic fascia. In the exposed area it was administered a dose of 10 Gy (90% isodose, 9 MeV energy) with a 12 cm diameter applicator.

The microscopic anatomopathological results did not identify residual tumor lesion in the studied samples. Adequate postoperative clinical evolution with defect reconstruction after 15 days. It consisted on latissimus dorsi free flap, advance of the gluteal flaps and skin graft.

The periodic follow-up has been initiated in the consultation by physical examination, MRI and analytical without locoregional or distance progression evidence. Patient is currently asymptomatic and he has a satisfactory quality of life.

3. Discussion

Malignant degeneration on pilonidal cyst is a rare transformation that is mainly observed in recurrent chronic untreated process [2] and inadequate hygiene of the area [5]; it usually takes about 20 years until its malignancy [6]. It is speculated that it happens by liberation of oxygen free radicals by activated cells (LAK, Lymphokine-activated Killer Cells) that induce genetic alterations in favor of the neoplastic transformation due, in turn, to DNA repair mechanism failure [2].

Local affectation predominates, being unusual distance involvement at the diagnosis; if present, the prognosis worsens [6]. Close monitoring of chronic ulcers with necrotic or friable margins is recommended, as well as biopsy in case of suspicion. Fine needle puncture of suspicious lymph nodes does not usually detect the presence of tumor disease [2], so thick needle biopsy is recommended [2, 13]. The majority of malignant lesions present deep involvement of the subcutaneous cellular tissue, reaching the bone plane in 8-15% of cases [2, 3, 6]. Therefore, it is important to determine the depth invasion, as well as to assess the metastatic involvement during the initial exploration examining both the lesion and the inguinal region [6]. It is convenient to perform rectoscopy / colonoscopy in order to rule out its affectation by contiguity [2]. MRI is the most appropriate technique for locoregional assessment and computerized axial tomography is also routinely performed [2, 6].

The first case was described in 1900 by Wolff [2, 5, 13] and, so far, about 70 cases have been described in the literature [1, 2, 5, 6, 13, 14]. Central ulceration is usually present, with indurated, friable and erythematous margins. The tumor grows locally before inguinal lymph node involvement. Recent data suggest that HPV and / or p16 positivity are prognostic markers in this entity, improving overall survival [8].

Therapeutic options offered are based on aggressive excision procedures. Subsequently, the wound may be closed

directly in the surgical act or allowed to do by second intention [2, 6]. The surgical choice treatment is based on the resection in bloc of the lesion with safety margins [6]. Due to the bulky lesions, with a greater diameter than 5 cm, exposing a wide surgical field, the area reconstruction is usually performed by vascularized flaps or skin grafts; in some cases, a temporary colostomy is necessary.

There is not enough available data to affirm which is the best therapeutic sequence. Radiotherapy can be performed before or after surgical treatment, although it is preferred before since it decreases the incidence and severity of the associated toxicity, as well as preserving the viability of grafts and plasty [2, 4, 15]. With this treatment sequence is possible to increase local control and, besides, the disease-free interval [4].

Prophylactic regional lymphadenectomy (LDN) may be indicated in case of initial lymph node involvement, but usually is not performed [2, 4].

Despite the curative attempt, the survival rate is around 55%. Percentage of local recurrence is around 50% in the first 5 years [1, 3, 6], with no relationship with tumor grade; the disease free survival not exceed 9-16 months [1].

The addition of local RTE decreases the local recurrence rate by 30-40% [1, 2, 4]. Lymph node and distant recurrence occur in approximately 14% of cases respectively (mainly at the bone level), with a 20-30% mortality rate [3]. If lymph node involvement, prognosis worsens drastically with an average survival of 6 months [2, 7].

Chemotherapy association can be effective in high risk lesions, but it is controversial such as adjuvant treatment [1, 2, 4]. It is important to rule out adverse factors such as lymphovascular / perineural invasion [6] and tumor margins, being difficult to assure its negativity for carcinoma because, sometimes, pseudocarcinomatous hyperplasia may appear [4].

Due to the few reported cases of this pathology, it is difficult to elaborate clinical guidelines based on evidence. In recurrence cases, a new exeresis and evaluation of adjuvant treatment is contemplated, provided that it has not received prior irradiation [7]. At present, our patient remains free of disease.

4. Conclusion

The incidence of malignant degeneration on pilonidal cyst is very low. We consider this case relevant because of its slow and torpid evolution towards malignancy and its ominous prognosis.

The diagnosis is established based on the clinical examination and the biopsy in case of friable and perilesional necrotic tissue. Tumor lesions are usually big, invasive in depth and usually infiltrate subcutaneous cellular tissue, muscle planes and bone tissue.

Magnetic resonance imaging and computerized axial tomography are indicated to assess locoregional extension, as well as rule out distant involvement.

If there is an unresectable disease at diagnosis, radiotherapy and chemotherapy treatment followed by radical surgery and

IORT are the key to improve the unfavorable prognosis, by emphasizing the importance of using intraoperative radiotherapy in these cases such as a new therapeutic approach for these patients. Evolutive control is acceptable in our patient, but a longer follow-up is required to infer adequate conclusions since it is difficult due to the scarce data available in the literature.

Abbreviations

DNA: Deoxyribonucleic acid. EBRT: External beam radiotherapy. HPV: Papillomavirus. IORT: Intraoperative Radiotherapy. Kv-CBCT: kilovoltage-ConeBeam Computerized Tomography. LDN: Lymphadenectomy. MRI: Magnetic Resonance Imaging. RTOG: Radiation Therapy Oncology Group. TC: Computer tomography. VMAT: Modulated Volumetric Arcotherapy.

Acknowledgements

First of all, I would like to express my thanks to Virginia Morillo for her dedication and support it has given to me, for respecting my suggestions and ideas, for trusting on me and the address that you have given to the article. Likewise, I would like to thank Fernando Ibáñez and again Virginia Morillo for their contribution, providing me the images of the clinical case. This case has been exhibited in poster format at the XX SEOR Congress and subsidized by the Consorcio Hospitalario Provincial in Castellon.

References

- [1] Michalopoulos N, Sapalidis K, Laskou S, Triantafyllou E, Raptou G, Kesisoglou I. "Squamous cell carcinoma arising from chronic sacroccocygeal pilonidal disease: a case report". *World J Surg Oncol*. 2017; 15 (1): 65.
- [2] Cruz-Mendoza I, Hernández-Jesús B, López-Pérez E, Flores-Cobos AE, García-Rodríguez F. "Tumor epidermoide moderadamente diferenciado asociado con quiste pilonidal". *Cirugía Cir*. 2014; 82 (1): 87-92.
- [3] Alarcón-del Agua I, Bernardos-García C, Bustos-Jiménez M, Serrano-Borrero I, Casado-Maestre MD, Docobo-Durantez F. "Denegeración maligna sobre quiste pilonidal". *Cirugía Cir*. 2011; 79 (4): 373-378.
- [4] Jaime SP, Julve JV, Alzamora MS, Santaló NB, Millán CV, Barón RE. "Malignización de los sinus pilonidales: tratamiento". *Oncol. Rev*. 2002; 4 (6): 331-334.
- [5] Nunes LF, Pitta de Castro AK, Vasconcelos RAT, Cajaraville F, Castilho J, Netto JF, Silva W. "Carcinomatous degeneration of pilonidal cyst with sacrum destruction and invasion of the rectum". *An Bras Dermatol*. 2013; 88 (6): 59-62.
- [6] Ramazan E, Tuna B, Ismail O, Orhan Veli O, Aytekin C, Mustafa S. "Recurrent squamous cell carcinoma arising in a neglected pilonidal sinus: report of a case and literature review". *Int J Clin Exp Med*. 2014; 7 (2): 446-450.

- [7] De Bree E, Zoetmulder FA, Christodoulakis M, Aleman BM, Tsiftsis DD. "Treatment of malignancy arising in pilonidal disease". *An. Surgery Oncol.* 2001; 8 (19): 60-64.
- [8] NCCN Clinical Practice Guidelines in Oncology, Anal carcinoma [Internet]. Nccn.org. 2018 [cited 6 May 2019]. Available from: https://www.nccn.org/professionals/physician_gls/default.aspx.
- [9] Meulendijks D, Dewit L, Tomaso NB, Van Tinteren H, Beijnen JH, Schellens JH, Cats A. "Chemoradiotherapy with capecitabine for locally advanced anal carcinoma: an alternative treatment option". *Br J Cancer.* 2014; 111 (9): 1726–1733. doi: 10.1038/bjc.2014.467.
- [10] RTOG Radiation Foundation INC, Anorectal Counturing Guidelines [Internet]. Rtog.org. 2019 [cited 11 May 2019]. Available from: <https://www.rtog.org/CoreLab/ContouringAtlases/Anorectal.aspx>.
- [11] Kachnic L, Winter K, Myerson R, Goodyear MD, Willins J, Esthappan J, Haddock MG, Rotman M, Parikh PJ, Safran H, Willett CG. "RTOG 0529: A Phase 2 Evaluation of Dose-Painted Intensity Modulated Radiation Therapy in Combination With 5-Fluorouracil and Mitomycin-C for the Reduction of Acute Morbidity in Carcinoma of the Anal Canal". *Int J Radiat Oncol Biol Phys.* 2013; 86 (1): 27-33.
- [12] Cooperative Group Common Toxicity Criteria [Internet]. Rtog.org. 2019 [cited 6 May 2019]. Available from: <https://www.rtog.org/ResearchAssociates/AdverseEventReporting/CooperativeGroupCommonToxicityCriteria.aspx>.
- [13] Park BS, Shin DH, Kim SH, Jung HJ, Son GM. "Perineal squamous cell carcinoma arising from an epidermal cyst: a case report". *World J Surg Oncol.* 2018; 16 (1): 155.
- [14] Boukalik W, Salwan F. "Squamous Cell Carcinoma Arising in a Pilonidal Sinus". *An Surgery.* 1962; 156 (1): 157-160.
- [15] Cardona-Hernández MA, Fierro-Arias L, González-González M, Ávila Medrano L. "Carcinoma epidermoide de alto riesgo originado en úlcera de Marjolin. Tratamiento alternativo con radioterapia". *Dermatol. Rev. Mex.* 2014; 58: 267-273.