



Dermoscopy Is the Crucial Step for Proper Outcome Prospection When Treating Androgenetic Alopecia with the Regenera[®] Protocol: A Score Proposal

Hernán Pinto¹, Rafael Gálvez², José Casanova²

¹Department of Medical, Biomedical Research Institute, Barcelona, Spain

²Giroclinic, Girona, Spain

Email address:

hpinto@i2e3.com (H. Pinto)

To cite this article:

Hernán Pinto, Rafael Gálvez, José Casanova. Dermoscopy Is the Crucial Step for Proper Outcome Prospection When Treating Androgenetic Alopecia with the Regenera[®] Protocol: A Score Proposal. *International Journal of Clinical and Developmental Anatomy*.

Vol. 4, No. 1, 2018, pp. 15-18. doi: 10.11648/j.ijcda.20180401.12

Received: November 13, 2017; **Accepted:** November 29, 2017; **Published:** February 26, 2018

Abstract: There is no actual treatment capable of creating hair follicles *de novo*, since a hair follicle is not a single tissue but a tiny, full anatomical structure. The Regenera[®] method is based on the regeneration and recovery of severely non-functional but still-alive hair follicles. For 1.5 years, clinical assessment has been the sole pillar of any outcome prospection issued. Wrong prospectations could be affecting about 10% of patients expecting good results. Scalp dermoscopy was then included in routine diagnosis tests of every patient willing to be treated with the Regenera[®] protocol. When analyzing the data of the dermoscopy of patients with a poor prospection, it was clear that the expectancies related to the treatment's results were overestimated.

Keywords: Regenera, Androgenetic Alopecia, Score, Hair Loss

1. Introduction

Hair restoration treatments claim to increase the number of follicles and to be able to improve hair general conditions, its health or appearance. Hair transplant aside, the truth is there is no actual treatment capable of creating hair follicles *de novo*, since a hair follicle is not a single tissue but a tiny, full anatomical structure. The Regenera[®] method is no exception to this rule, and its action is based on the regeneration and recovery of severely non-functional but still-alive hair follicles [1-4]. These are called "miniaturized" follicles and, though their presence is not pathognomonic of Androgenetic Alopecia (AA), these hypotrophic and hypofunctioning follicles are naturally found in the course of its evolution. The amount of miniaturized hair follicles is in direct relationship with the severity of AA, which is perfectly characterized by the Hamilton-Norwood and the Ludwig scales. During the initial AA stages, a fair amount of miniaturized hair follicles and units that share miniaturized and non-miniaturized hairs can be expected. The advance of AA involves a shift from miniaturized and non-miniaturized multiple hair units to single hair units. An increasing but variable

amount of miniaturized hair follicles is expected, but cannot be analyzed seriously without proper evaluation of the patient as a whole. The more miniaturized hair follicles a patient has at the beginning of the treatment, the better the expected results.

2. Material and Methods

The Regenera[®] protocol

The Regenera[®] protocol uses a special microdermatome (Regeneracons[®]) that breaks up the structure of skin by means of 2.5-mm biopsies and filters elements smaller than 50 micras [5], such as cells. The processed material is reinjected into the patient's skin at the scalp. Fiber proteins and the stratum corneum are naturally excluded, since the cell fraction obtained is the biological product desired with therapeutic action. No added chemicals or any other physical processing medium is used. The Regenera[®] protocol involves the following sequential main steps: i) Local anesthetic—Lidocaine 2% without adrenaline—, ii) Skin micrograft from the nape area—2.5 mm punch x 3—, iii) Micrograft placed in the Regeneracons[®] and in the machine —mechanical

deaggregation at 80 rpm for 1 minute—, v) Recovery of the filtered cells, and vi) Deep intradermal injection.

2.1. Tackling the Problem

For 1.5 years, clinical assessment has been the sole pillar of any outcome prospecption issued. Thus, certain clinical conditions that used to be thought as "non-favorable" slowly got established as actual contraindications or exclusion criteria for the Regenera® method: systemic pathologies, local scalp pathologies, mid or severe Androgenetic Alopecia (Hamilton Score >3, Ludwig Score >1), psychological stress, and unrealistic expectancies. In most patients, the issued prospecption was accurate or even extremely accurate when it came to foresee a poor outcome. Still, and on the other hand, we had some cases that predicted excellent results from a clinical point of view, but fail to achieve them on treatment delivery.

To overcome this obstacle, one single fact had to be

acknowledged: there was a very small but constantly growing empiricism of wrong prospecptions that could be affecting about 10% of patients expecting good results (based on the clinical assessment). At that point, it seemed obvious to us that there was something that we were missing.

Scalp dermoscopy was immediately included in routine diagnosis tests of every patient willing to be treated with the Regenera® protocol and, soon enough, we found the answer to our problem [6-7] When analyzing the data of the dermoscopy of the patients with a poor prospecption, it was clear that the expectancies related to the treatment's results were overestimated. We were considering only two different scenarios when in fact, we were facing three (Table 1): inappropriate clinical characteristics (contraindication), clinical-dermoscopic consistency (majority of cases, accurate prospecption) and clinical-dermoscopic inconsistency (small amount of cases, not accurate prospecption).

Table 1. The consistency between dermoscopy and clinical assessment expectancies affects therapeutic behavior, treatment results and prospecption.

	Good Expectancy Dermoscopy	Bad Expectancy Dermoscopy
Good Expectancy Clinical Assessment	Accurate prospecption	Not accurate prospecption
Bad Expectancy Clinical Assessment	Contraindication	Contraindication

Since a Bad Expectancy Clinical Assessment would automatically imply the contraindication of the patient, the odds of mis-prospecption were naturally reduced to Good Expectancy Clinical Assessment scenarios. The key to secure the prospecption was to establish easy-to-follow criteria that would clearly define good and bad expectancies in terms of the dermoscopic analysis (allowing physicians to distinguish them).

2.2. Building the Score

One hundred dermoscopies were evaluated. From the large amount of dermoscopic parameters assessed, eight signs stood out as very important (Table 2) and were finally included in the score (Table 3) [8-9] A Firefly DE300 dermatoscope, Firefly Global®, Belmont, USA, was used as per technical specifications. Pictures were taken with a 40X zoom.

Table 2. Dermoscopy findings included in the score.

Sign	Comment
#1 Number of hairs	Generally (with a 40X zoom), we see a lot of follicles in any patient. The number of follicles diminishes according to the advance of AA.
#2 Distance between follicles	It is related to #1, reinforces the concept of an incipient condition and gives a sense of the amount of follicles that might benefit from the procedure. The distance between follicles grows with the advance of AA.
#3 Miniaturized follicles	They are the target of the Regenera® protocol. Generally, there are a lot of miniaturized follicles on the edges of the areas where AA is advancing. Still, careful evaluation is recommended, since this is a very important but tricky parameter.
#4 Hair diameter	The presence of different hair diameters is indicative of AA advance and of hair follicle involution.
#5 Miniaturized and non-miniaturized hairs in the same follicular unit	This is a typical sign that can be seen with AA's standard evolution. Miniaturization process takes place at different moments in every follicle, even within the same follicular unit.
#6 Yellowish pigment	Follicular openings with keratotic material and/or sebum.
#7 Inflammation	Inflammatory infiltrate can be seen as a ring around the shaft, at the point where the hair merges. It is 100% not specific, but it helps to discard local damage, infectious or inflammatory conditions.
#8 Scalp general condition	A bright, white pearl-like color and absence of desquamation are good signs.

Patients were classified into four groups based on the dermoscopy findings: Ideal outcome (A), Good outcome (B), Bad outcome (C), and Extremely Bad outcome (D). Standard dermoscopic images expected for these 4 groups are shown in Figure 1.

The evolution of the 8 dermoscopy parameters for the AA pathogeny represents AA's slow progress from Figure 2A to Figure 2D. Most of the time, dermoscopy can be correlated with the patient's physical appearance (represented by the

Hamilton-Norton and Ludwig scales), and it is very tight, except for those cases that actually justify the fruition of a dermoscopy and the ultimate implementation of this study [10-11] The standard physical-appearance pictures expected for the patients of these 4 groups are shown in Figure 2. The basic idea underlying these rough, simplified and arbitrary classifications is that any patient showing an A-B pattern of physical appearance will have a very good result prospecption whenever he or she has an A-B dermoscopy pattern.

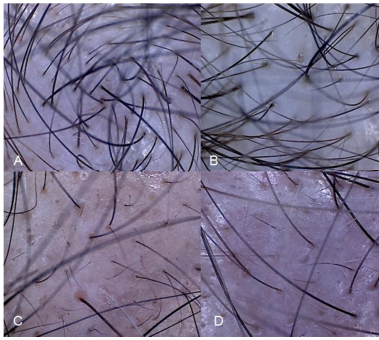


Figure 1. Patient classification based on the dermoscopy image. A: Ideal outcome, B: Good outcome, C: Bad outcome, and D: Very Bad outcome.

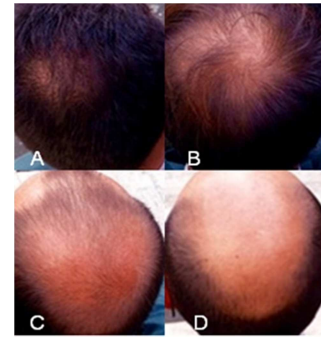

Figure 2. Patient classification based on appearance. A: Ideal outcome, B: Good outcome, C: Bad outcome, and D: Very Bad outcome.

3. Results

Issuing a recommendation

After the dermoscopic analysis was performed, the score (Table 3) was run.

Table 3. Proposed score.

Sign		1 point	0 point
#1	Number of hairs	More than a few	A few
#2	Distance between follicles	Short	Mid to long
#3	Miniaturized follicles	A lot	A few
#4	Hair diameter	Diverse	All the same
#5	Miniaturized and non-miniaturized hairs in the same follicular unit	Yes	No
#6	Yellowish pigment	No	Yes
#7	Inflammation	No	Yes
#8	Scalp general condition	Good	Not good

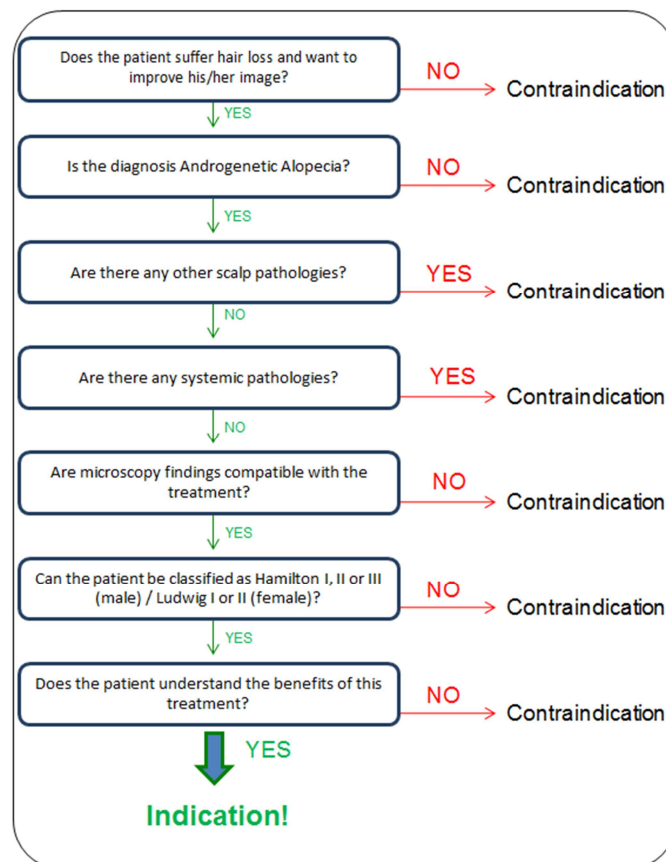


Figure 3. Patient indication and prospection algorithm.

Under a Good Expectancy Clinical Assessment (no contraindication scenarios), whenever the patient scored 6, 7 or 8 points, a good result prospection applied, and when a 5 or less point score was achieved, a good result prospection did not apply. All these data together shaped the final indication and prospection algorithm (Figure 3) used today for the Regenera[®] method.

4. Conclusion

In summary, using scalp dermoscopic findings in combination with clinical assessment expectancy to evaluate the indication of the Regenera[®] method is more likely to produce significant results when there are inconsistencies and tendency to overestimate the results of the treatment.

References

- [1] Purpura V, Bondioli E, Graziano A, Trovato L, Melandri D, Ghetti M, et al. Tissue Characterization after a New Disaggregation Method for Skin Micro-Grafts Generation. *J Vis Exp* 2016 Mar 4; (109).
- [2] Niezgoda A, Niezgoda P, Nowowiejska L, Bialecka A, Męcińska-Jundziłł K, Adamska U, Czajkowski R. Properties of skin stem cells and their potential clinical applications in modern dermatology. *Eur J Dermatol* 2017 Mar 11. doi: 10.1684/ejd.2017.2988. [Epub ahead of print].
- [3] Ibrahim ZA, Elmaadawi IH, Mohamed BM, Abdou SM, El Attar YA, Youssef A, Shamloula MM, Taha A, Gabr Metwally H, El Afandy MM, Salem ML. Stem cell therapy as a novel therapeutic intervention for resistant cases of alopecia areata and androgenetic alopecia. *J Dermatolog Treat* 2016 Aug 24: 1-30.
- [4] Svolacchia, Fabiano, Francesco De Francesco, Letizia Trovato, Antonio Graziano, and Giuseppe A. Ferraro. An Innovative Regenerative Treatment of Scars with Dermal Micrografts. *Journal of Cosmetic Dermatology* 2016 Sep; 15 (3): 245-53.
- [5] Giaccone M, Brunetti M, Camandona M, Trovato L, Graziano A. A New Medical Device, Based on Rigena Protocol, in the Management of Complex Wounds. *J Stem Cells Res, Rev & Rep* 2014; 1 (3): 1013.
- [6] Jha AK, Udayan UK, Roy PK, Amar AKJ, Chaudhary RKP. Dermoscopy of alopecia areata-a retrospective analysis. *Dermatol Pract Concept* 2017 Apr 30; 7 (2): 53-57.
- [7] Guttikonda AS, Aruna C, Ramamurthy DV, Sridevi K, Alagappan SK. Evaluation of Clinical Significance of Dermoscopy in Alopecia Areata. *Indian J Dermatol* 2016 Nov-Dec; 61 (6): 628-633.
- [8] Moreno-Arrones OM, Saceda-Corralo D, Fonda-Pascual P, Rodrigues-Barata AR, Buendía-Castaño D, Alegre-Sánchez A, Pindado-Ortega C, Molins M, Perosanz D, Segurado-Miravalles G, Jaén P, Vañó-Galván S. Frontal fibrosing alopecia: clinical and prognostic classification. *J Eur Acad Dermatol Venereol* 2017 Apr 20. doi: 10.1111/jdv.14287. [Epub ahead of print].
- [9] Younger J, Gandhi V, Hubbard E, Mackey S. Development of the Stanford Expectations of Treatment Scale (SETS): a tool for measuring patient outcome expectancy in clinical trials. *Clin Trials* 2012 Dec; 9 (6): 767-76.
- [10] Guarrera M, Cardo P, Arrigo P, Rebora A. Reliability of hamilton-norwood classification. *Int J Trichology* 2009 Jul; 1 (2): 120-2.
- [11] Hong H, Ji JH, Lee Y, Kang H, Choi GS, Lee WS. Reliability of the pattern hair loss classifications: a comparison of the basic and specific and Norwood-Hamilton classifications. *J Dermatol* 2013 Feb; 40 (2): 102-6.