

Paraneoplastic Encephalitis Due to Anti-NMDA Receptor Antibodies in a Young Woman with Ovarian Teratoma

Gonzalez Manrique Guillermo¹, Zabaleta Orozco Mario Alberto¹, Claros Ortiz Katherine Viviana¹, Cano Arias Luis Guillermo², Velasco Hoyos Maria Fernanda³, Solano Vega Irina Isabel³, Lizcano Aros Jose Alfredo³, Luna Tavera Rina Liliana⁴

¹Neurophysiology Department, Hospital Universitario Hernando Moncaleano Perdomo, Investigation Group MI DNeuropsych, Neiva, Colombia

²Gynecologic Oncology Department, Hospital Universitario Hernando Moncaleano Perdomo, Neiva, Colombia

³Internal Medicine Department, Universidad Surcolombiana, Investigation Group MI DNeuropsych, Neiva, Colombia

⁴Department of Pathology, Hospital Universitario Hernando Moncaleano Perdomo, Neiva, Colombia

Email address:

feevon@hotmail.es (Gonzalez Manrique Guillermo)

To cite this article:

Gonzalez Manrique Guillermo, Zabaleta Orozco Mario Alberto, Claros Ortiz Katherine Viviana, Cano Arias Luis Guillermo, Velasco Hoyos Maria Fernanda, Solano Vega Irina Isabel, Lizcano Aros Jose Alfredo, Luna Tavera Rina Liliana. Paraneoplastic Encephalitis Due to Anti-NMDA Receptor Antibodies in a Young Woman with Ovarian Teratoma. *European Journal of Clinical and Biomedical Sciences*. Vol. 9, No. 4, 2023, pp. 51-54. doi: 10.11648/j.ejcb.20230904.12

Received: March 16, 2023; **Accepted:** April 1, 2023; **Published:** September 25, 2023

Abstract: Anti-N-methyl D-aspartate receptor (NMDAR) encephalitis is a rare condition, often associated with neoplasms and characterized by neuropsychiatric symptoms and dysautonomia. Affecting approximately 0.01% of cancer patients, it is the second most frequent autoimmune encephalitis after acute disseminated encephalomyelitis, its clinical presentation is usually acute and severe, so prompt identification and treatment improve prognosis. We present the case of a 23-year-old female patient from a rural area of Caquetá, Colombia, previously healthy, who presented persistent psychotic symptoms of two weeks of evolution and was initially treated in a psychiatric unit where she evolved with systemic compromise. Finally, a diagnosis of paraneoplastic anti-NMDAR encephalitis was made. The patient received IV immunoglobulin G plus adjuvant systemic management with chemotherapy. She had complete resolution of her neuropsychiatric disorder and was asymptomatic when discharged. In conclusion, anti-NMDAR encephalitis is a condition with an underlying autoimmune mechanism, with production of autoantibodies mainly against the NR1 and NR2 subunits of NMDA receptors in the brain. These autoantibodies are produced in response to a breakdown of immune tolerance usually secondary to a neoplastic process, mostly ovarian teratoma, or infectious as in the case of herpes viral encephalitis. Despite its severe and potentially fatal nature, AE typically exhibits a positive response to treatment if a prompt diagnosis is established and management is initiated. However, it is acknowledged in some texts that there is still a gap in recognizing this entity, which encourages future valuable research.

Keywords: Anti-N-Methyl-D-Aspartate Receptor Encephalitis, Encephalitis, Psychosis, Autoimmune Diseases, Paraneoplastic Encephalitis

1. Introduction

Anti-N-methyl D-aspartate receptor (NMDAR) encephalitis is a rare condition, often associated with neoplasms and characterized by neuropsychiatric symptoms and dysautonomia. Affecting approximately 0.01% of cancer patients, its clinical presentation is usually acute and severe, so prompt identification and treatment improve prognosis.

The median age of presentation is 68 years old, with a slight

female predominance (52% vs. 48%). The incidence of paraneoplastic syndromes (PNS) has increased over time, from 0.62/100,000 person-years between 2009 and 2011 to 1.22/100,000 person-years between 2015 and 2017.

The most frequent PNS are limbic encephalitis, cerebellar degeneration, and encephalomyelitis. The incidence of anti-NMDAR encephalitis is approximately 2-3 cases per million people [1]. It is the second most frequent autoimmune encephalitis after acute disseminated encephalomyelitis.

We present the case of a young adult female patient who presented with a first acute psychotic episode, documenting the presence of a complex adnexal mass with histopathological evidence of an ovarian teratoma and serological confirmation of anti-NMDAR antibodies.

2. Case Presentation

We present the case of a 23-year-old female patient from a rural area of Caquetá, Colombia, previously healthy, who presented persistent psychotic symptoms of two weeks of evolution and was initially treated in a psychiatric unit where she evolved with systemic compromise due to the presence of arterial hypertension, tachycardia and fever.

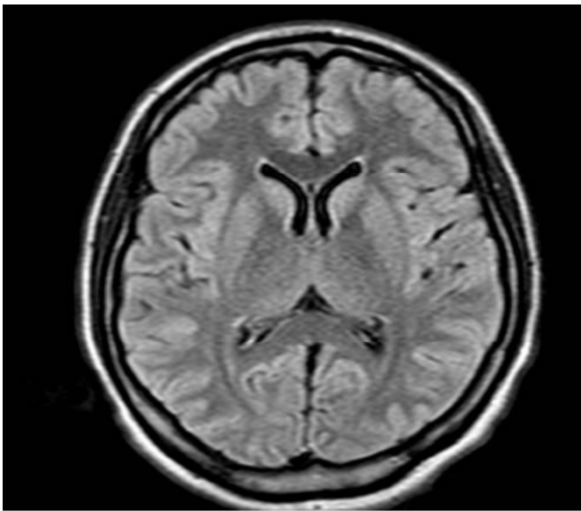


Figure 1. Brain Magnetic Resonance Imaging in FLAIR T2 Axial slice. No abnormal findings.

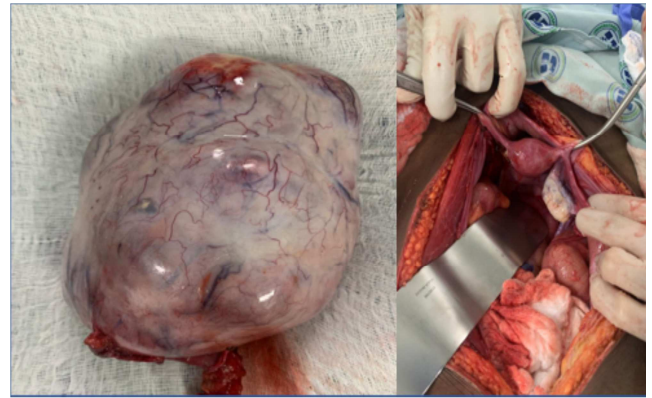


Figure 2. Left: Ovarian tumor with smooth vascularized external surface. Weight 1,080 g. It measures 17x11x9 cm. On section it is cystic, multilocular, occupied by a mucoid material that when evacuated reveals a solid area of 11x7x5 cm, with the appearance of fish flesh. Right: intraoperative image of the contralateral normal ovary.

She was referred to our institution for management in the intensive care unit under suspicion of a neuroleptic malignant syndrome. Electroencephalographic monitoring and brain MRI were performed (Figure 1), with no evidence of alterations. On physical examination, the patient presented an abdominal mass which was resected (Figure 2) with histopathological study and immunohistochemical confirmation of a mixed germinal ovarian tumor lesion of the immature teratoma type plus Yolk sac stage IA (FIGO classification, Figure 3). Finally, a diagnosis of paraneoplastic anti-NMDAR encephalitis was made. The patient received IV immunoglobulin G plus adjuvant systemic management with chemotherapy. She had complete resolution of her neuropsychiatric disorder and was asymptomatic when discharged.

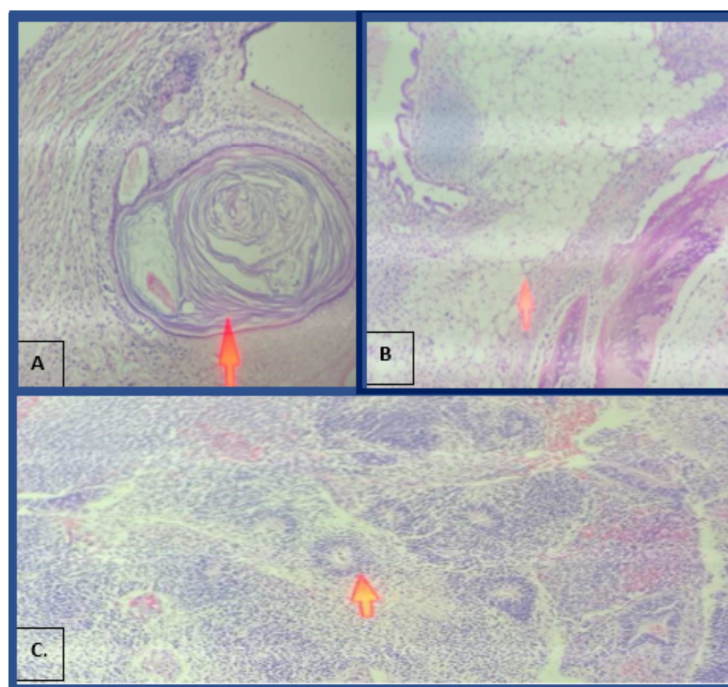


Figure 3. Histopathologic study with hematoxylin eosin, 10x objective. A: presence of ectodermal tissue with corneal pearl. B: fibroconnective tissue with presence of mature cartilage nests, fibroconnective tissue, mature adipose tissue, and osteoblasts. C: neural tissue (rosettes).

3. Discussion

Approximately 20,000 cases of encephalitis occur in the United States annually. Estimated hospitalization costs alone can exceed \$2 billion. It is common for physicians to obtain training on infectious causes of encephalitis, which was reported more often. However, in the California encephalitis project, it was noted that up to 50% of cases did not have an infectious etiology, and many have now been classified as autoimmune encephalitis (AE) cases [2].

AE affects approximately 0.01% of cancer patients, with an increasing incidence and prevalence estimated at 4/100,000. The frequency with which it is associated with a tumor varies according to age, sex, and race. The younger the patient, the less likely it is to find an associated neoplasm, except in the case of women between 12 and 45 years of age, where the prevalence of ovarian teratoma can reach up to 50% [3].

The first antibodies discovered that targeted intracellular antigens were in patients with paraneoplastic CNS disease. Then, in 2007, antibodies against the NMDA receptor that bound an antigen expressed on the cell surface were discovered. These are recognized now as one of the most common causes of AE [4].

Most paraneoplastic encephalitis has been associated with antibodies against intracellular onconeural proteins and cytotoxic T cells against the same proteins. Alterations in memory, behavior, cognition, and seizures may result from immune-mediated encephalitis. The wide range of abnormal movements and prominent orofacial involvement that remains even when the level of consciousness is low, resistance to treatment, along with psychiatric symptoms, in addition to autonomic features and central hypoventilation, distinguish anti-NMDAR encephalitis from other types of paraneoplastic encephalitis [5].

There are even cases in which prolonged treatments for diagnosis of psychiatric pathologies such as schizophrenia, or even other neurological entities such as epilepsy, being suspected only after the refractoriness of the symptoms, considered as a warning sign for the search of underlying organic etiologies such as AE [6].

In a retrospective study of 505 patients with criteria for encephalitis of unknown etiology, between 18 and 35 years of age, admitted to the intensive care unit (ICU) over five years, it was found that women of childbearing age were the group most likely to develop prominent neuropsychiatric symptoms, seizures, memory deficits and decreased level of consciousness. As in the case of our index patient.

Diagnosis requires high clinical suspicion. Initial examinations should include a cerebrospinal fluid (CSF) study that usually shows pleocytosis or increased protein concentration, suggesting inflammation or immune-mediated processes. MRI is frequently normal, but up to 55% of patients have hyperintensity on FLAIR or T2W images at the level of the medial temporal lobes followed by the cerebral cortex, cerebellum, brainstem, and basal ganglia; these findings are nonspecific and do not correlate well with symptoms [8]. Although the number of antibodies associated

with AE has expanded at a remarkable rate, in 30%-40% of patients with symptoms and signs highly suggestive of AE, in whom an infectious cause is not identified, none of the currently identified antibodies may be detected despite an exhaustive search, thus delaying early diagnosis. Early initiation of therapy in this group of patients is vital as many cases of AE appear to be treatable, and early treatment improves outcomes.

The EEG, which was normal for our case, only shows abnormality in 21% of patients, and the most common finding is generalized or predominantly frontotemporal slow waves. The definitive diagnosis is based on the presence of anti-NMDAR antibodies identified in serum or CSF. The titers of such antibodies in CSF are usually higher than in serum and correlate well with clinical symptoms [5].

As for treatment, there are no controlled studies on any form of immunotherapy in patients with paraneoplastic or autoimmune encephalitis. The first line of intervention is corticosteroids and IV immunoglobulin; a more invasive procedure is plasma exchange. In the second line, we find the more extensive immunosuppressive therapy, which includes cyclophosphamide, mycophenolate mofetil [7], and, in selected cases, Rituximab [9].

In PNS with identified neoplasia, treatment of the tumor can be beneficial. Usually, the response is adequate with immunotherapy associated with tumor removal. Although recovery is slow [10] and may require more than 18 months to achieve complete functional recovery, this occurs in 80% of cases [11]. Patients should receive symptomatic treatment as soon as possible. Specific therapies should for seizures, psychiatric manifestations, and dysautonomic manifestations should be initiated. During the psychiatric symptom phase, patients tolerate classical antipsychotics poorly and seem to have the propensity to develop the neuroleptic malignant syndrome [12].

4. Conclusion

Anti-NMDAR encephalitis is a condition with an underlying autoimmune mechanism, with production of autoantibodies mainly against the NR1 and NR2 subunits of NMDA receptors in the brain. These autoantibodies are produced in response to a breakdown of immune tolerance usually secondary to a neoplastic process, mostly ovarian teratoma, or infectious as in the case of herpes viral encephalitis [13]. The diagnosis of AE is reliant upon the detection of specific antibodies in the cerebrospinal fluid within the clinical context described. Although imaging modalities, such as magnetic resonance imaging of the brain, often appear unremarkable, they aid in excluding alternative diagnoses, such as CNS neoplasms [14]. Despite its severe and potentially fatal nature, AE typically exhibits a positive response to treatment if a prompt diagnosis is established and management is initiated. Consequently, it is imperative that clinicians develop the ability to promptly identify this condition [15].

The recognition of autoimmune encephalitis is improving.

A recent epidemiological study in Olmsted County indicated that the incidence of autoimmune encephalitis tripled from 2006 [16], attributed to greater clinical recognition and diagnostic test availability. However, it is acknowledged in some texts that there is still a gap in recognizing this entity, which encourages future valuable research.

References

- [1] Fu P, He L, Tang N, Nie Q, Li Z. A single center retrospective study of paraneoplastic neurological syndromes with positive onconeural antibodies. *Journal of Clinical Neuroscience*. 2021; 89: 336–42.
- [2] Patel, A., Koul, P., & Lado, F. (2021). The Autoimmune Encephalitis: Historical Overview (2587). *Neurology*, 96 (15 Supplement), 2587.
- [3] Vogrig A, Gigli GL, Segatti S, Corazza E, Marini A, Bernardini A, et al. Epidemiology of paraneoplastic neurological syndromes: a population-based study. *Journal of Neurology*. 2020; 267 (1): 26–35.
- [4] Midgley, L., Kelleher, E., & Zandi, M. S. Autoimmune encephalitis. *British Journal of Hospital Medicine*. 2018; 79 (9), C134–C137.
- [5] Dalmau J, Tüzün E, Wu HY, Masjuan J, Rossi JE, Voloschin A, Baehring JM, Shimazaki H, Koide R, King D, Mason W, Sansing LH, Dichter MA, Rosenfeld MR, Lynch DR. Paraneoplastic anti-N-methyl-D-aspartate receptor encephalitis associated with ovarian teratoma. *Ann Neurol*. 2007; 61 (1): 25–36.
- [6] Vaux, A., Robinson, K., Saglam, B., Cheuk, N., Kilpatrick, T., Evans, A., & Monif, M. Autoimmune Encephalitis in Long-Standing Schizophrenia: A Case Report. *Frontiers in Neurology*. 2022. 12, 1–7.
- [7] Prüss H, Dalmau J, Harms L, Hölting M, Ahnert-Hilger G, Borowski K, et al. Retrospective analysis of NMDA receptor antibodies in encephalitis of unknown origin. *Neurology*. 2010; 75 (19): 1735–9.
- [8] Abboud H, Probasco JC, Irani S, Ances B, Benavides DR, Bradshaw M, et al. Autoimmune encephalitis: Proposed best practice recommendations for diagnosis and acute management. Vol. 92, *Journal of Neurology, Neurosurgery and Psychiatry*. BMJ; 2021. p. 757–68.
- [9] Lee WJ, Lee ST, Byun JI, Sunwoo JS, Kim TJ, Lim JA, et al. Rituximab treatment for autoimmune limbic encephalitis in an institutional cohort. *Neurology*. 2016 May 3; 86 (18): 1683–91.
- [10] Gresa-Arribas N, Titulaer MJ, Torrents A, et al. Antibody titres at diagnosis and during follow-up of anti-NMDA receptor encephalitis: a retrospective study. *Lancet Neurol* 2014; 13: 167.
- [11] Vedeler CA, Antoine JC, Giometto B, et al. Management of paraneoplastic neurological syndromes: report of an EFNS Task Force. *Eur J Neurol* 2006; 13: 682.
- [12] Lejoste F, Thomas L, Picard G, et al. Neuroleptic intolerance in patients with anti-NMDAR encephalitis. *Neurol Neuroimmunol Neuroinflamm* 2016; 3: e280.
- [13] Granerod J, Dphil A, Clewley JP, Walsh AL, Morgan D, Brown Frepath WG, et al. Causes of encephalitis and differences in their clinical presentations in England: a multicentre, population-based prospective study. *Lancet Infect Dis*. 2010 Dec; 10 (12): 835–44.
- [14] Lawn ND, Westmoreland BF, Kiely MJ, et al. Clinical, magnetic resonance imaging, and electroencephalographic findings in paraneoplastic limbic encephalitis. *Mayo Clin Proc* 2003; 78: 1363.
- [15] Dalmau J, Graus F. Autoimmune Encephalitis-Misdiagnosis, Misconceptions, and How to Avoid Them. *JAMA Neurol*. 2023 Jan 1; 80 (1): 12–14.
- [16] Britton, J. W., & Dalmau, J. Recognizing autoimmune encephalitis as a cause of seizures: Treating cause and not effect. *Neurology*. 2019; 92 (19), 877–878.