

**Case Report**

# Cerebral Venous Sinus Thrombosis in a 40-year-old Lady with JAK2-positive Polycythemia Vera: A Case Report

Maliha Hakim<sup>1,\*</sup>, Mohammad Nur Uddin<sup>1</sup>, Fatema Ahmed<sup>2</sup>, Mashfiqul Hasan<sup>3</sup>

<sup>1</sup>Department of Neurology, National Institute of Neurosciences & Hospital, Dhaka, Bangladesh

<sup>2</sup>Discipline of Hematology, National Institute of Neurosciences & Hospital, Dhaka, Bangladesh

<sup>3</sup>Discipline of Neuroendocrinology and Diabetes, National Institute of Neurosciences & Hospital, Dhaka, Bangladesh

**Email address:**

malihahakimnins@gmail.com (M. Hakim)

\*Corresponding author

**To cite this article:**

Maliha Hakim, Mohammad Nur Uddin, Fatema Ahmed, Mashfiqul Hasan. Cerebral Venous Sinus Thrombosis in a 40-year-old Lady with JAK2-positive Polycythemia Vera: A Case Report. *Clinical Neurology and Neuroscience*. Vol. 5, No. 3, 2021, pp. 60-62.

doi: 10.11648/j.cnn.20210503.15

**Received:** August 8, 2021; **Accepted:** August 23, 2021; **Published:** August 31, 2021

---

**Abstract:** Cerebral venous sinus thrombosis (CVST) has a range of underlying cause. Here a case of CVST with an uncommon etiology is presented and discussed. A 40-year-old female presented with headache for 2 years and progressive visual loss for 4 months. She had conjunctival congestion and bilateral papilloedema with pale disc on right side. Computed tomography (CT) scans and contrast magnetic resonance imaging (MRI) of brain were normal but venography (MRV) revealed widespread thrombosis of dural sinuses including superior sagittal sinus. Cerebrospinal fluid (CSF) pressure was high (360 mm of H<sub>2</sub>O) while other CSF parameters were normal. She was polycythemic (hemoglobin 18.1 g/dl, hematocrit 60.2%), Bone marrow study revealed pan-myeloid hyperplasia whereas trephine biopsy revealed hypercellular marrow with trilineage expansion suggestive of myeloproliferative disorder possibly polycythemia vera. JAK-2 mutation was also detected. CVST has different patterns of presentations including isolated intracranial hypertension leading to visual loss. It is essential to identify and treat underlying condition like polycythemia vera.

**Keywords:** Cerebral Venous Sinus Thrombosis, Polycythemia Vera, Intracranial Hypertension

---

## 1. Introduction

In 'Cerebral venous sinus thrombosis' (CVST) the process of thrombosis affects the venous side of the brain circulation and leads to occlusion of one or more dural venous sinuses [1]. The incidence of CVST is estimated to be 1.32 per 100 thousand populations per year in developed countries [2]. But the incidence may be higher in developing countries. It was experienced that CVST was the cause of admission to the neurology department of the National Institute of Neurosciences, Dhaka, Bangladesh in 0.9% (53 out of 5752) and 1.3% (79 out of 6162) patients during 2017 and 2018 respectively. Common risk factors of CVST are pregnancy, puerperium, infections, dehydration and prothrombotic drugs like oral contraceptive pills. Risk factors like genetic thrombophilic diseases, antiphospholipid syndrome and

myeloproliferative syndromes are relatively rare but important to identify and manage [3]. Here a case of CVST with an uncommon etiology is presented and discussed.

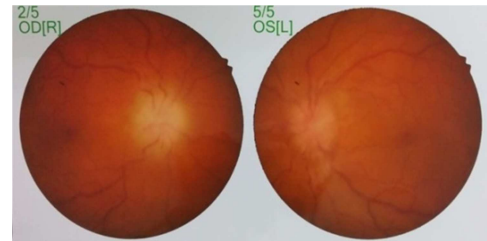## 2. Case Report

A 40-year-old female was admitted in neurology department of National Institute of Neurosciences and hospital for evaluation of headache and visual loss. She had chronic daily headache with occasional exacerbation for last 2 years, which was dull and continuous in nature with mild to moderate intensity. It had no specific aggravating factor and relieved to some extent after taking analgesics like paracetamol and tolfenamic acid. Headache was not associated with fever, vomiting, photophobia or seizure. For the last 4 months she noticed progressive dimness of vision in

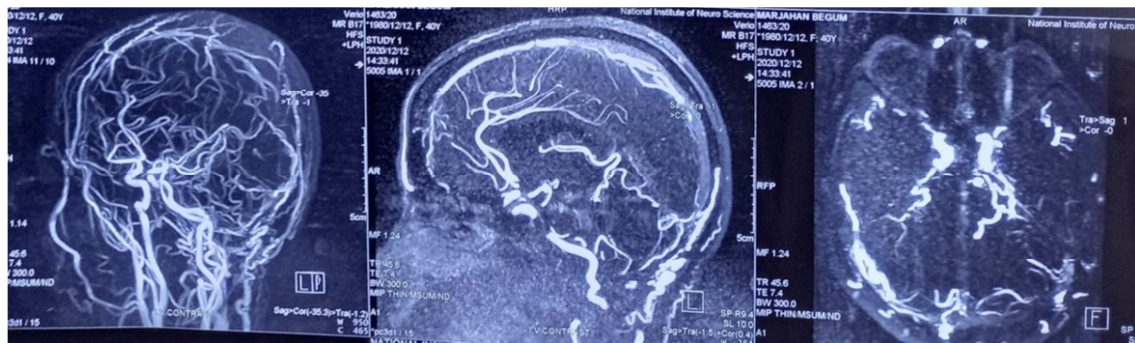
the right eye that progressed to complete loss of vision 2-months back. Vision of left eye also started deteriorating 1-month back. She had no history of painful red eye and there was no diplopia or pain on eye movement. She was mother of 4 children and had no history of fetal loss. She used oral contraceptive pill for long duration and discontinued only 4 months back. On examination, she was depressed looking and irritable. She had conjunctival congestion and bilateral papilloedema with pale disc on right side (Figure 1). Other systemic and neurological examination was unremarkable.

Computed tomography (CT) scans and contrast magnetic resonance imaging (MRI) of brain was normal but venography (MRV) revealed widespread thrombosis of dural sinuses including superior sagittal sinus, both transverse-sigmoid sinuses and straight sinus (Figure 2). Cerebrospinal fluid (CSF) pressure was high (360 mm of H<sub>2</sub>O) while other CSF parameters were normal. She was polycythemic (hemoglobin 18.1 g/dl, hematocrit 60.2%), along with high WBC and platelet count (17,500 and 940,000 per cubic mm respectively)

with a low normal ESR (5 mm in 1<sup>st</sup> hour). Bone marrow study revealed pan-myeloid hyperplasia whereas trephine biopsy revealed hypercellular marrow with trilineage expansion of erythrocyte, granulocyte and hypobulbated mature megakaryocytes suggestive of myeloproliferative disorder possibly polycythemia vera. JAK-2 mutation was also detected. Chest X-ray, ultrasonogram of abdomen and echocardiography were normal.



**Figure 1.** Color fundus photography showing bilateral papilloedema and pale optic disc on right side.



**Figure 2.** Magnetic resonance venography (MRV) of brain showing widespread thrombosis of dural sinuses including superior sagittal sinus, both transverse-sigmoid sinuses and straight sinus.

Optic nerve sheath fenestration was done to prevent rapid deterioration of vision due to secondary intracranial hypertension. Thereafter she was started on anticoagulants. For the treatment of polycythemia rubra vera, hydroxyurea was started along with weekly venesection. Currently she is under regular follow up.

### 3. Discussion

The presenting symptoms of CVST are often variable [3]. Headache is the most common presenting complaint in CVST but no characteristic pattern distinguishes it from other primary or secondary headaches. However, a change of stable daily headache to rapid and progressive pattern indicates possible secondary etiology of headache like CVST especially when associated with other neurological symptoms [4]. Seizures are common consequences of CVST and may occur soon after onset [5]. Other common symptoms are, vomiting and hemiparesis [6]. Papilloedema is commonly present during diagnosis [7]. However, few distinct patterns of presentation is recognized [3]. Patients with isolated intracranial hypertension presents with headache, papilloedema and decreased visual acuity similar to the index case. They do not usually have symptoms like seizures,

neurological deficits or coma. It is documented that patients with thrombosis of superficial venous system and parenchymal lesions present with focal neurological deficits and seizures. Involvement of deep venous system results in diffuse encephalopathy and coma. In some patients, involvement of cavernous sinus presents with distinct features of cavernous sinus syndrome, orbital pain, chemosis, proptosis and ophthalmoplegia.

An unenhanced CT scan may give some clue regarding the diagnosis of CVST. A clot in the superior sagittal sinus may be manifested as 'dense triangle sign' and thrombosis of cortical or deep veins as 'cord sign'. 'Empty delta sign' may be seen in contrast CT due to contrast enhancement of the thrombosed sinus. But these signs are only present in limited number of patients and are less common in subacute or chronic cases [8]. There may also be venous infarcts that often cross arterial boundaries and hemorrhage ranging from scattered subcortical to lobar hematoma [9]. More appropriate tools to reach a diagnosis of CVST are Magnetic resonance venography (MRV) and CT venography (CTV) [10]. Nevertheless, interpretation of these venography procedures is difficult in presence of hypoplastic sinus, cortical vein thrombosis or partial sinus occlusion [11]. Clinical correlation is necessary to resolve such dilemma.

Clinical evaluation and investigations should aim at finding an underlying cause of CVST. Recommended laboratory tests include complete blood count, biochemical and metabolic parameters, urinalysis, prothrombin time, and activated partial thromboplastin time [12]. In the index case, evidence of underlying cause was present in complete blood count. In fact, conditions like genetic thrombophilic diseases, antiphospholipid syndrome, malignancies and myeloproliferative disorders are important to identify as they are regarded as permanent risk factors of CVST. Of the various myeloproliferative disorders, polycythemia vera (PV) may cause thrombosis due to hyperviscosity and stasis of blood. Thrombosis of cerebral sinuses impairs CSF absorption and leads to increased intracranial pressure [13]. Mutations of Janus kinase gene (JAK2) may be present in all types of myeloproliferative disorders. Its sensitivity is high and specificity is virtually 100% for distinguishing PV from other causes of raised hematocrit. Bone marrow morphology is needed to confirm the diagnosis [14].

Although the clinical course is unpredictable in CVST presenting with acute symptoms, the long term outcome is not unfavorable [15]. Transtentorial herniation, status epilepticus and pulmonary embolism are causes of early deterioration [16]. Severe visual loss due to intracranial hypertension is rare but important to address. Acetazolamide has limited role in reducing intracranial pressure in CVST and use of steroids are often discouraged [17]. In patients with threatened vision, neurosurgical procedure is indicated to reduce intracranial pressure especially when recanalization of cerebral venous sinus cannot be achieved promptly [18].

## 4. Conclusions

In conclusion, CVST has different patterns of presentations including isolated intracranial hypertension leading to visual loss. It is essential to identify and treat underlying condition like polycythemia vera for proper management.

## References

- [1] Ferro JM, Boussier MG, Canhão P, Coutinho JM, Crassard I, Dentali F, di Minno M, Maino A, Martinelli I, Masuhr F, de Sousa DA. European Stroke Organization guideline for the diagnosis and treatment of cerebral venous thrombosis—endorsed by the European Academy of Neurology. *European stroke journal*. 2017 Sep; 2 (3): 195-221.
- [2] Coutinho JM, Zuurbier SM, Aramideh M, Stam J. The incidence of cerebral venous thrombosis: a cross-sectional study. *Stroke*. 2012 Dec; 43 (12): 3375-7.
- [3] Silvis SM, de Sousa DA, Ferro JM, Coutinho JM. Cerebral venous thrombosis. *Nat Rev Neurol*. 2017 Sep; 13 (9): 555-565.
- [4] Singh RJ, Saini J, Varadharajan S, Kulkarni GB, Veerendrakumar M. Headache in cerebral venous sinus thrombosis revisited: Exploring the role of vascular congestion and cortical vein thrombosis. *Cephalalgia*. 2018 Mar; 38 (3): 503-510.
- [5] Mehvari Habibabadi J, Saadatnia M, Tabrizi N. Seizure in cerebral venous and sinus thrombosis. *Epilepsia Open*. 2018 Jun 8; 3 (3): 316-322.
- [6] Rajoor UG, Sindhur JC, Gundikeri SK, Patil P. Cerebral Venous Thrombosis in Adults: An Experience from a Tertiary Teaching Hospital in Dharwad, Karnataka. *Indian Journal of Public Health Research & Development*. 2014 Jan 1; 5 (1).
- [7] Liu KC, Bhatti MT, Chen JJ, Fairbanks AM, Foroozan R, McClelland CM, Lee MS, Satija CE, Francis CE, Wildes MT, Subramanian PS, Williams ZR, El-Dairi MA. Presentation and Progression of Papilledema in Cerebral Venous Sinus Thrombosis. *Am J Ophthalmol*. 2020 May; 213: 1-8.
- [8] Leach JL, Fortuna RB, Jones BV, Gaskill-Shipley MF. Imaging of cerebral venous thrombosis: current techniques, spectrum of findings, and diagnostic pitfalls. *Radiographics*. 2006 Oct; 26 Suppl 1: S19-41; discussion S42-3.
- [9] Qu H, Yang M. Early imaging characteristics of 62 cases of cerebral venous sinus thrombosis. *Exp Ther Med*. 2013 Jan; 5 (1): 233-236.
- [10] Gao L, Xu W, Li T, Yu X, Cao S, Xu H, Yan F, Chen G. Accuracy of magnetic resonance venography in diagnosing cerebral venous sinus thrombosis. *Thromb Res*. 2018 Jul; 167: 64-73.
- [11] Pallewatte, A. S., Tharmalingam, T. and Liyanage, N., 2016. Anatomic variants and artefacts in non enhanced MRV – potential pitfalls in diagnosing cerebral venous sinus thrombosis (CVST). *Sri Lanka Journal of Radiology*, 2 (1), pp. 40–46.
- [12] Saposnik G, Barinagarrementeria F, Brown RD Jr, Bushnell CD, Cucchiara B, Cushman M, deVeber G, Ferro JM, Tsai FY; American Heart Association Stroke Council and the Council on Epidemiology and Prevention. Diagnosis and management of cerebral venous thrombosis: a statement for healthcare professionals from the American Heart Association/American Stroke Association. *Stroke*. 2011 Apr; 42 (4): 1158-92.
- [13] Stam J. Thrombosis of the cerebral veins and sinuses. *N Engl J Med*. 2005 Apr 28; 352 (17): 1791-8.
- [14] Tefferi A, Barbui T. Polycythemia vera and essential thrombocythemia: 2021 update on diagnosis, risk-stratification and management. *Am J Hematol*. 2020 Dec; 95 (12): 1599-1613.
- [15] Khan MWA, Zeeshan HM, Iqbal S. Clinical Profile and Prognosis of Cerebral Venous Sinus Thrombosis. *Cureus*. 2020 Dec 22; 12 (12): e12221.
- [16] Canhão P, Ferro JM, Lindgren AG, Boussier MG, Stam J, Barinagarrementeria F; ISCVT Investigators. Causes and predictors of death in cerebral venous thrombosis. *Stroke*. 2005 Aug; 36 (8): 1720-5.
- [17] Canhão P, Cortesão A, Cabral M, Ferro JM, Stam J, Boussier MG, Barinagarrementeria F; ISCVT Investigators. Are steroids useful to treat cerebral venous thrombosis? *Stroke*. 2008 Jan; 39 (1): 105-10.
- [18] Ding J, Zhou D, Geng T, Pan L, Ya J, Wang Z, Hu Y, Ding Y, Zhang X, Meng R. To Predict Visual Deterioration According to the Degree of Intracranial Hypertension in Patients with Cerebral Venous Sinus Thrombosis. *Eur Neurol*. 2018; 80 (1-2): 28-33.