

Surgical Results of Transoral Endoscopic Thyroidectomy Vestibular Approach (TOETVA) Compared to Open Thyroidectomy in Patient with Benign Thyroid Nodule

Kornwalee Koichusakul^{1,*}, Khwannara Ketwong^{2,*}

¹Department of Surgery, Chiangrai Prachanukroh Hospital, Chiang Rai, Thailand

²Department of Surgery, Chularat 3 International Hospital, Samut Prakan, Thailand

Email address:

suangsii06@gmail.com (K. Koichusakul), iamhero501@yahoo.com (K. Ketwong)

*Corresponding author

To cite this article:

Kornwalee Koichusakul, Khwannara Ketwong. Surgical Results of Transoral Endoscopic Thyroidectomy Vestibular Approach (TOETVA) Compared to Open Thyroidectomy in Patient with Benign Thyroid Nodule. *Advances in Surgical Sciences*. Vol. 9, No. 2, 2021, pp. 15-19. doi: 10.11648/j.ass.20210902.11

Received: August 4, 2021; **Accepted:** August 16, 2021; **Published:** September 4, 2021

Abstract: Background: Transoral endoscopic thyroidectomy vestibular approach (TOETVA) is an innovative technique to perform thyroidectomy which provides excellent cosmetic and surgical outcomes. Methods: Between June 2018 to January 2020 all patients pathological diagnosis with benign thyroid nodule in Chiangrai Prachanukroh Hospital were reviewed retrospectively. TOETVA and Open thyroidectomy were performed in 55 cases per each group, respectively. Patient baseline characteristics and surgical results, including postoperative pain, estimate blood loss, operative time, length of hospital stay and postoperative complications, were investigated and compared. Results: TOETVA and open thyroidectomy was performed on 110 consecutive patients. The baseline characteristics were similar in both groups. The mean postoperative visual analog scale for pain score in the first three days was comparable for both groups (4.43 [2.01] vs 3.73 [2.5], $P=0.126$). Mean estimate blood loss was not statistically different for both groups (20 [76.19] vs 30 [44.28] ml, $P=0.302$). But the median operative time was longer for the TOETVA group compared to the open thyroidectomy group (120 [61.55] vs 60 [33.70] mins, $P=0.00003$). Mean length of stay was comparable for both groups (3.7 [0.98] vs 3.43 [1.05] days, $P=0.072$). For the postoperative complication, 3 patients (5.45%) in TOETVA and 6 patients (10.91%) in open thyroidectomy group has recurrent laryngeal nerve injury. One patient (1.82%) had hypocalcemia in both groups. In TOETVA group, one patient (1.82%) had wound infection and one patient (1.82%) had transient mental nerve injury. Conclusion: TOETVA is an effective and safe surgical approach for benign thyroid nodule with excellent cosmetic outcome. This technique is a reasonable optional treatment for patients who demanded a scarless wound. The surgical outcomes and complication rates were similar but TOETVA is associated with longer operative time.

Keywords: TOETVA, Thyroidectomy, Transoral Endoscopic Thyroidectomy Vestibular Approach, Benign Thyroid Nodule

1. Introduction

Conventional open thyroidectomy is an accepted surgical treatment for patient with benign thyroid nodule, which leads to a noticeable cervical scar from big collar incision. Many of the patients especially young women are concerned about their aesthetical aspect. Thus, Various technique of minimal invasive surgery for thyroid disease has been invented.

The history of minimal invasive thyroid surgery has been established since the last two decades. Development of

endoscopic procedure has provided surgeons to perform a thyroidectomy with no scar in the anterior neck. These techniques including the transaxillary approach, bilateral axillo-breast approach, and a facelift approach. Recently, The technique of natural orifice transluminal endoscopic surgery (NOTES) which perform thyroidectomy via sublingual access have been promoted since 2009 [1]. The new procedure has an excellent cosmetic effect but the procedure

is limited due to the associated complications. Subsequently, oral vestibular techniques have been developed. The Transoral Endoscopic Thyroidectomy Vestibular Approach (TOETVA) was demonstrated to have less complications and better surgical results. However, there are still debates whether TOETVA approach is appropriated. Besides, limited data about the efficacy of TOETVA are published. The aim of this paper is to compare the surgical results of TOETVA with those standard open thyroidectomy in patients with benign thyroid nodule. [2, 6-8]

2. Methods

Between June 2018 to January 2020, we retrospectively review all patients who were diagnosed with benign thyroid nodule and underwent thyroid surgery in Chiangrai Prachanukroh Hospital, Thailand. Both TOETVA and standard open thyroidectomy technique were performed by experienced one MIS surgeon and high volume general surgeons. The method for thyroidectomy was based on the patients preferences. The study was approved by Chiangrai Prachanukroh hospital Ethics committee and all participants were provided the particular details for their surgeries and informed consent obtained from each patient.

Inclusion criteria included all patients with benign thyroid nodule diagnosed by pathological report. Exclusion criteria comprised patients who were (I) unfit for surgery; (II) Unable to tolerate general anesthesia; (III) Other diagnosis of thyroid disease apart from benign thyroid nodule. (table 1)

Table 1. Baseline Characteristics of Patients.

Baseline characteristics	TOETVA (n=55)	OT (n=55)	P-value
Age, mean (SD)	40	42.85	0.1065
Sex			
Male	0	0	
Female	55 (100%)	55 (100%)	
Mean Tumor size, mean (cm)	3.32	3.11	0.2826
Operation			
-Total thyroidectomy	8 (14.55%)	5 (9.10%)	
-Hemithyroidectomy	47 (85.45%)	50 (90.90%)	

SD=Standard Deviation, TOETVA=Transoral Endoscopic Thyroidectomy Vestibular Approach, OT=Open Thyroidectomy

2.1. Study Protocol

All patients were examined preoperatively with thyroid function tests, thyroid ultrasonography and cytology testing by fine-needle aspiration. In Open thyroidectomy, no perioperative antibiotic was given in this group. In TOETVA. Antibiotic named Amoxicillin-clavulanic acid 1.2 g was intravenously injected 30 minutes before incision and were continued for 2 days postoperative, subsequently, an oral form was given for total 7 days. Postoperative pain control was the same in the both groups. All patients had follow up examination at 2 weeks and 1 month. Follow-up evaluation included clinical examinations for their surgical wound, recurrent laryngeal nerve injury, hypoparathyroidism and a thyroid function test. [2, 3]

2.2. Operative Techniques

2.2.1. Transoral Endoscopic Thyroidectomy Vestibular Approach [1-5, 9]

For TOETVA surgical procedure, the patient was performed under general anesthesia and with nasotracheal intubation, position of operation is slightly neck extension under a sand bag under shoulders. 0.05% Hibitane water was used to clean the oral cavity. The working space at subplatysmal plane was created by injection of 1 mg adrenaline diluted with 300 ml of normal saline injected into the oral vestibular area of the lower lips down to the anterior neck. A 10 mm port was inserted at the midline of the oral vestibule. Then, two 5 mm trocars were inserted at the lateral junction between the canine and first premolar teeth under the lower lip at the oral vestibular area. A standard 10 mm laparoscope was used, The working space was created down to the sternal notch with the lateral border at the sternocleidomastoid muscles. Strap muscles were opened at the median raphe. Then, strap muscles were retracted laterally by a transcutaneous 2/0 silk suture for better exposure. Thyroid isthmus was transected by an ultrasonic device. Afterwards, the middle thyroid vein and superior thyroid vessels were ligated as close to the thyroid as possible. The recurrent laryngeal nerve (RLN) was identified and preserved as well as the upper and lower parathyroid glands. Then inferior thyroid vessel was ligated, a thyroid lobe specimen was placed in a sterile bag and removed through the 10 mm central incision. Strap muscles were closed using absorbable sutures. Finally, The oral vestibule mucosa was closed using absorbable sutures and a pressure dressing was placed around the chin and upper neck for 24 hours. For total thyroidectomy, the operation was performed in the same manner on the contralateral side (Figures 1-4 at the last page).

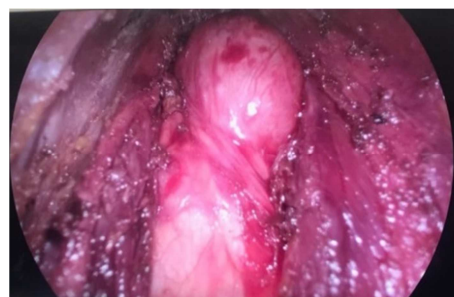

Figure 1. Rt thyroid lobe was identified.

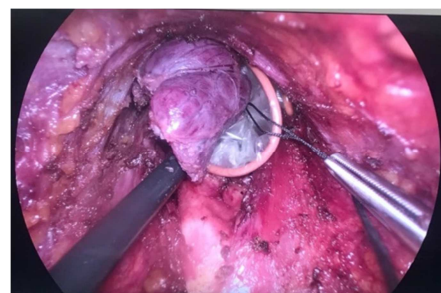


Figure 2. Rt thyroid lobe was dissected and removed.

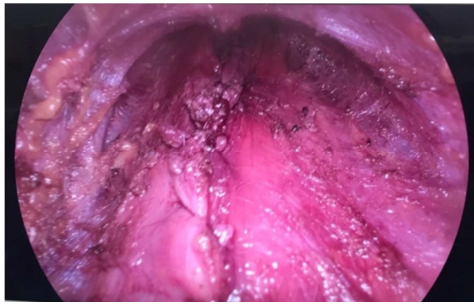

Figure 3. Strap muscles were closed.

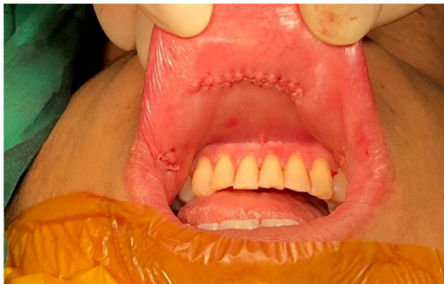

Figure 4. Oral vestibule incision after suturing.

2.2.2. Open Thyroidectomy

For conventional open thyroidectomy technique, the patient was placed in a supine position. A transverse collar incision on the anterior neck was performed. After dissecting an adequate subplatysmal flap up to the thyroid cartilage and down to the sternal notch, the strap muscle were opened in the midline to expose the thyroid gland. Lateral dissection of the thyroid gland was performed. The middle thyroid vein was identified and ligated. Subsequently, Superior thyroid vessels were ligated closed to the thyroid gland. The recurrent laryngeal nerve was identified and preserved. The inferior thyroid vessels were ligated. The lower parathyroid gland was identified and preserved. Berry ligament was then dissected and finally, the isthmus was transected, the operation was performed in the same manner on the contralateral side for total thyroidectomy. A closed suction drain was placed below the strap muscle and a pressure dressing was applied.

2.3. Outcomes

Medical records were reviewed for patient characteristics and surgical outcomes, including age, gender, size of thyroid (cm) by pathological report and operative procedure. The overall surgical endpoints included postoperative pain as measured by the mean visual analog scale (VAS). Operative time (min), estimate blood loss (ml) length of stay in days and postoperative complications in the two study groups. Perioperative complications were infection, hoarseness from recurrent laryngeal nerve injury, mental nerve injury and hypoparathyroidism were evaluated. All patients underwent follow up based on the same manners as protocol mention above.

2.4. Statistical Analysis

All data were expressed as mean \pm SD for continuous variables and number for categorical variables. Baseline

characteristics were compared using the Fisher exact test for categorical variables and the independent, -2tailed, paired t test for continuous variables. All statistical tests with P value <0.05 were considered statistically significant. Statistical analysis was performed with SPSS statistical software, version 20.0 (IBM Inc).

3. Results

All 110 patients who underwent thyroidectomy in Chiangrai Prachanukroh hospital and pathologic diagnosis with benign thyroid nodule between June 2018 and January 2020 were included. Fifty-five patients underwent TOETVA were included in the analysis (All are females). The mean age was 40 ± 15.12 years and the mean tumor size was 3.32 ± 2.41 cm. A total of 47 patients (85.45%) underwent hemithyroidectomy, and 8 patients (14.55%) underwent total thyroidectomy. Concurrently, There were 55 patients enrolled in open thyroidectomy group (we included all female patients and patient age younger than 60 years to equalize baseline characteristic). The mean age was 42.85 ± 8.16 years and the mean tumor size was 3.11 ± 1.08 cm. In this group, 50 patients (90.90%) underwent hemithyroidectomy, and 5 patients (9.10%) underwent total thyroidectomy. The baseline characteristics between TOETVA and OT group, including the number of patients, gender, ages, mean tumor size and operative procedure were similar (Table 1).

The overall mean VAS pain score in the first 3 days was 4.43 ± 2.01 in TOETVA and 3.73 ± 2.50 in OT ($P=0.126$). Median estimated blood loss was 20 ± 76.19 ml in TOETVA and 30 ± 44.28 ml in OT ($P=0.302$). Median operative time was 120 ± 61.55 mins in TOETVA and 60 ± 33.70 mins in OT ($P=0.00003$). Mean length of stay was 3.7 ± 0.98 days in TOETVA and 3.43 ± 1.05 days in OT ($P=0.072$), respectively. For the postoperative complication, 3 patients (5.45%) in TOETVA and 6 patients (10.91%) in OT has RLN injury, all cases in TOETVA group resolved within 6 months but 2 patient in OT group had permanent hoarseness. One patient (1.82%) had hypoparathyroidism in both groups. One patient (1.82%) had wound infection and one patient (1.82%) had transient mental nerve injury (Table 2).

Table 2. Comparison of Surgical Outcomes Between the TOETVA and OT Groups.

Surgical Results	TOETVA (n=55)	OT (n=55)	P-Value
Mean VAS (mean) Day 0-3	4.43	3.73	0.1264
Day 0	5.48	4.98	0.0116
Day 1	4.31	3.55	0.0030
Day 2	3.5	2.67	0.4435
Blood loss (median), ml	20	30	0.3017
Op time (median), mins	120	60	0.00003
LOS (mean), days	3.7	3.43	0.0722
Complication (n)	6 (10.91%)	7 (12.73%)	
Hoarseness	3 (All temporary)	6 (2 permanen)	
Hypoparathyroid	1	1	
Infection	1	0	
Mental nerve injury	1	0	

SD=Standard Deviation, TOETVA=Transoral Endoscopic Thyroidectomy Vestibular Approach, OT=Open Thyroidectomy

$P < 0.05$ is considered statistically significant. Values are mean \pm SD for continuous variables and n for categorical variables. P-values are from the t-test for the continuous variables and from Fisher's exact test for the categorical variables.

4. Discussion

Currently, there is limited data published on the results of endoscopic thyroidectomy in benign thyroid nodule patients, and not many surgeons can do this operation. Therefore, we calculated n of this research from pilot study and got a number of 55 each side. The clinical characteristics between the 2 groups were similar except for their gender and age, this difference is most likely referable to patient selection (most of the patient in TOETVA group were young and female). Thus, in OT group we choose all female patients and those with age younger than 60 years to equalize the baseline characteristic.

According the results of this study, The TOETVA group had a significantly longer operative time compared with the OT group. This can be explained from additional time to create the working space and apply 3 ports insertion in TOETVA group. However, operative time may decrease after a learning curve.

We conclude that the safety and efficacy of TOETVA were similar to OT because no significant differences were found in postoperative pain, estimate blood loss, length of stay or complication rates between 2 groups. For TOETVA, RLN injury occurred less because it is easier to endoscopically dissect the RLN from top down first at its insertion. In addition, visualization of RLN from endoscope is more obvious than those with OT. This study reported no patients with permanent RLN injury in TOETVA group but found in 2 patients from OT group. The incidence of hypoparathyroidism in this study was similar to OT. There is no patient with permanent hypoparathyroidism. The endoscopic intensified view may allow for better identification of the parathyroid glands. One patient reported surgical site infection in TOETVA group which can be resolved by oral antibiotics because transoral incision are classified as clean-contaminated wound which provides higher risk of infection.

Certainly, TOETVA provides better cosmetic results according to the invisible oral vestibule incisions. However, from review literature [10-19], there is no prospective study to demonstrate the effectiveness and safety of this procedure. Therefore, long term follow-up well designed randomized control trials are required.

5. Conclusion

TOETVA is an effective and safe surgical approach for benign thyroid nodule with excellent cosmetic outcome. This technique is a reasonable optional treatment for patients who demanded to avoid a neck scar. The surgical outcomes and complication rates were comparable to those of open

thyroidectomy but TOETVA is associated with longer operative time.

Author Contributions

- (I) Conception and design: All authors
- (II) Administrative support: Koichusakul
- (III) Provision of study materials or patients: All authors
- (IV) Collection and assembly of data: Koichusakul
- (V) Data analysis and interpretation: All authors
- (VI) Manuscript writing: All authors
- (VII) Final approval of manuscript: All authors

Conflicts of Interest

The authors have no conflict of interest to declare.

Ethical Statement

The authors are accountable for all aspects of the work in ensuring that questions related to the accuracy or integrity of any part of the work are appropriately investigated and resolved.

References

- [1] Anuwong A, Ketwong K, Jitpratoom P, Sasanakietkul T, Duh QY. Safety and outcomes of the transoral endoscopic thyroidectomy vestibular approach. *JAMA Surg.* 2018; 153 (1): 21-27.
- [2] Jongekkasit I, Jitpratoom P, Sasanakietkul T, et al. Transoral Endoscopic Thyroidectomy for Thyroid Cancer. *Endocrinol Metab Clin North Am* [Internet]. 2019 Mar [cited 2021 May]; 48 (1): 165-180. Available from: <https://www.sciencedirect.com/science/article/abs/pii/S0889852918305966?via%3Dihub> DOI: 10.1016/j.ecl.2018.11.009.
- [3] Liu Z, Peng X, Li Z, et al. Postoperative drain after transoral endoscopic thyroidectomy vestibular approach (TOETVA) with single incision. *Surg Endosc* [Internet]. 2021 Jan [cited 2021 May]; 35 (1): 358-366. Available from: <https://dx.doi.org/10.1007/s00464-020-07408-8> DOI: 10.1007/s00464-020-07408-8.
- [4] Jitpratoom P, Ketwong K, Sasanakietkul T, Anuwong A. Transoral endoscopic thyroidectomy vestibular approach (TOETVA) for Graves' disease: a comparison of surgical results with open thyroidectomy. *Gland Surg.* 2016; 5 (6): 546-552.
- [5] Chen YH, Kim HY, Anuwong A, Huang TS, Duh QY. Transoral robotic thyroidectomy versus transoral endoscopic thyroidectomy: a propensity-score-matched analysis of surgical outcomes. *Surg Endosc* [Internet]. 2020 Oct 27 [cited 2021 May]. Available from: <https://link.springer.com/article/10.1007%2Fs00464-020-08114-1> DOI: 10.1007/s00464-020-08114-1.
- [6] Pérez-Soto RH, Ponce de León-Ballesteros G, Montalvo-Hernández J, et al. Transoral endoscopic thyroidectomy by ves-tibular approach-initial experience and comparative analysis in the first reported Mexican cohort. *J Laparoendosc Adv Surg Tech A.* 2019; 29 (12): 1526-1531.

- [7] Wang Y, Zhou S, Liu X, et al. Transoral endoscopic thyroidectomy vestibular approach vs conventional open thyroidectomy: Meta-analysis. *Head Neck* [Internet]. 2021 Jan [cited 2021 May]; 43 (1): 345-353. Available from: <https://onlinelibrary.wiley.com/doi/epdf/10.1002/hed.26486> DOI: 10.1002/hed.26486.
- [8] Wang C, Feng Z, Li J, et al. Endoscopic thyroidectomy via areola approach: summary of 1,250 cases in a single institution. *Surg Endosc*. 2015; 29 (1): 192-201.
- [9] Dionigi G, Chai YJ, Tufano RP, Anuwong A, Kim HY. Transoral endoscopic thyroidectomy via a vestibular approach: why and how? *Endocrine*. 2018; 59 (2): 275-279.
- [10] Sun H, Zheng H, Wang X, Zeng Q, Wang P, Wang Y. Comparison of transoral endoscopic thyroidectomy vestibular approach, total endoscopic thyroidectomy via areola approach, and conventional open thyroidectomy: a retrospective analysis of safety, trauma, and feasibility of central neck dissection in the treatment of papillary thyroid carcinoma. *Surg Endosc*. 2020; 34 (1): 268-274.
- [11] Kasemsiri P, Trakulkajornsak S, Bamroong P, Mahawerawat K, Piromchai P, Ratanaaneekchai T. Comparison of quality of life between patients undergoing trans-oral endoscopic thyroid surgery and conventional open surgery. *BMC Surg*. 2020; 20 (1): 18.
- [12] Wang C, Zhai H, Liu W, et al. Thyroidectomy: a novel endoscopic oral vestibular approach. *Surgery*. 2014; 155 (1): 33-38.
- [13] Shan L, Liu JA. Systemic review of transoral thyroidectomy. *Surg Laparosc Endosc Percutan Tech*. 2018; 28 (3): 135-138.
- [14] Camenzuli C, Schembri Wismayer P, Calleja Agius J. Transoral endoscopic thyroidectomy: a systematic review of the practice so far. *JSLS*. 2018; 22 (3): e2018.00026.
- [15] Anuwong A, Sasanakietkul T, Jitpratoom P, et al. Transoral endoscopic thyroidectomy vestibular approach (TOETVA): indications, techniques and results. *Surg Endosc*. 2018; 32 (1): 456-465.
- [16] Tesseroli MAS, Spagnol M, Sanabria A. Transoral endoscopic thyroidectomy by vestibular approach (TOETVA): initial experience in Brazil. *Rev Col Bras Cir*. 2018; 45 (5): e1951.
- [17] Anuwong A. Transoral Endoscopic Thyroidectomy Vestibular Approach: A Series of the First 60 Human Cases. *World J Surg*. 2016 Mar; 40 (3): 491-7.
- [18] Deroide G, Honigman I, Berthe A, et al. Transoral endoscopic thyroidectomy (TOETVA): First French experience in 90 patients. *J Visc Surg* [Internet]. 2021 Apr [cited 2021 May]; 158 (2): 103-110. Available from: <https://www.sciencedirect.com/science/article/pii/S1878788621000230?via%3Dihub> DOI: 10.1016/j.jviscsurg.2021.02.001.
- [19] Anuwong A, Kim HY, Dionigi G. Transoral endoscopic thyroidectomy using vestibular approach: updates and evidences. *Gland Surg* [Internet]. 2017 Jun [cited 2021 May]; 6 (3): 277-284. Available from: <https://gs.amegroups.com/article/view/14691/14873> DOI: 10.21037/g.2017.03.16.